

19-00

Visual Organs

19 Visual Organs

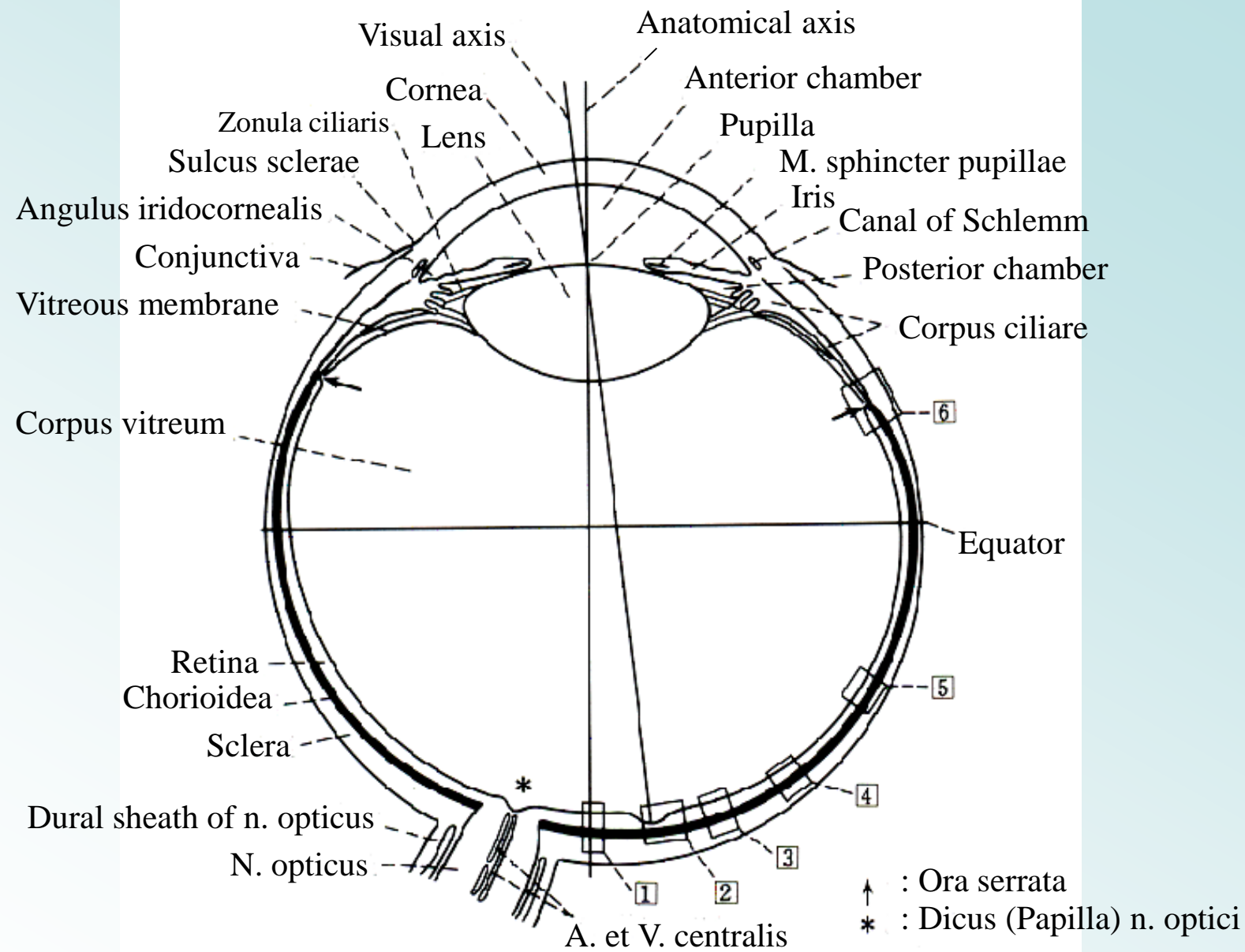
Menu

- [19-00.](#) Visual Organs
- [19-001.](#) Eyeballs
- [19-01.](#) Scheme showing the horizontal section of right eyeball.
- [19-02.](#) Table showing the structure of the eyeball.
- [19-03.](#) Eyeball, horizontal section 1. General view. Monkey, H-E stain, x1.2.
- [19-04.](#) Eyeball, horizontal section 2. General view. Monkey, H-E stain, x1.6.
- [19-05.](#) Anterior portion of the eyeball. Monkey, H-E stain, x 2.0.
- [19-06.](#) Posterior portion of eyeball. Monkey, H-E stain, x 4.0.
- [19-07.](#) Posterior wall of eyeball. Monkey, H-E stain, x 30.
- [19-08.](#) Retina, 1. Monkey, H-E stain, x 100.
- [19-09.](#) Scheme showing the structure of retina, based on the Golgi method and electron microscopy.
- [19-10.](#) Table showing the path-way of light and neuronal conduction.
- [19-11.](#) Scheme showing the distribution of cones and rods.
- [19-12.](#) Fovea centralis, 1. Monkey, H-E stain, x 25.
- [19-13.](#) Fovea centralis, 2. Monkey, H-E stain, x 50.
- [19-14.](#) Fovea centralis, 3. Monkey, H-E stain, x 25.
- [19-15.](#) Fovea centralis, 4. Monkey, H-E stain, x 64.
- [19-16.](#) Retina, 2. Monkey, H-E stain, x 100.
- [19-17.](#) Retina, 3. Monkey, H-E stain, x 100.
- [19-18.](#) Retina, 4. Monkey, H-E stain, x 160.

- [19-19.](#) Retina, 5. Ora serrata. Monkey, H-E stain, x 30.
- [19-20.](#) Chorioidea. Monkey, H-E stain, x 160.
- [19-21.](#) Papilla nervi optici. Monkey, H-E stain, x 10.
- [19-22.](#) Cornea 1. Monkey, H-E stain, x 64.
- [19-23.](#) Cornea 2. Anterior portion. Monkey, H-E stain, x 130.
- [19-24.](#) Cornea 3. Posterior portion. Monkey, H-E stain, x 160.
- [19-25.](#) Iridocorneal angle, 1. Monkey, H-E stain, x 6.
- [19-26.](#) Iridocorneal angle, 2. Canal of Schlemm. Monkey, H-E stain, x 40.
- [19-27.](#) Iridocorneal angle, 3. Monkey, H-E stain, x 30.
- [19-28.](#) Corpus ciliare, iris, and lens. Monkey, H-E stain, x 25.
- [19-29.](#) Pars ciliaris retinae. Monkey, H-E stain, x 64.
- [19-30.](#) Equatorial portion of lens. Monkey, H-E stain, x 50.
- [19-31.](#) Lens and zonule fibers. Monkey, H-E stain, x 100.
- [19-32.](#) Lens and pupillar edge of iris. Monkey, H-E stain, x 30.
- [19-33.](#) Iris, the whole thickness. Monkey, H-E stain, x 50.
- [19-34.](#) Posterior portion of iris. Monkey, H-E stain, x 160.
- [19-35.](#) Eyelid, sagittal section. Human, H-E stain, x 4.0.
- [19-36.](#) Tarsal glands. Human, H-E stain, x 10.
- [19-37.](#) A lobe of tarsal gland. Human, H-E stain, x 100.
- [19-38.](#) Lacrimal gland, 1. Human, H-E stain, x 64.
- [19-39.](#) Lacrimal gland, 2. Human, H-E stain, x 100.

19-001

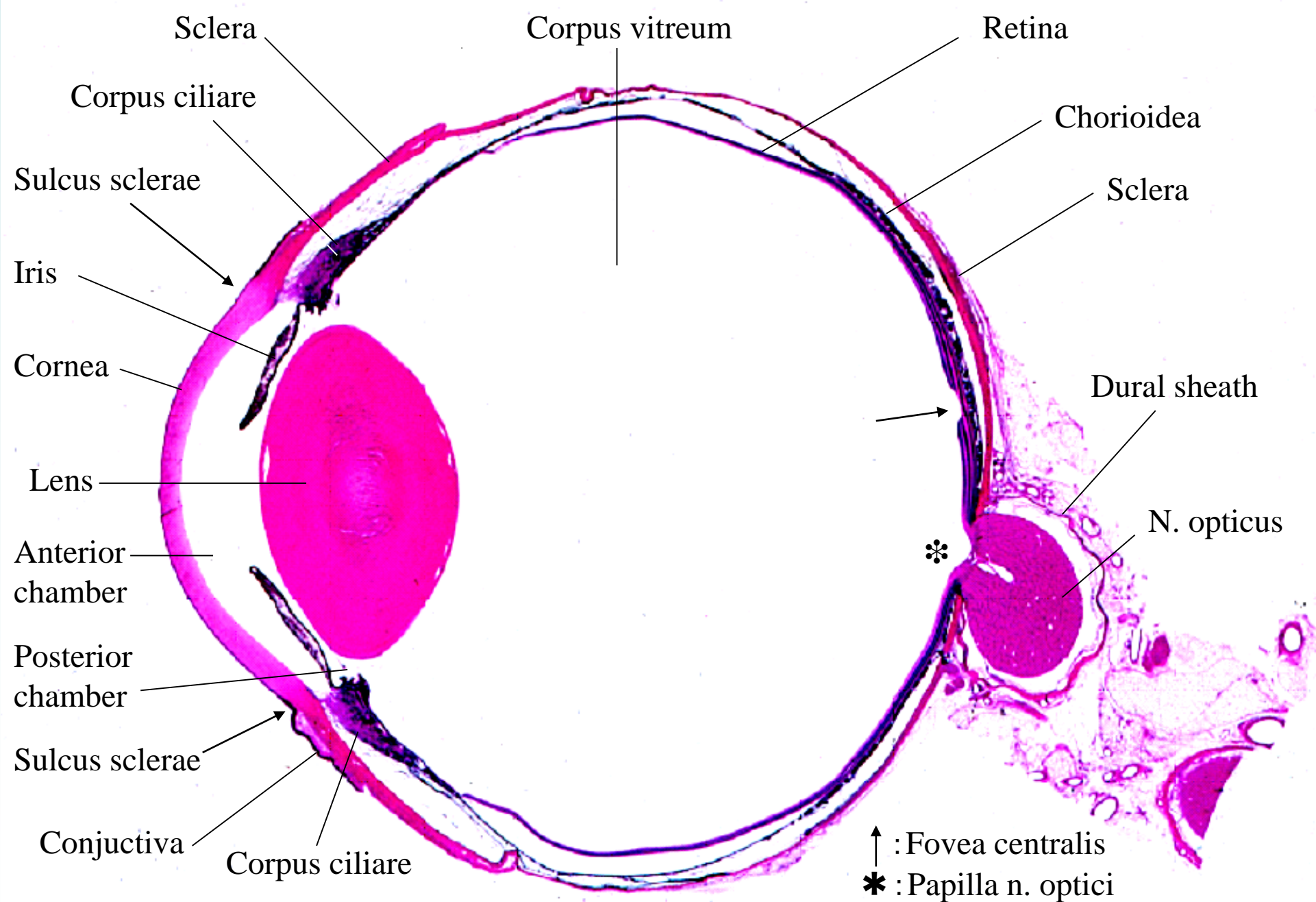
Eyeballs



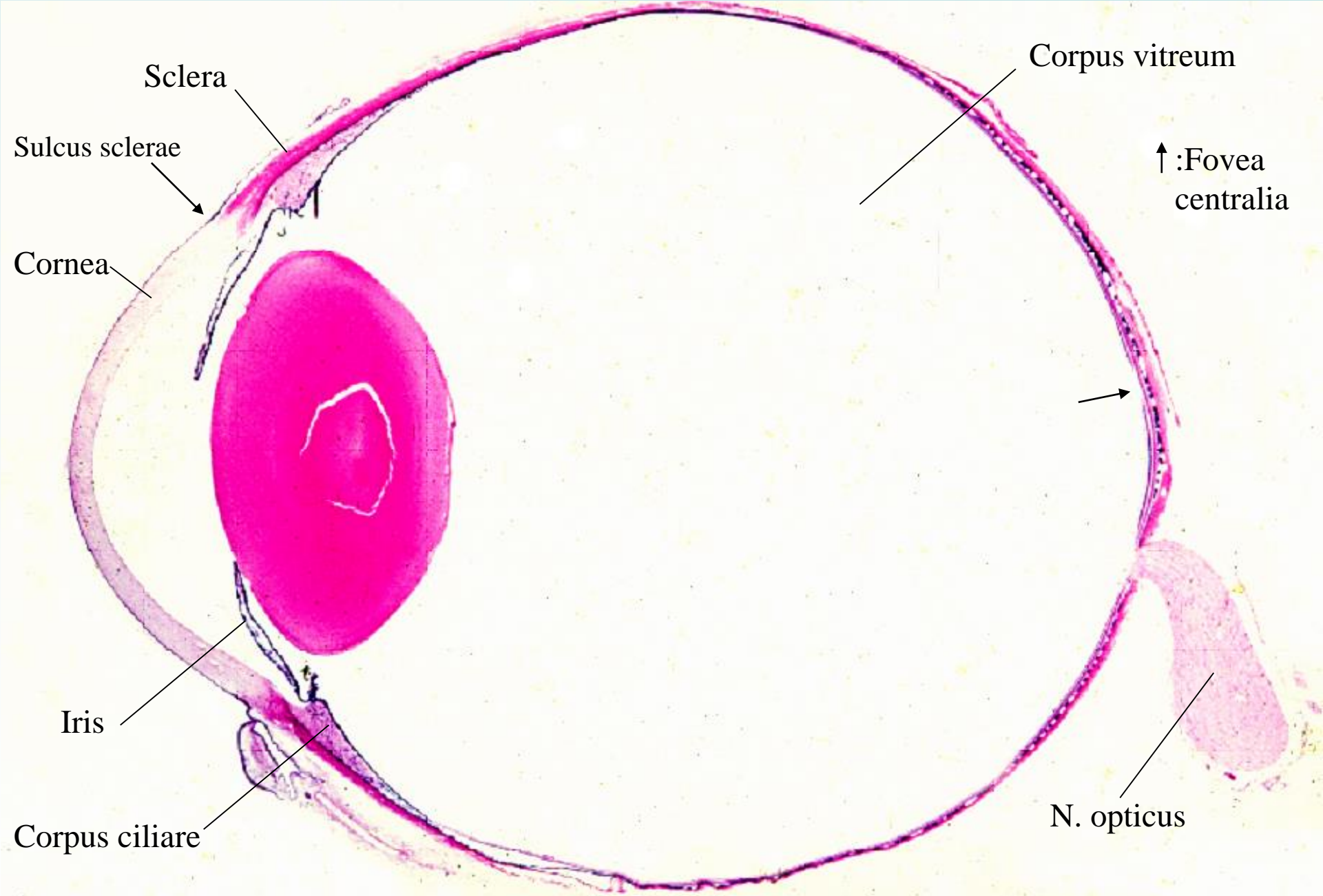
19-01 Scheme showing the horizontal section of right eyeball.

		Anterior portion	Posterior portion
Wall of eye-ball	Tunica fibrosa	Cornea	Sclera
	Tunica vasculosa	Iris & Corpus ciliare	Chorioidea
	Tunica interna	Pars caeca retinae ①Pars iridica retinae ②Pars ciliaris retinae	Retina
Contents		Lens & Humor aquaeus	Corpus vitreum

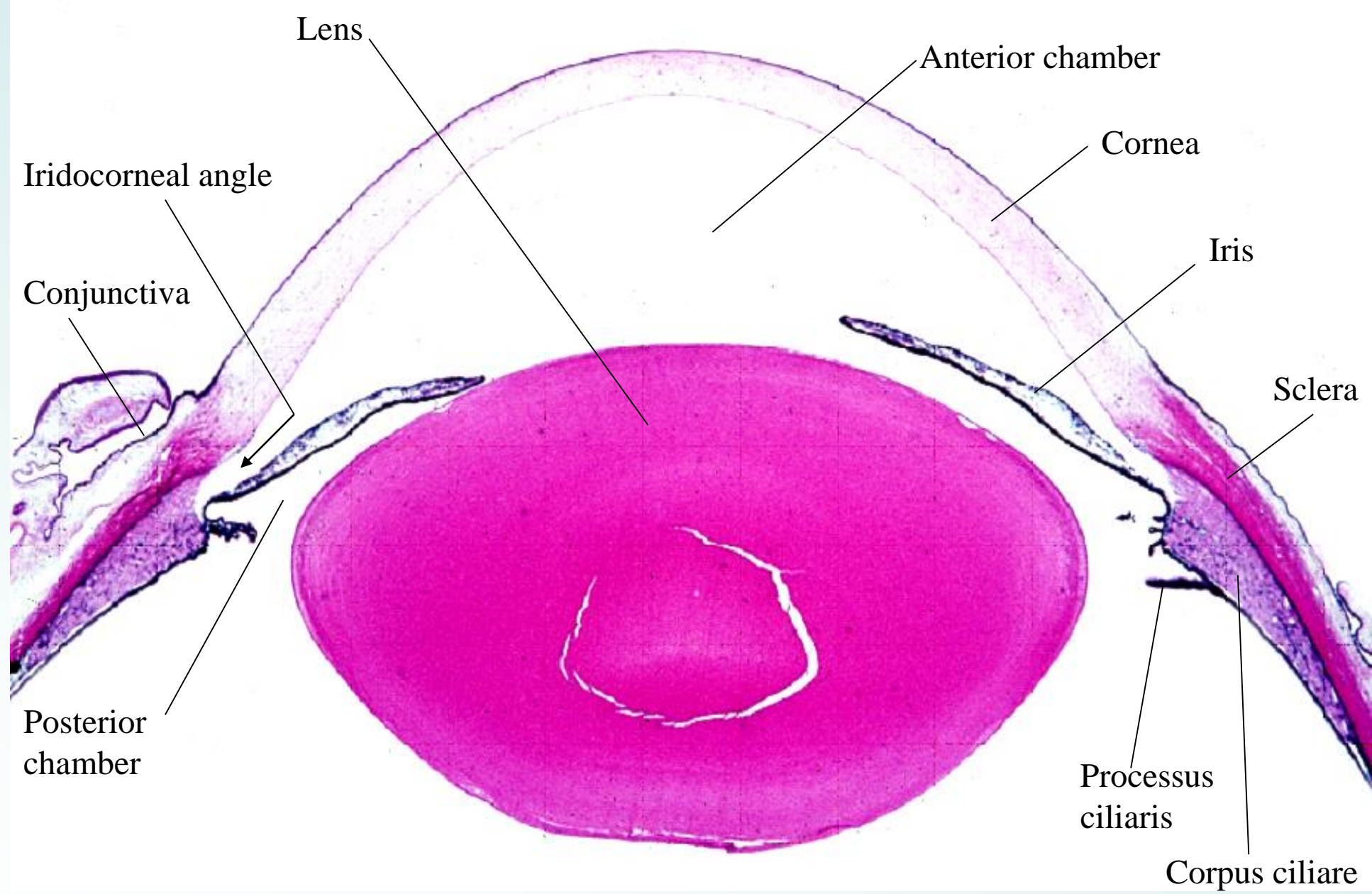
① and ② are both the component of Iris and Corpus ciliare, respectively.



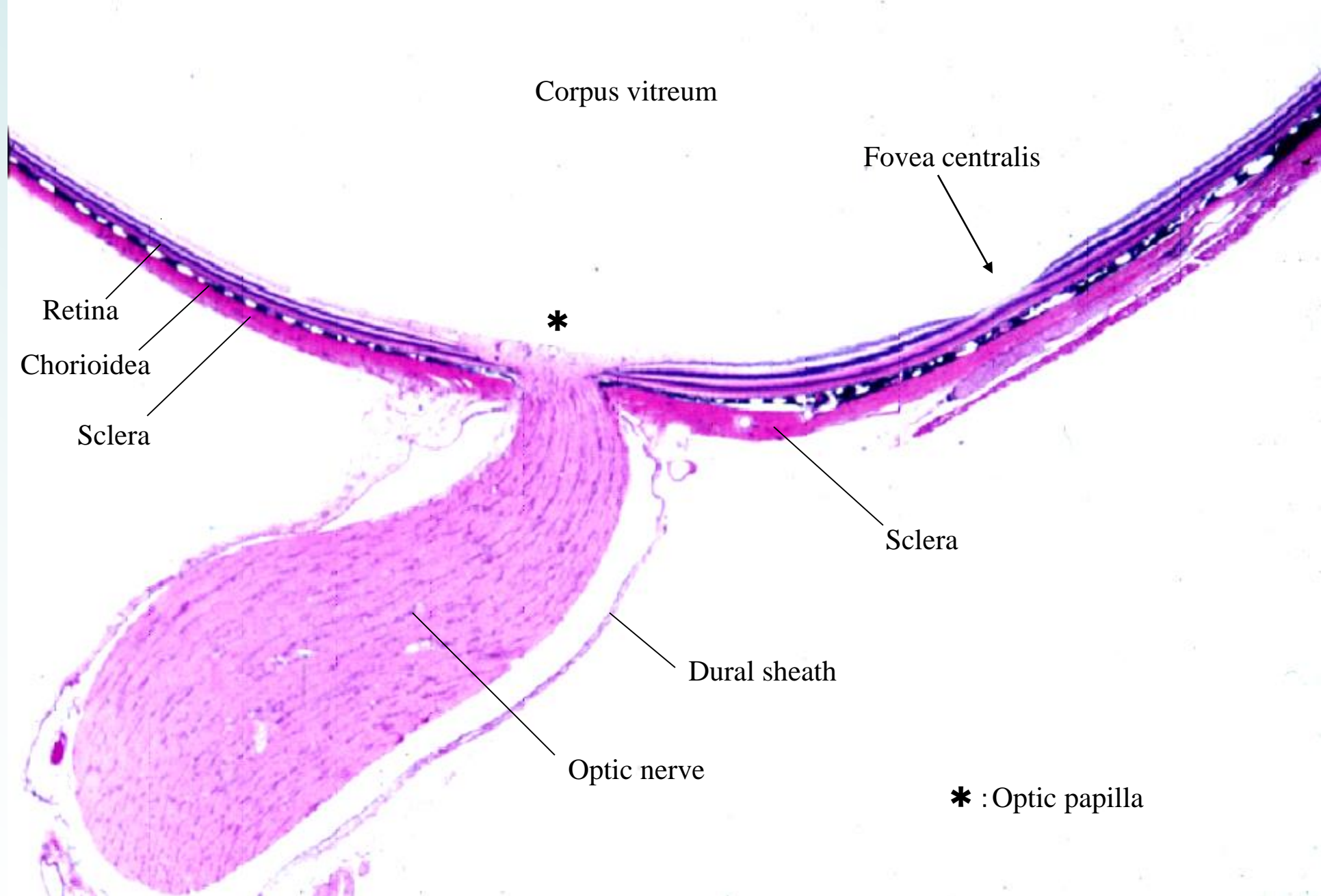
19-03 Eyeball, horizontal section 1. General view. Monkey, H-E stain, x1.2.



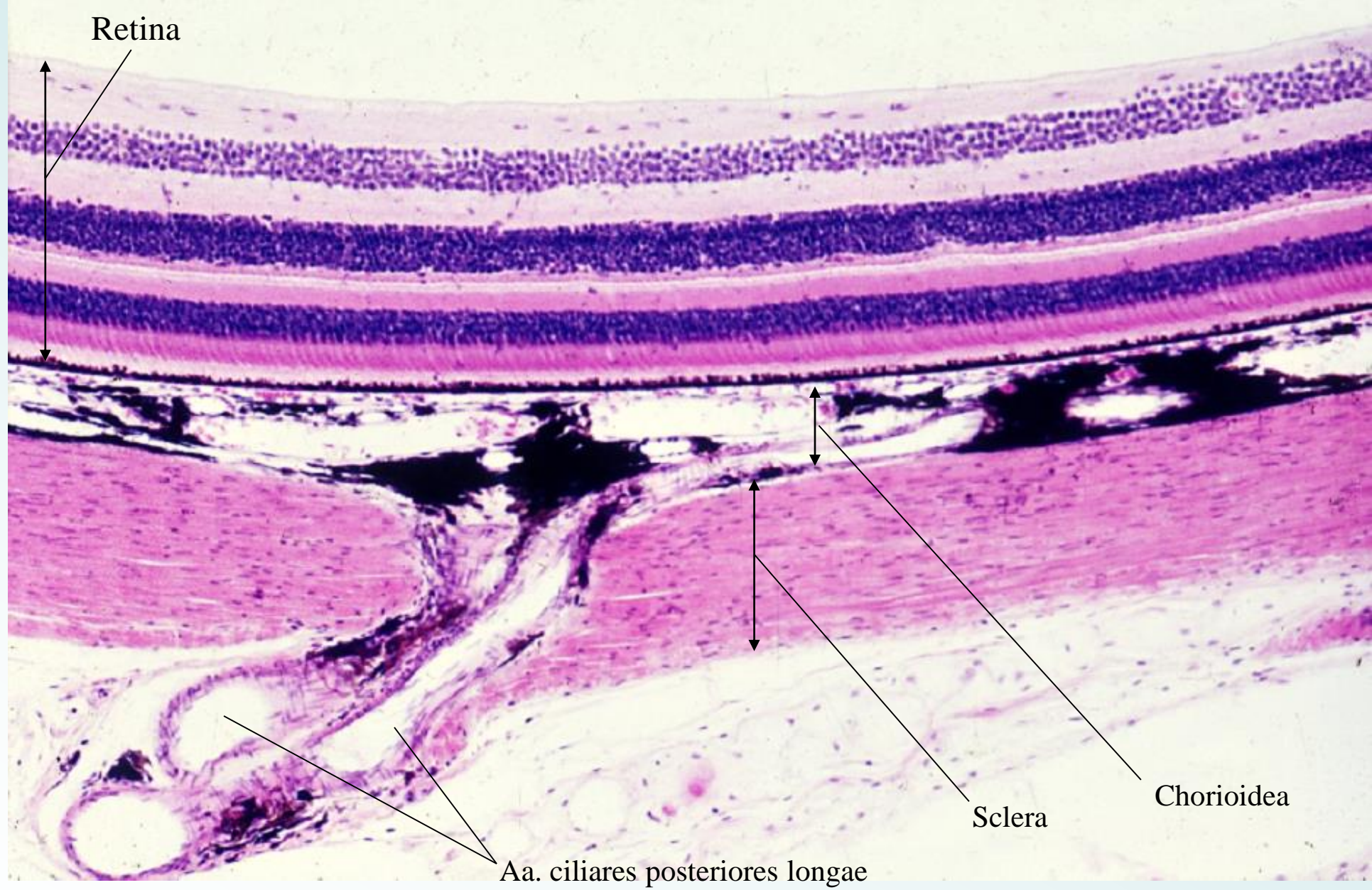
19-04 Eyeball, horizontal section 2. General view. Monkey, H-E stain, x1.6.



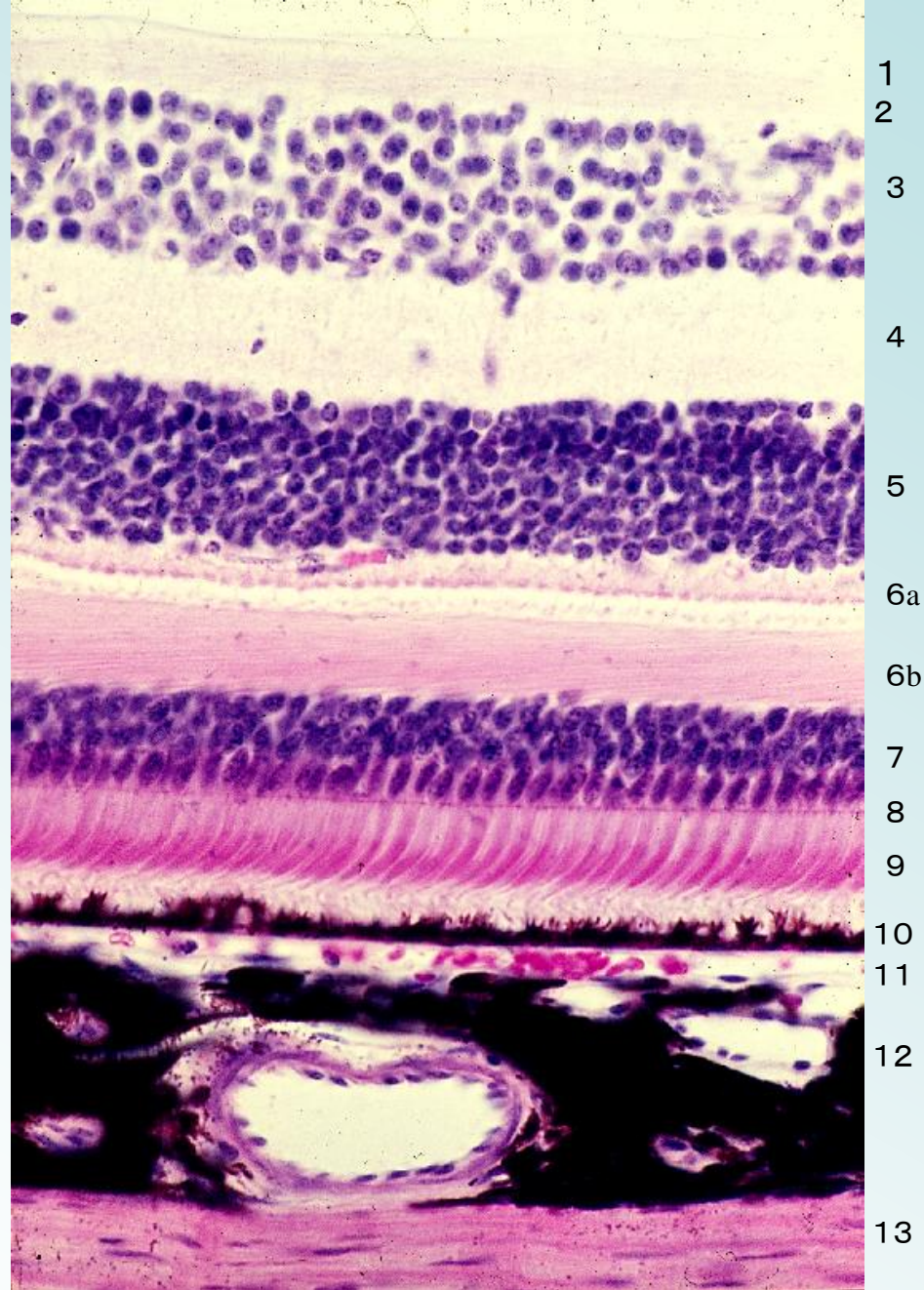
19-05 Anterior portion of the eyeball. Monkey, H-E stain, x 2.0.



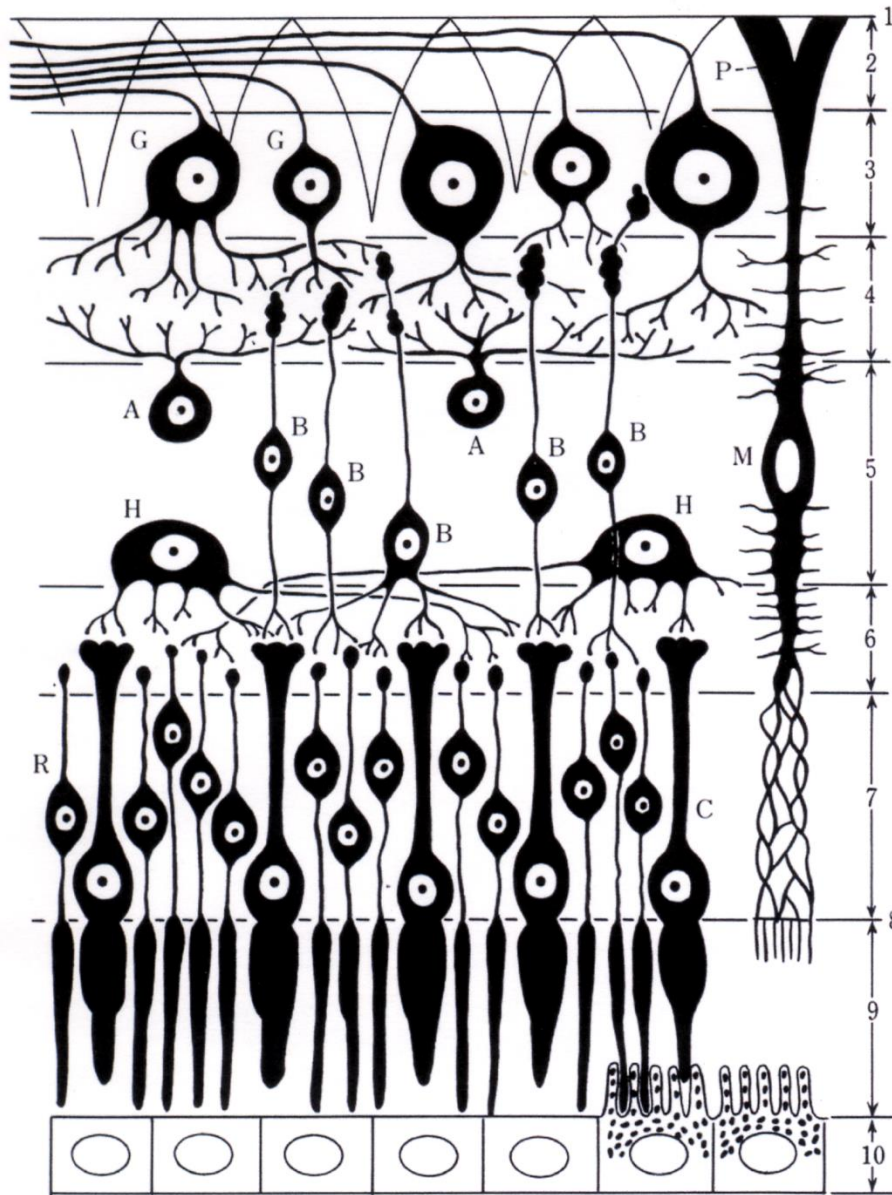
19-06 Posterior portion of eyeball. Monkey, H-E stain, x 4.0.



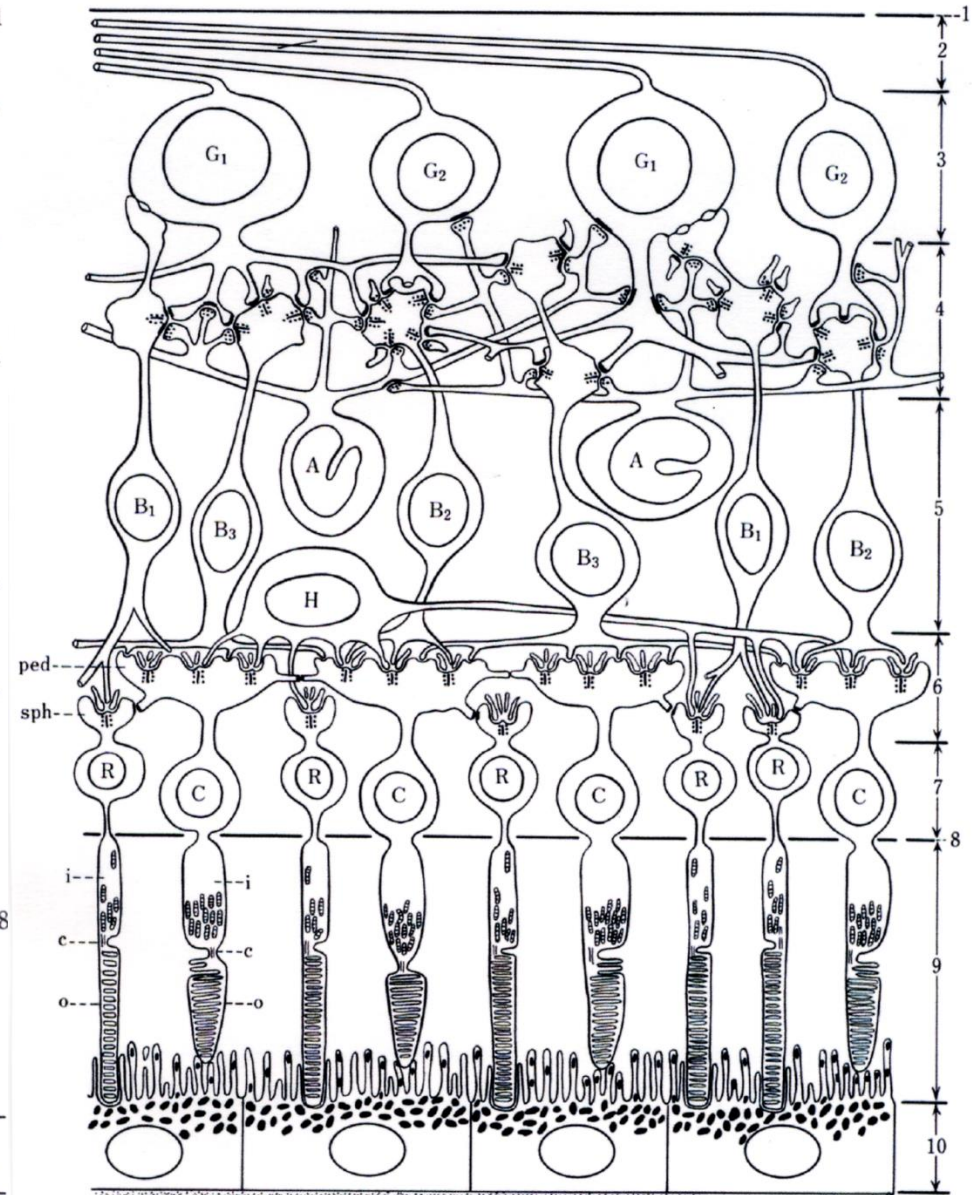
19-07 Posterior wall of eyeball. Monkey, H-E stain, x 30.



19-08 Retina, 1. Monkey, H-E stain, x 100.



Golgi method

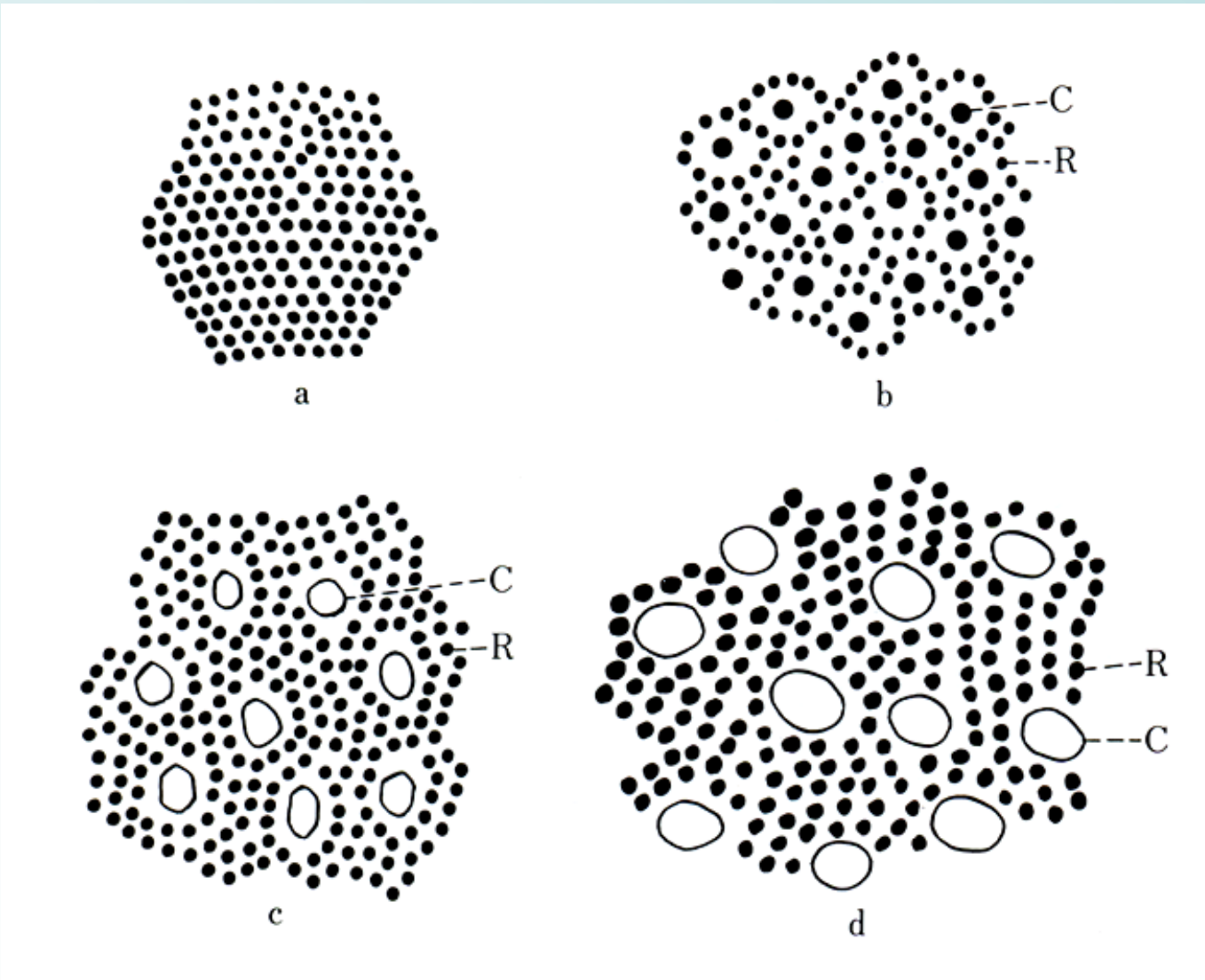


Electron microscopy

19-09 Scheme showing the structure of retina, based on the Golgi method and electron microscopy.

Path-way of light	Layers of retina	Cells constituting retina	Neuronal conduction
↓	1 . Int. limiting membrane 2 . Layer of optic nerve 3 . Layer of ganglion cells 4 . Inner plexiform layer 5 . Inner granular layer 6 . Outer plexiform layer 7 . Outer granular layer 8 . Ext. limiting membrane 9 . Layer of cones & rods	-----d. Optic nerve cells -----c. Bipolar cells -----b. Cone cells & Rod cells	↑
	10. Layer of pigment epithelium	-----a. Cells of pigment epithelium	

19-10 Table showing the path-way of light and neuronal conduction.



a: Central portion of fovea centralis.


b: Peripheral portion of fovea centralis.

c: Ring area surrounding fovea centralis.

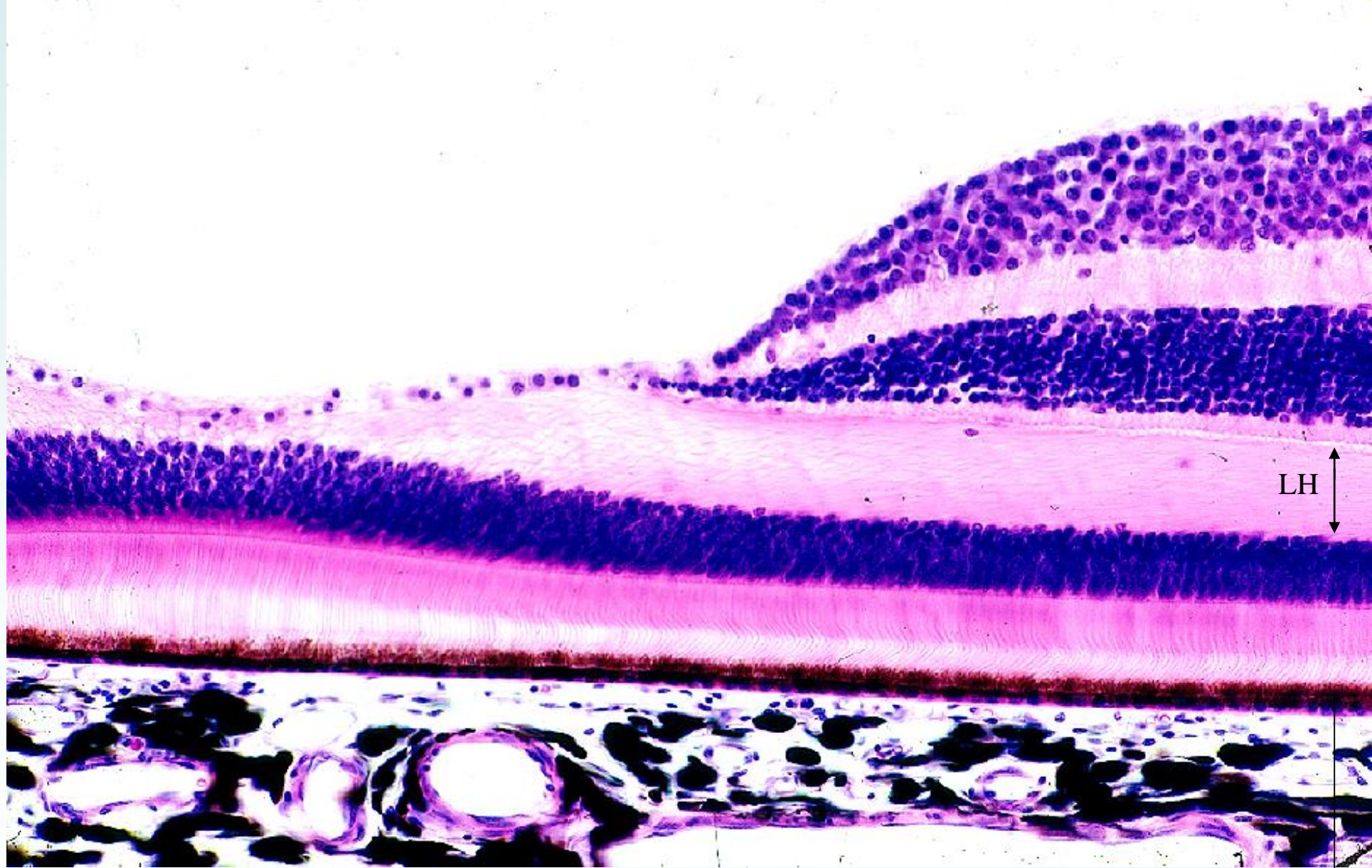
d: The most peripheral area near the ora serrata.

C: Cones.

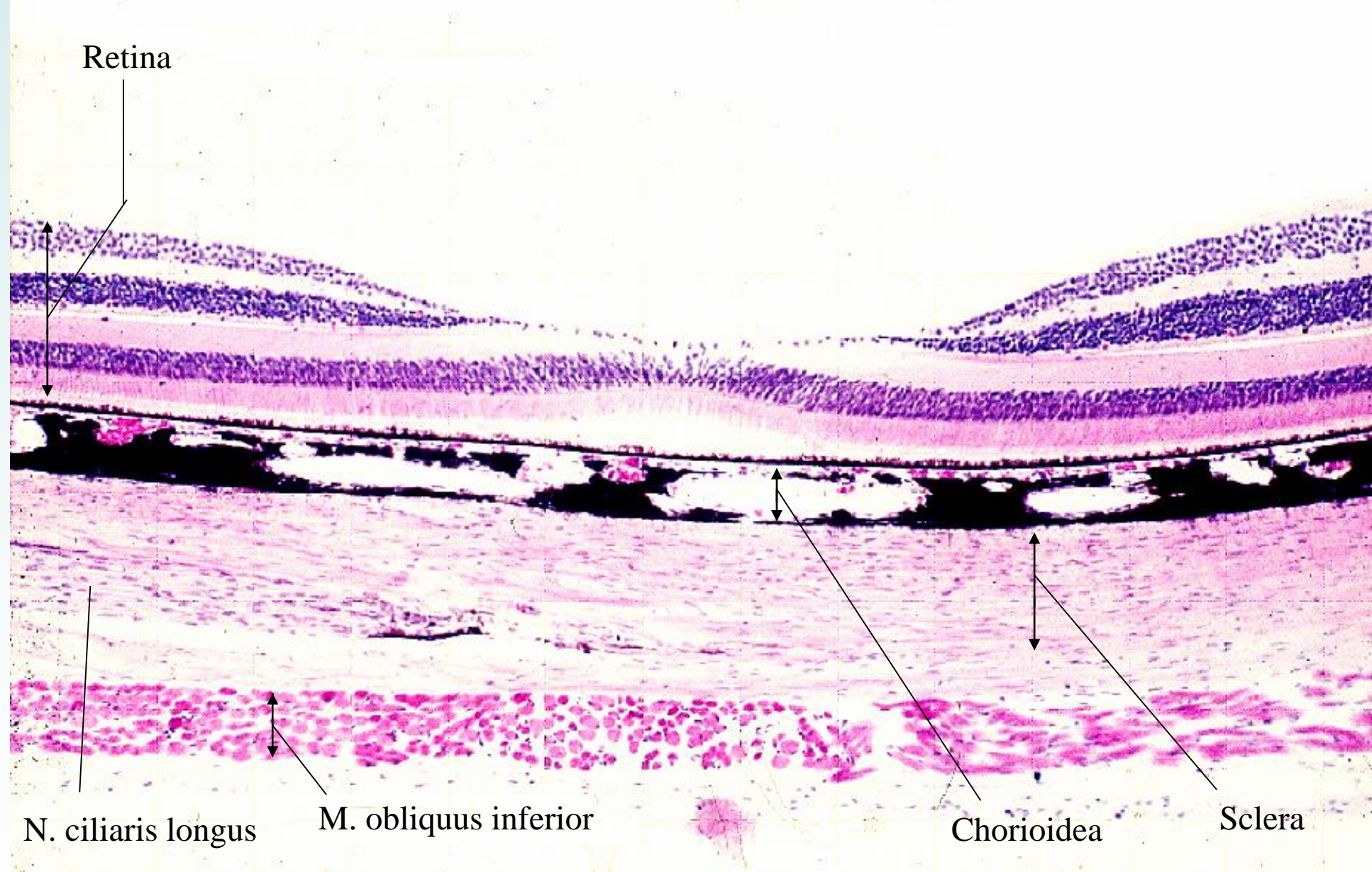
R: Rods.



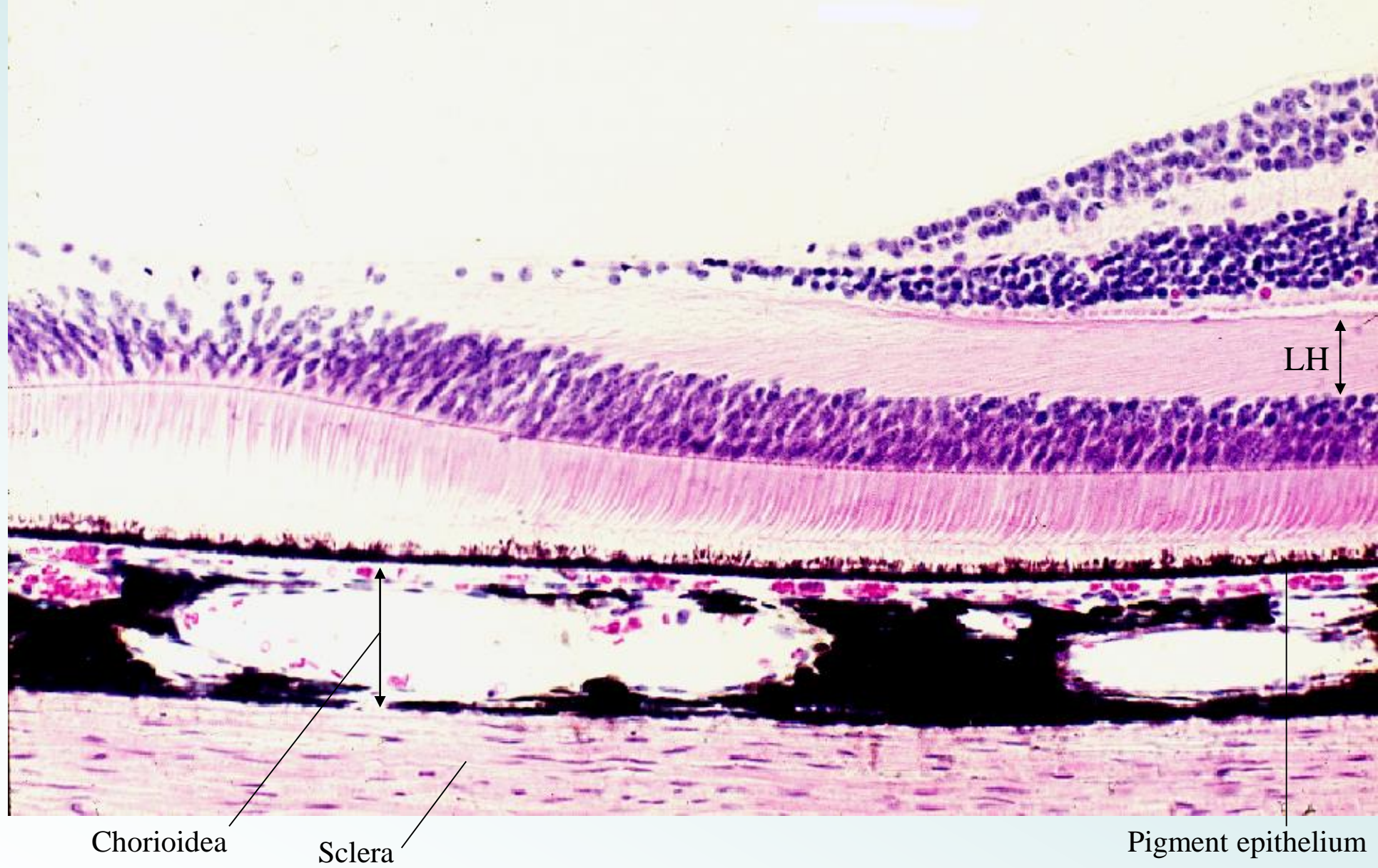
19-12 Fovea centralis, 1. Monkey, H-E stain, x 25.



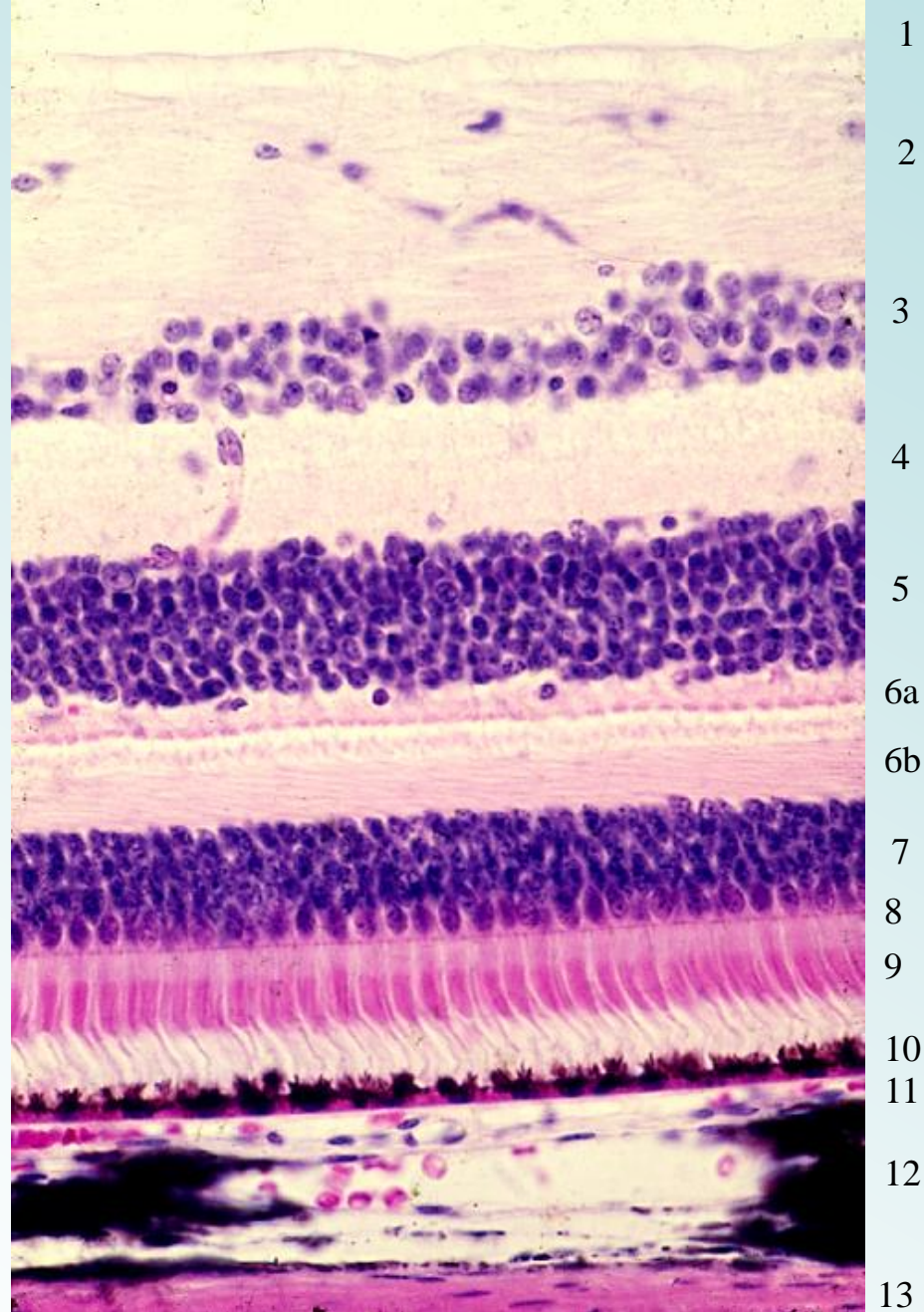
19-13 Fovea centralis, 2. Monkey, H-E stain, x 50.




19-14 Fovea centralis, 3. Monkey, H-E stain, x 25.



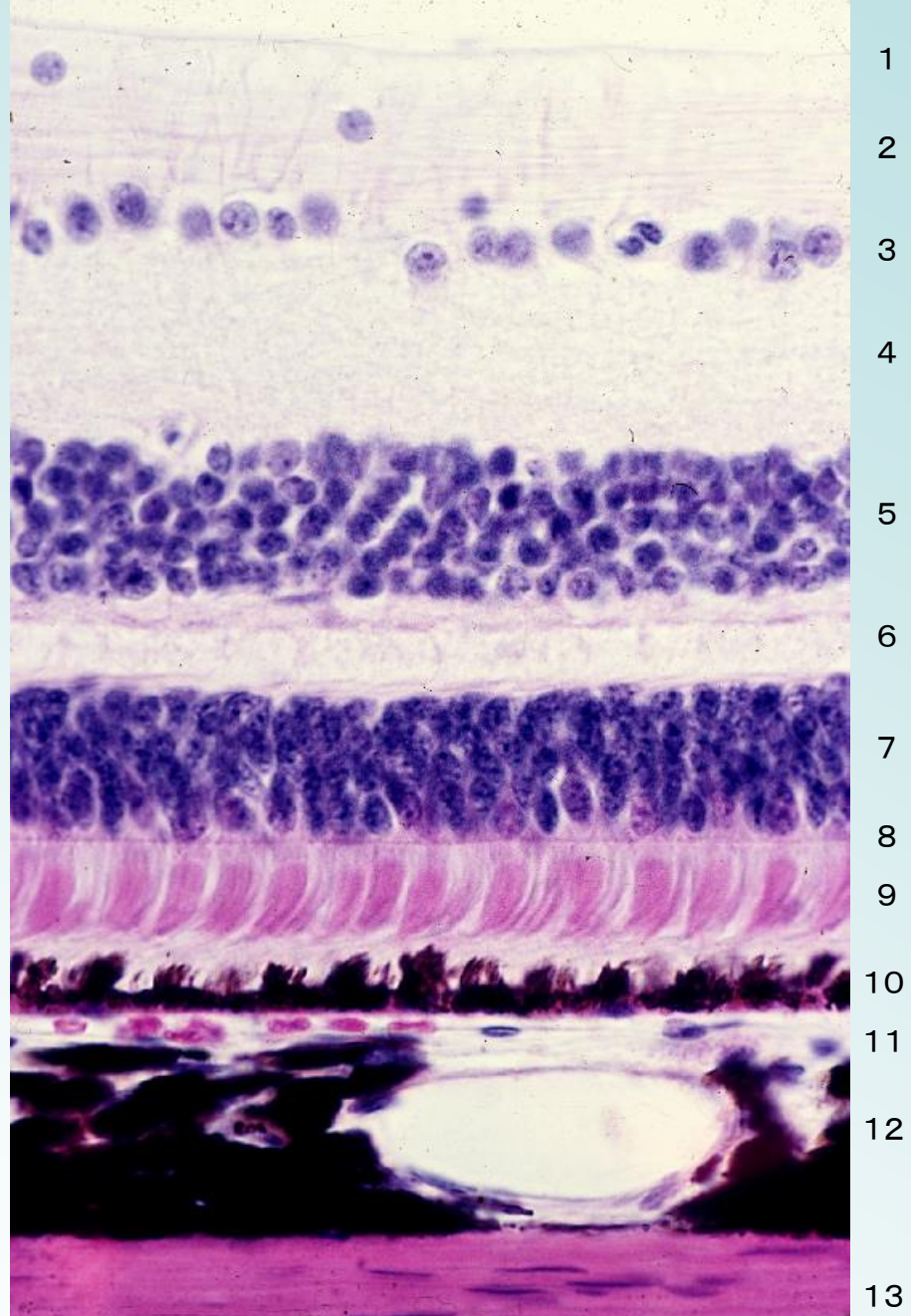
19-15 Fovea centralis, 4. Monkey, H-E stain, x 64.



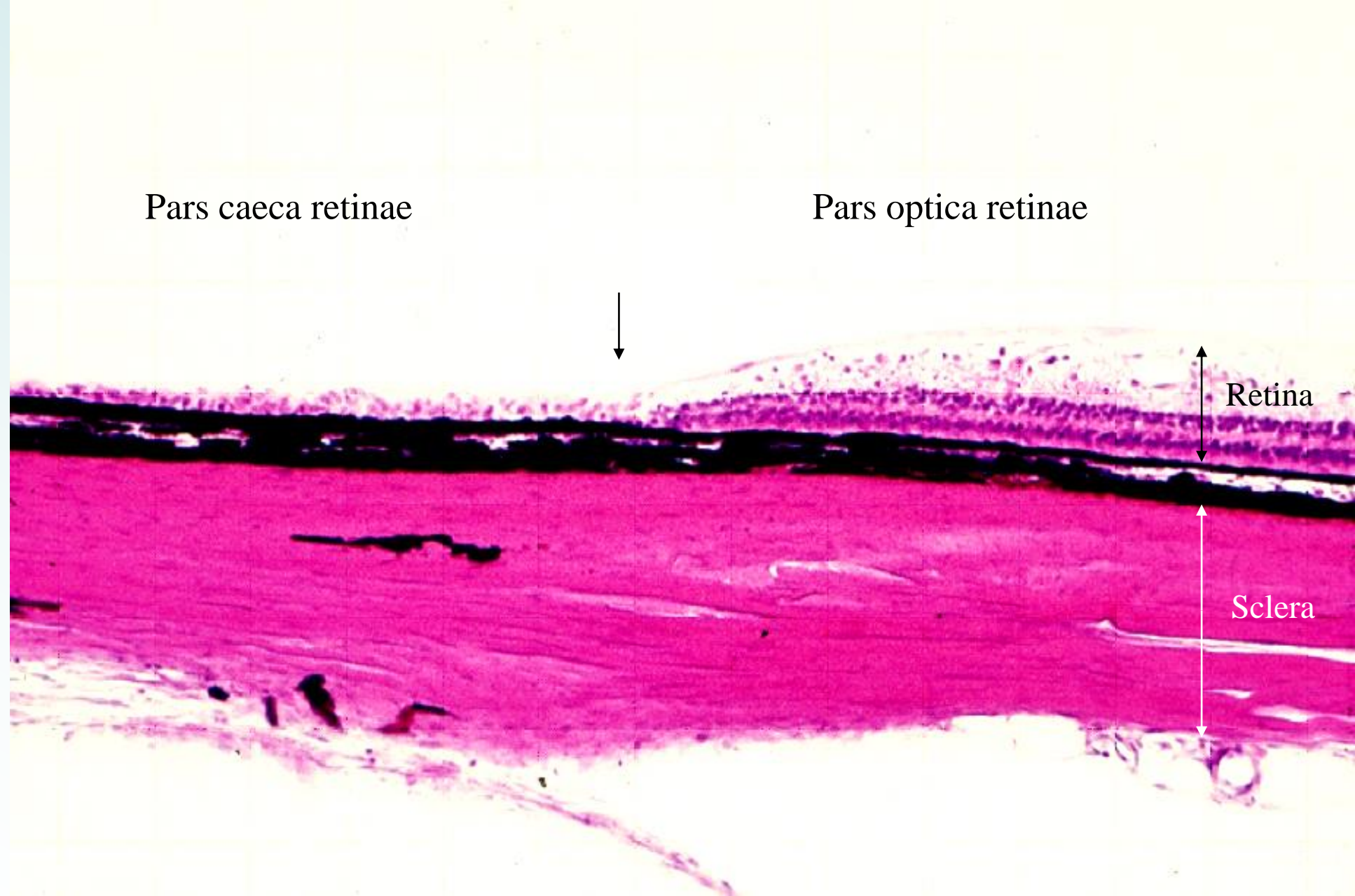
19-16 Retina, 2. Monkey, H-E stain, x 100.



19-17 Retina, 3. Monkey, H-E stain, x 100.



19-18 Retina, 4. Monkey, H-E stain, x 160.



19-19 Retina, 5. Ora serrata. Monkey, H-E stain, x 30.



7

8

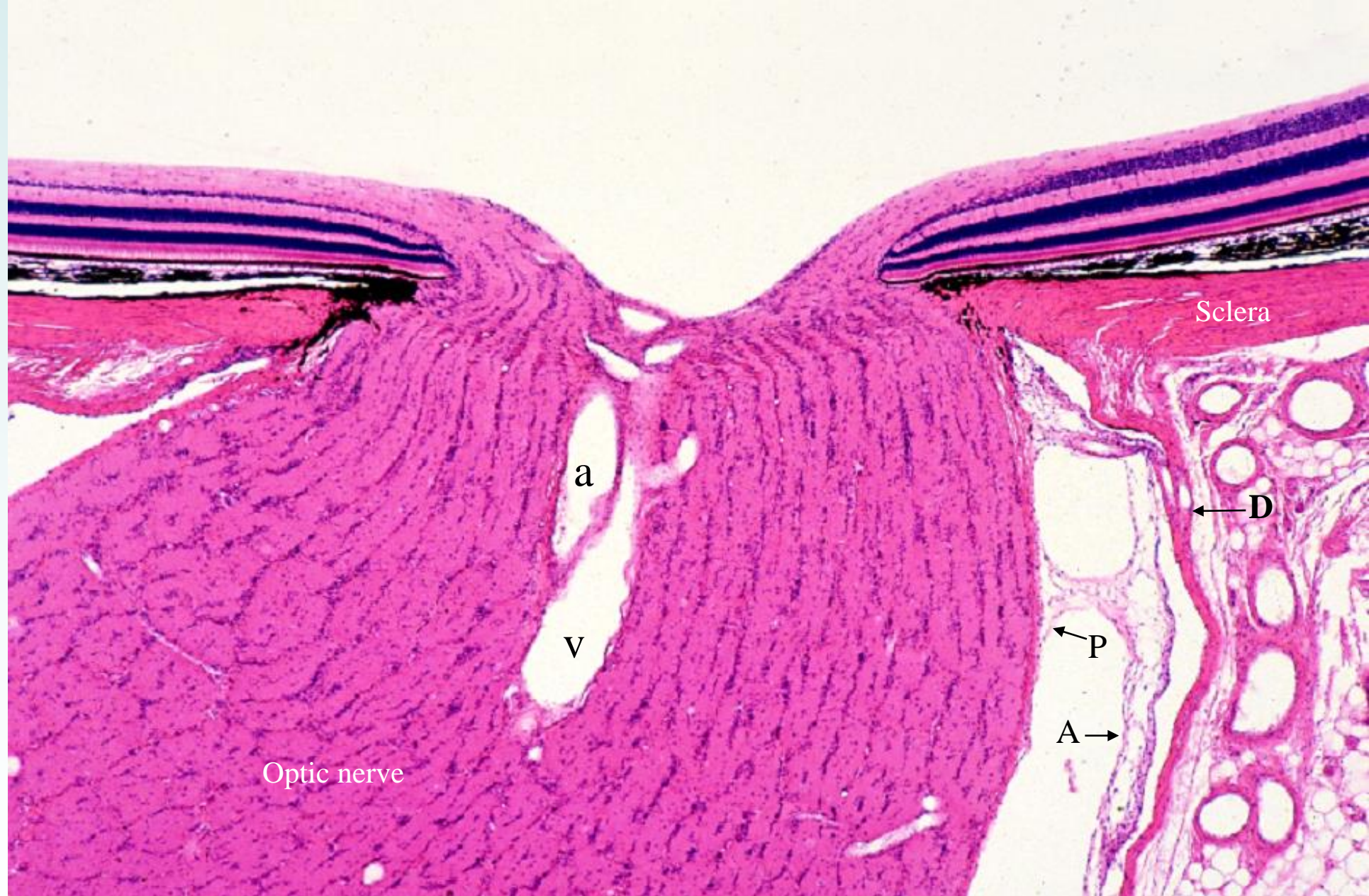9

10

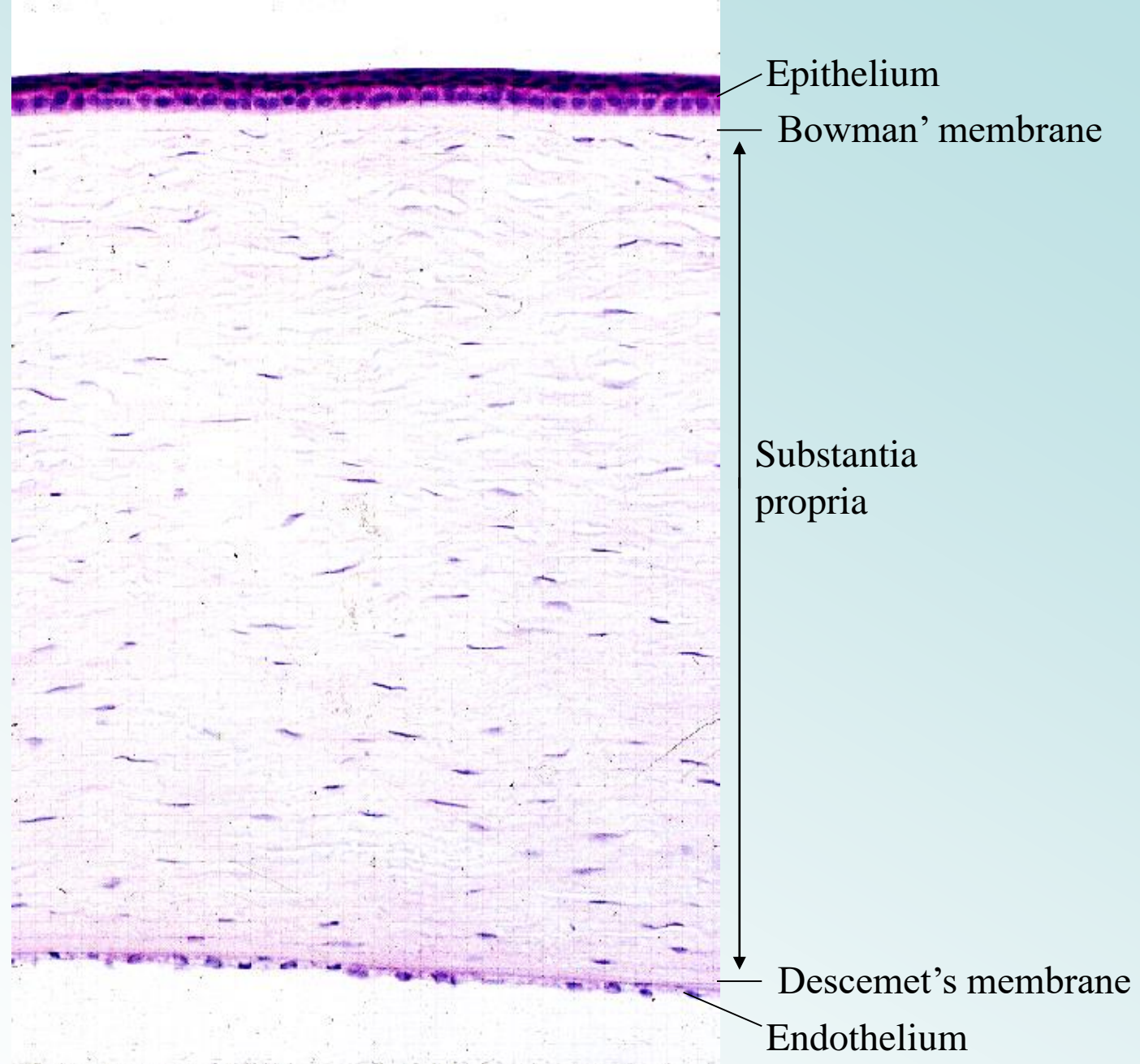
11

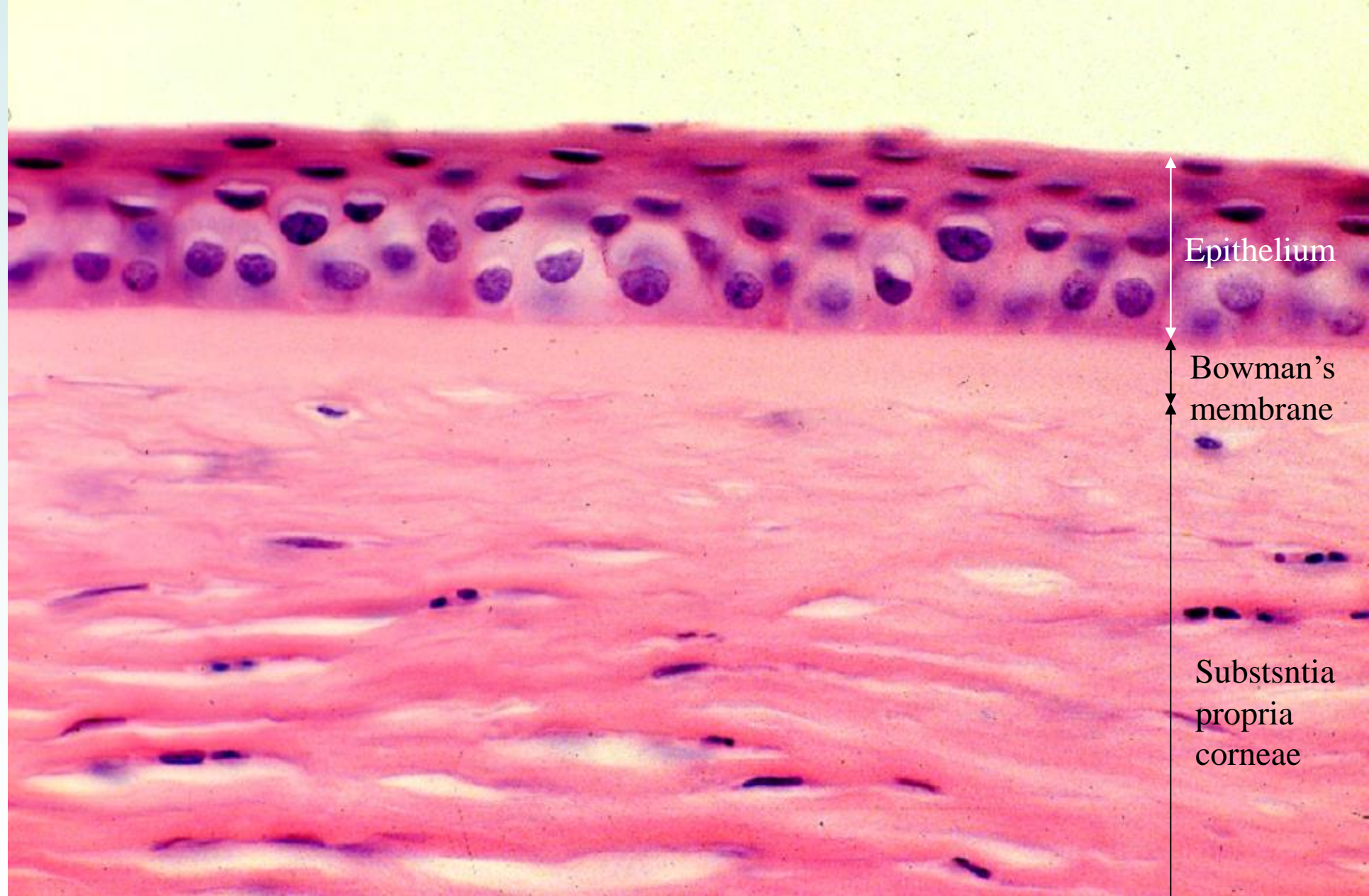
12

13

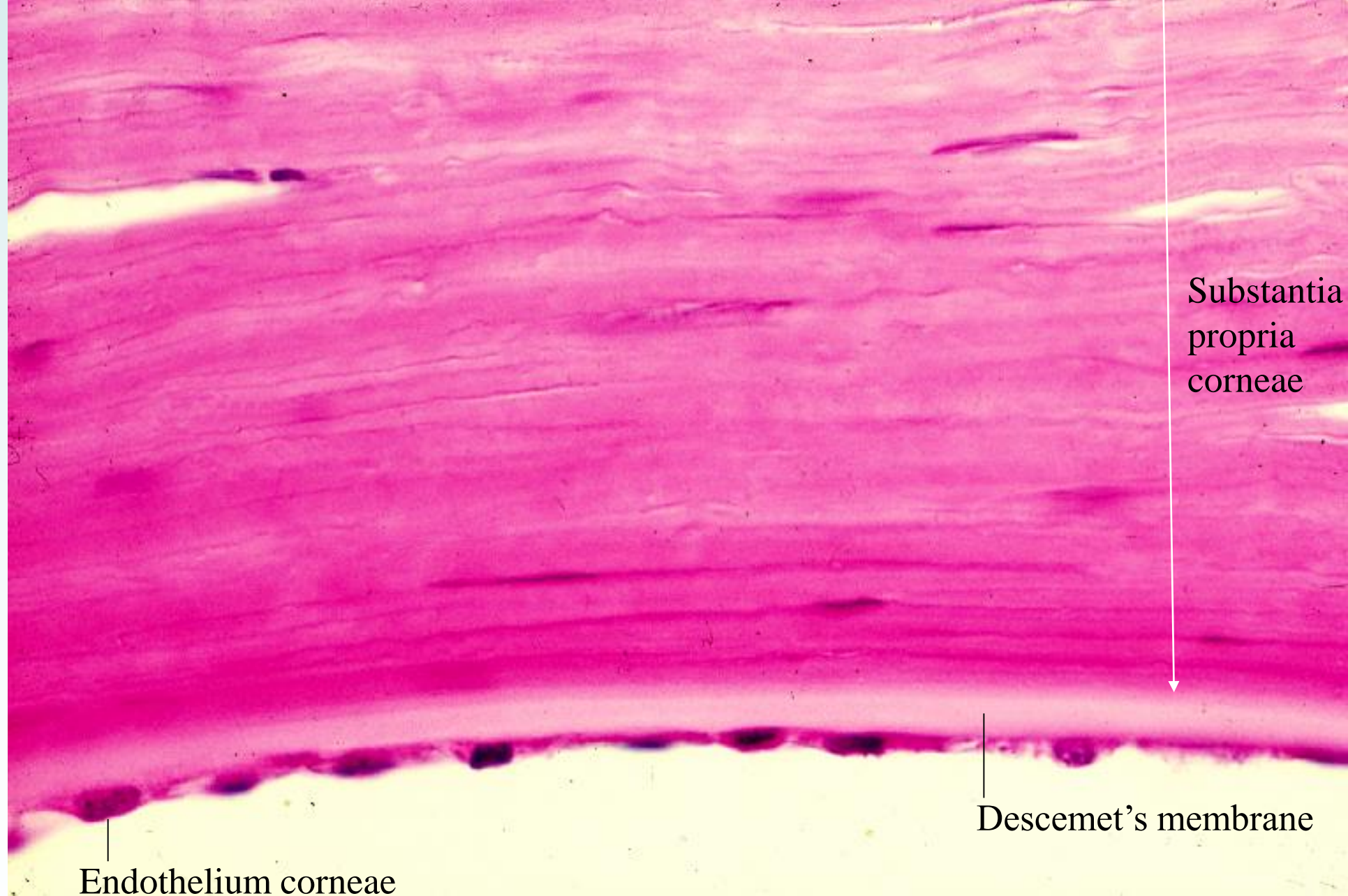


19-21 Papilla nervi optici. Monkey, H-E stain, x 10.

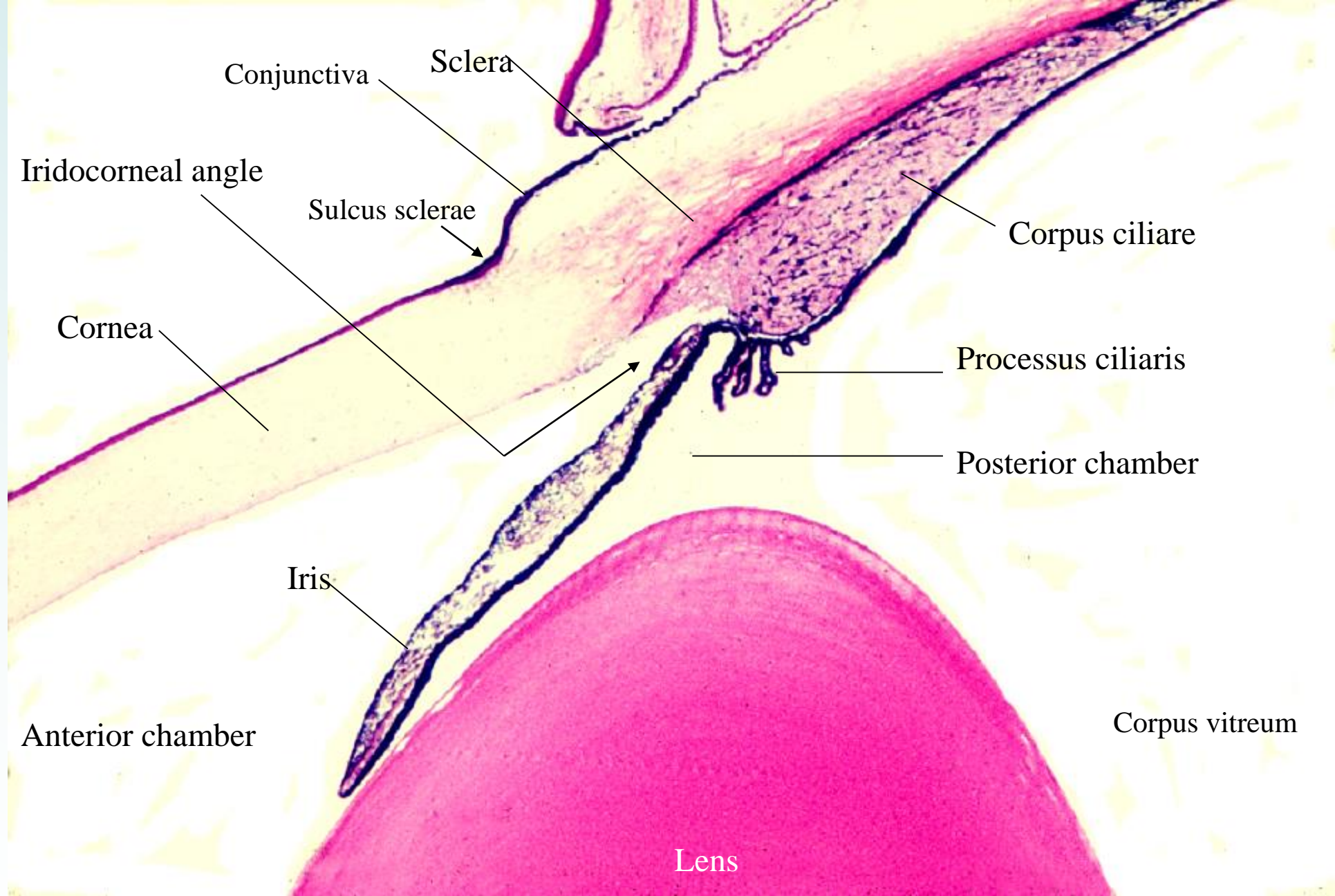




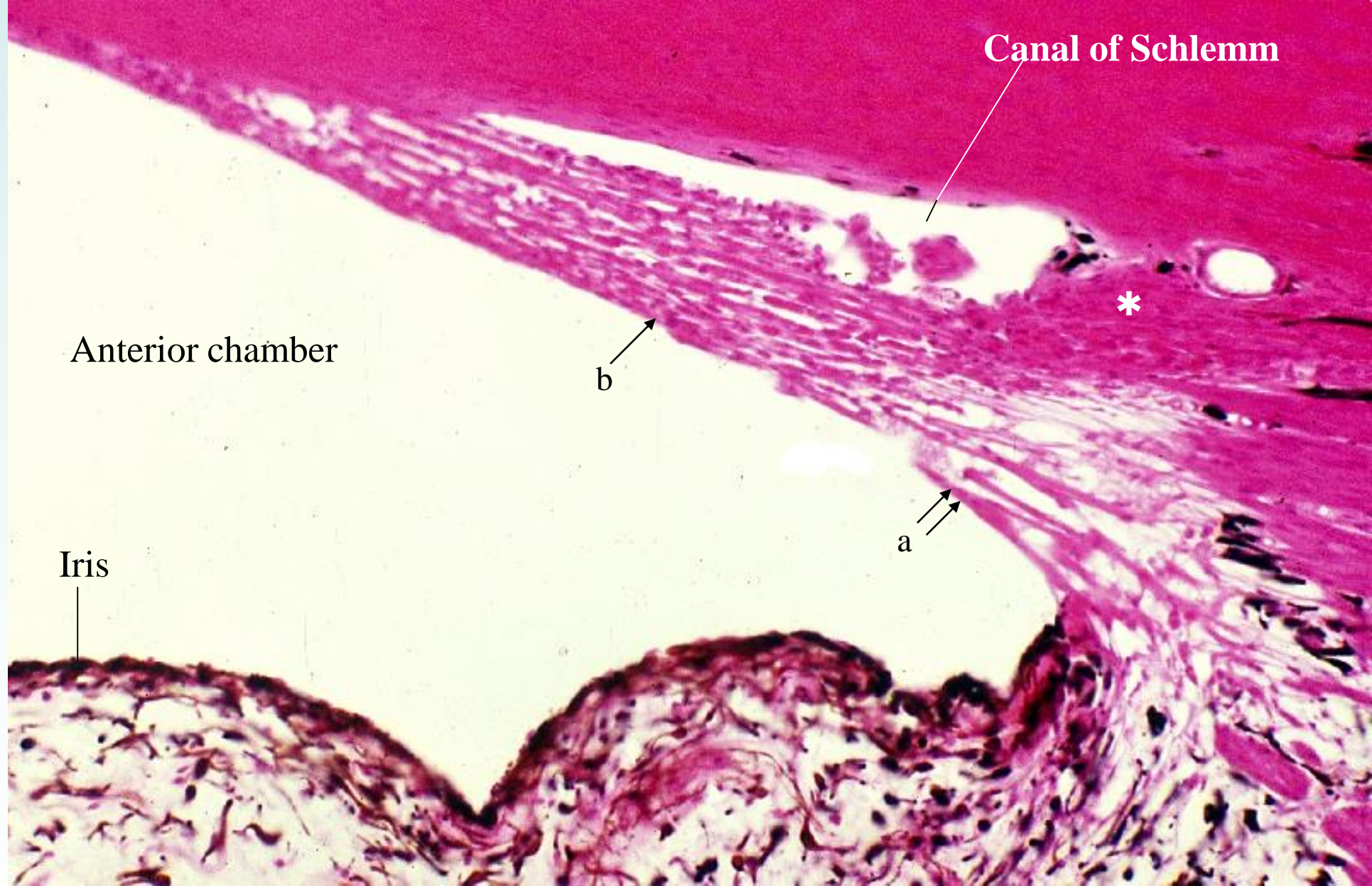
19-23 Cornea 2. Anterior portion. Monkey, H-E stain, x 130.



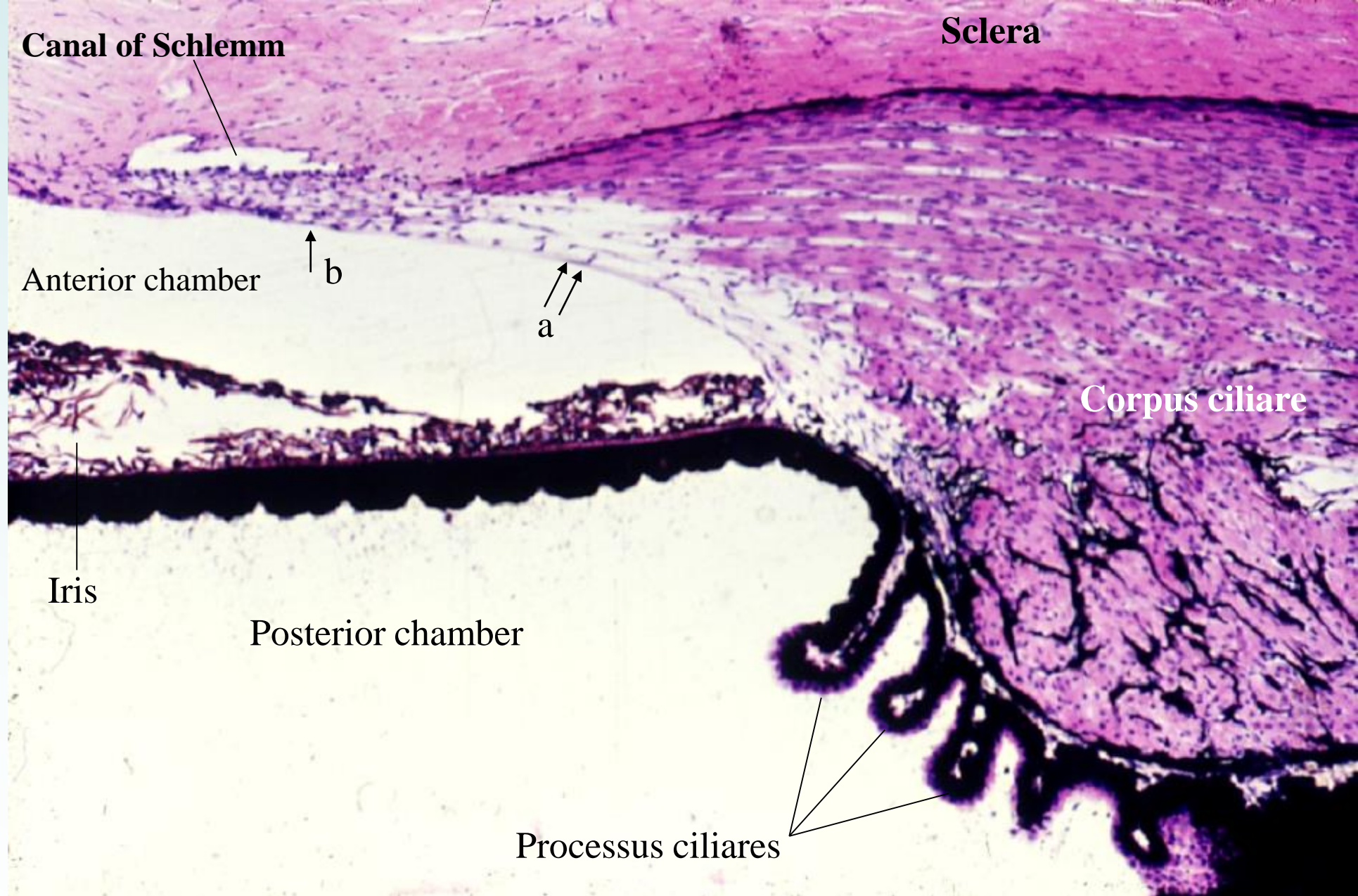
19-24 Cornea 3. Posterior portion. Monkey, H-E stain, x 160.

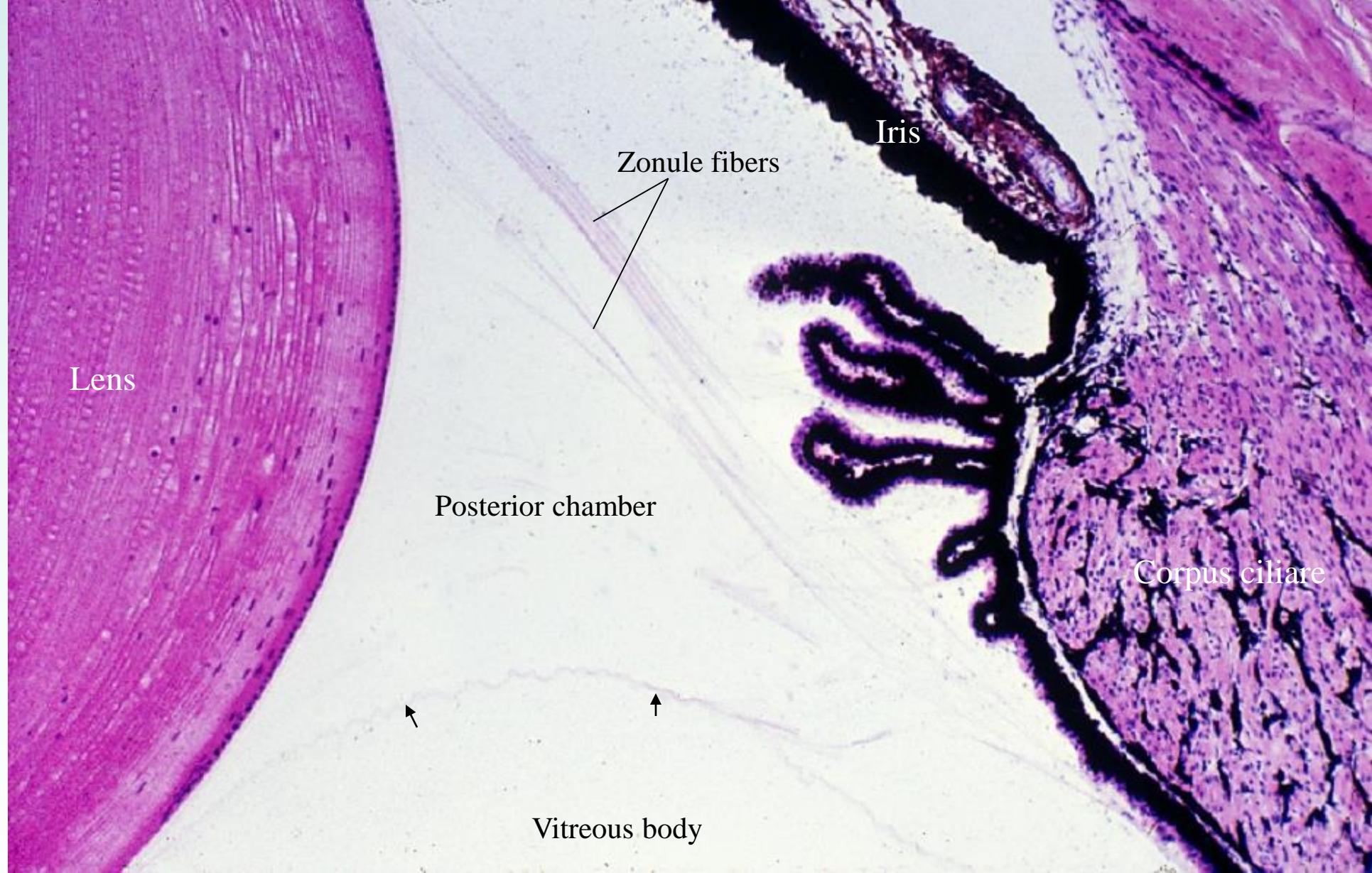


19-25 Iridocorneal angle, 1. Monkey, H-E stain, x 6.

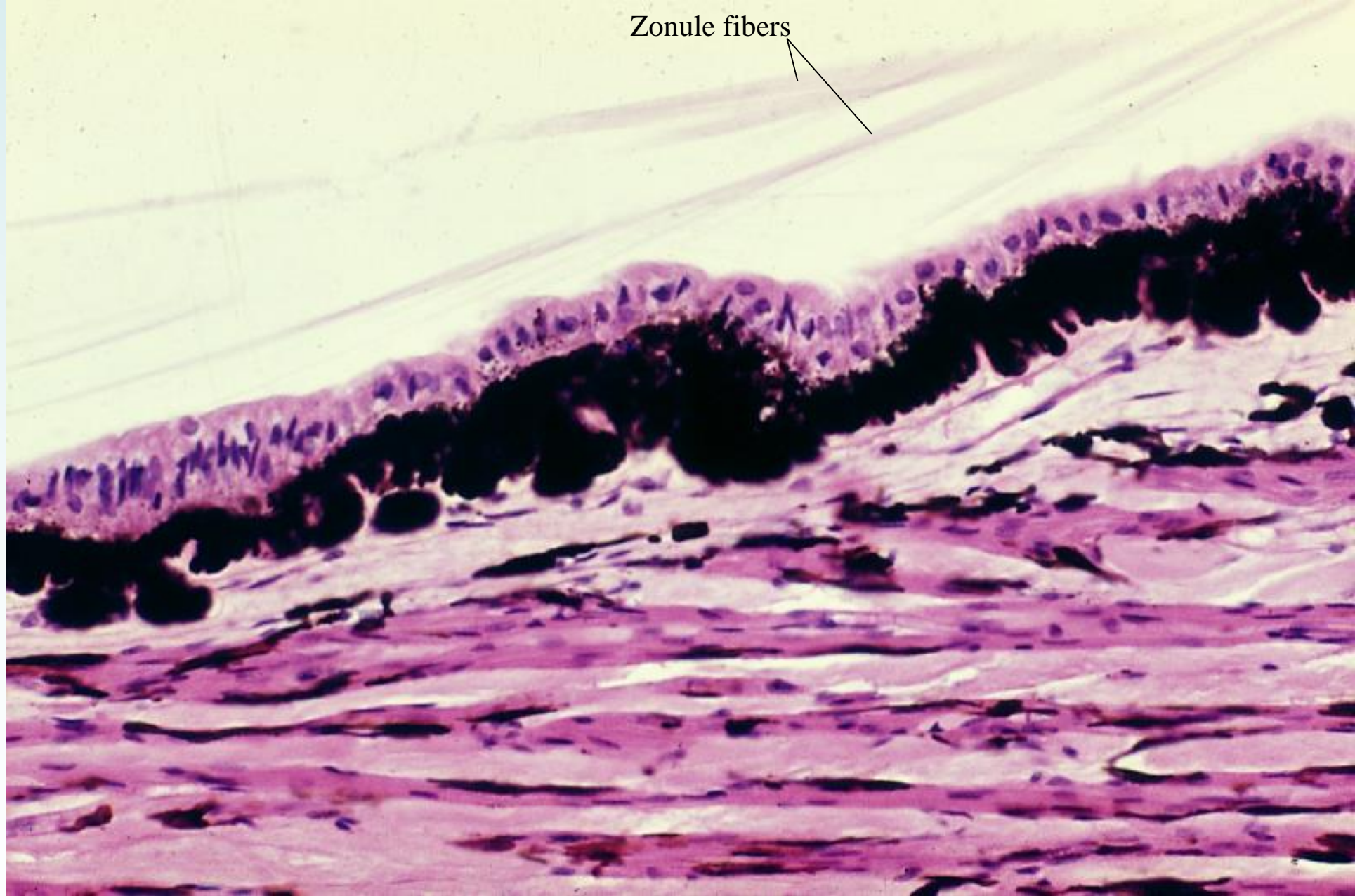


19-26 Iridocorneal angle, 2. Canal of Schlemm. Monkey, H-E stain, x 40.

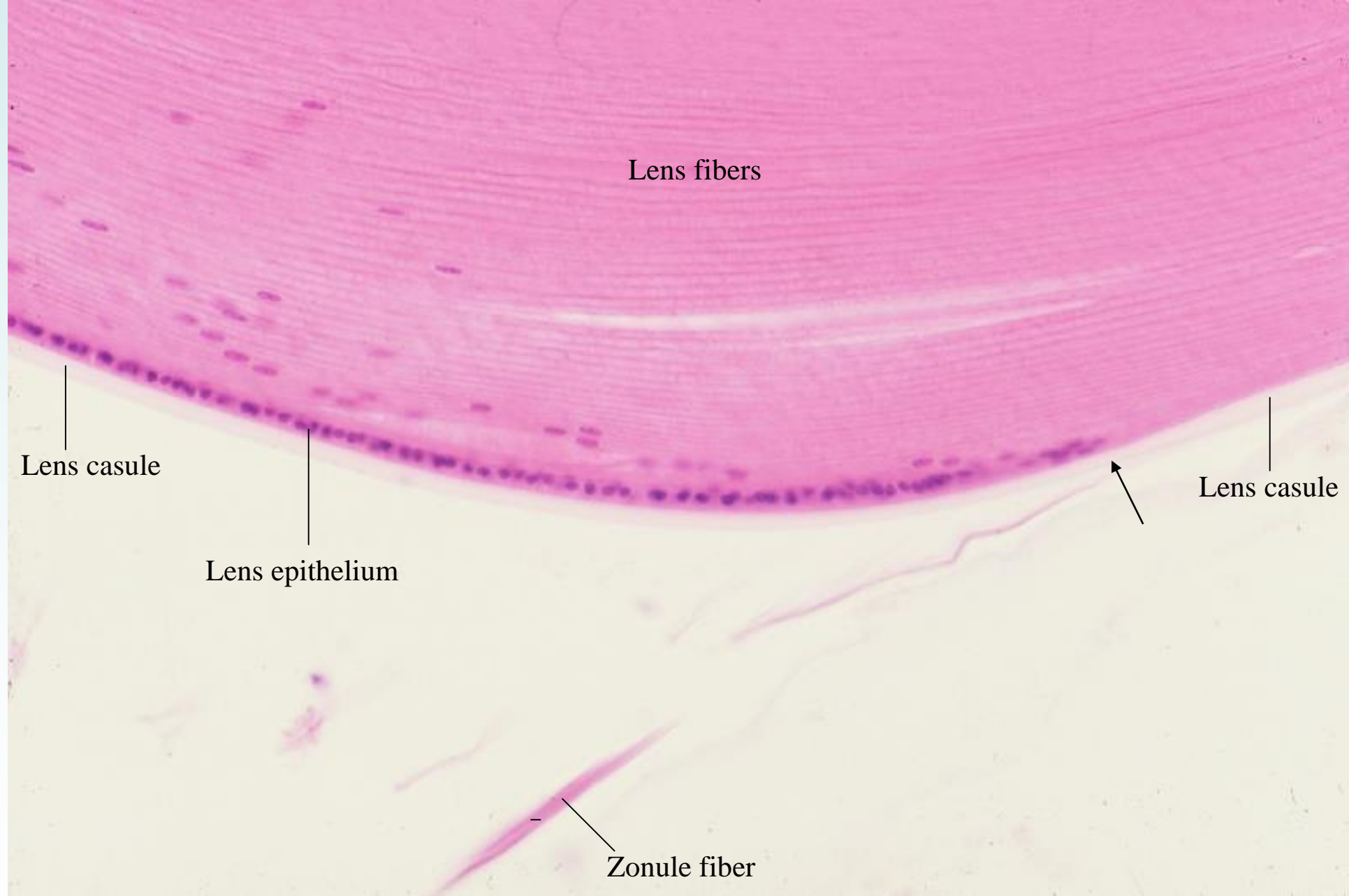




19-28 Corpus ciliare, iris, and lens. Monkey, H-E stain, x 25.



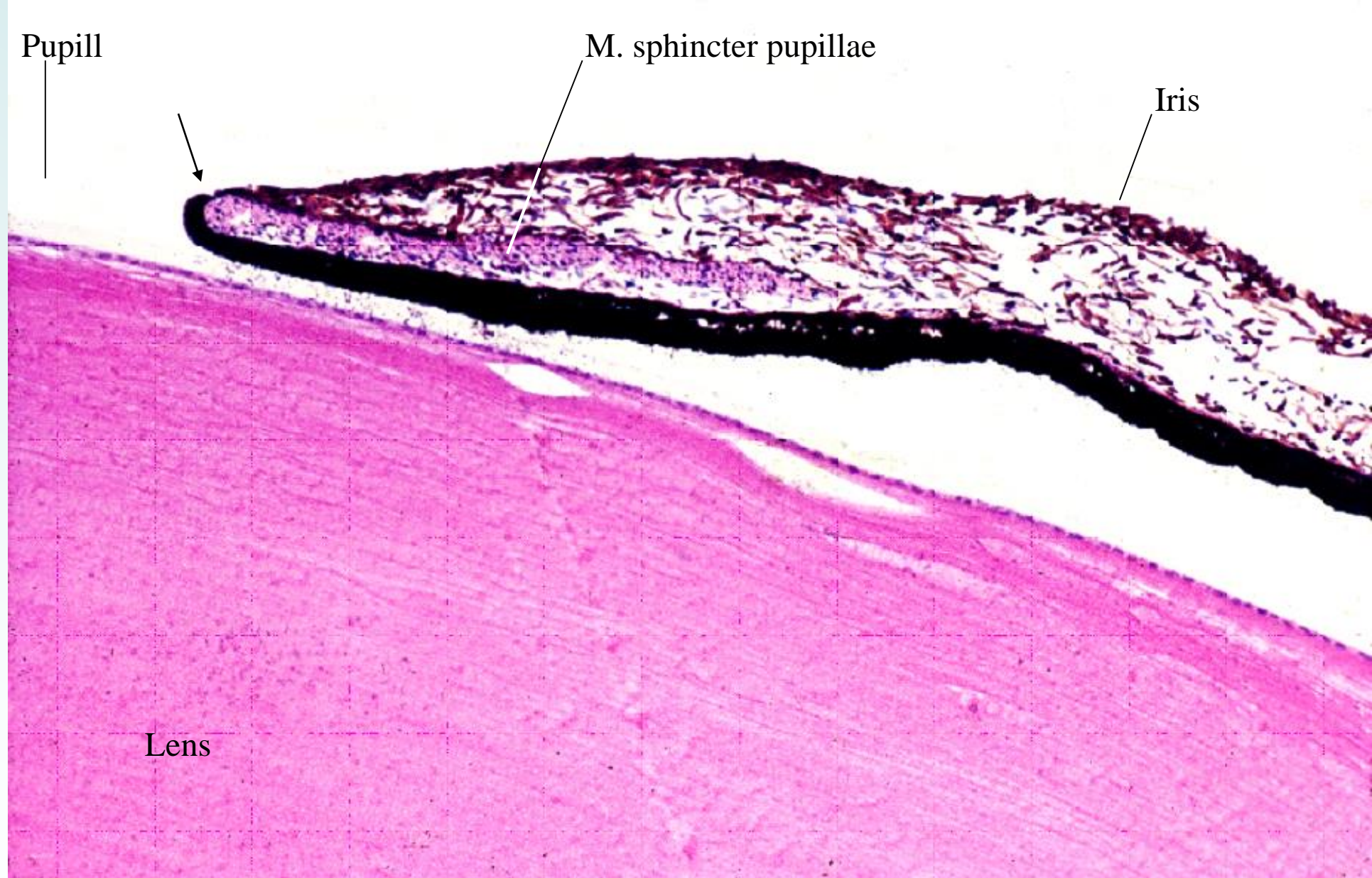
19-29 Pars ciliaris retinae. Monkey, H-E stain, x 64.



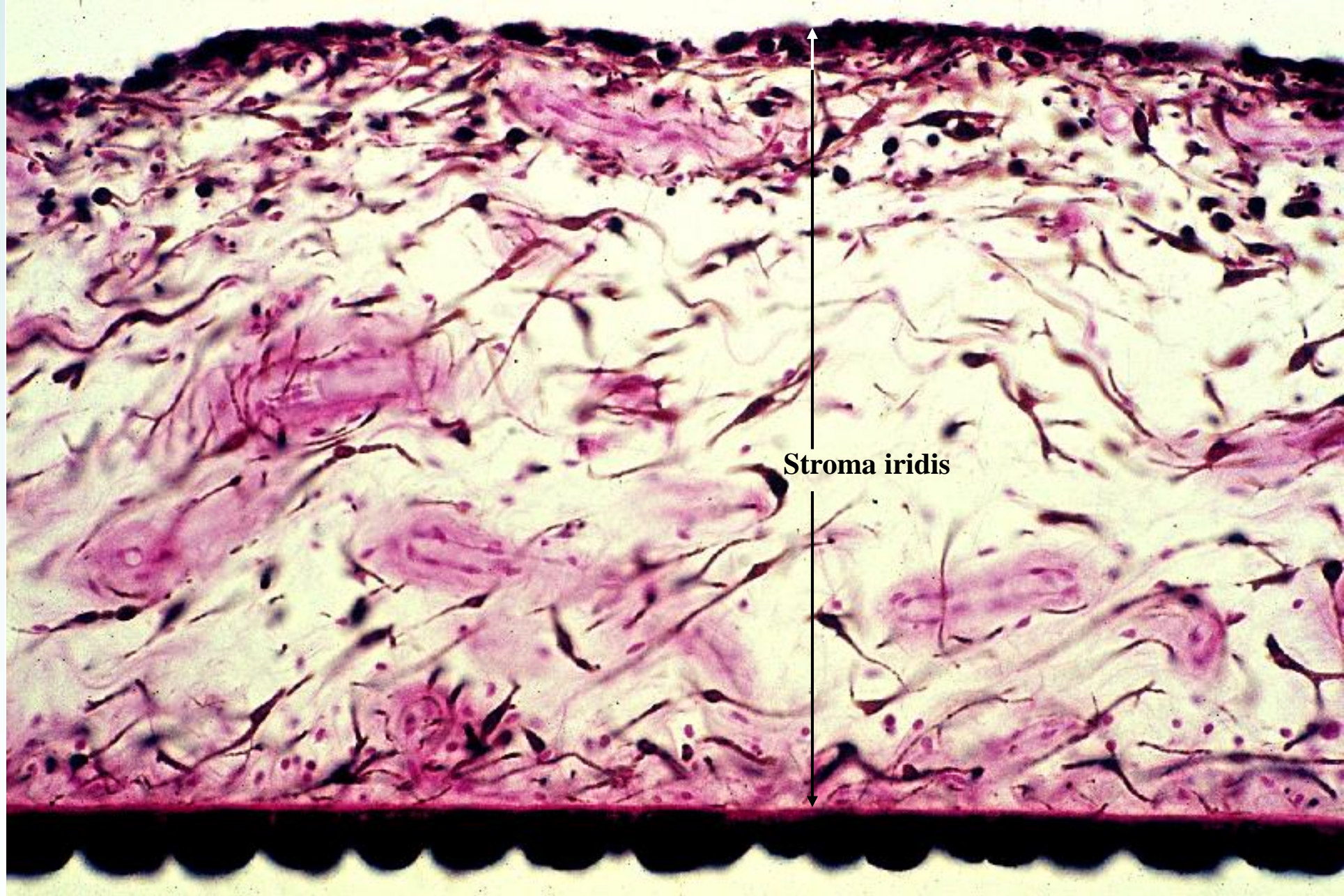
19-30 Equatorial portion of lens. Monkey, H-E stain, x 50.



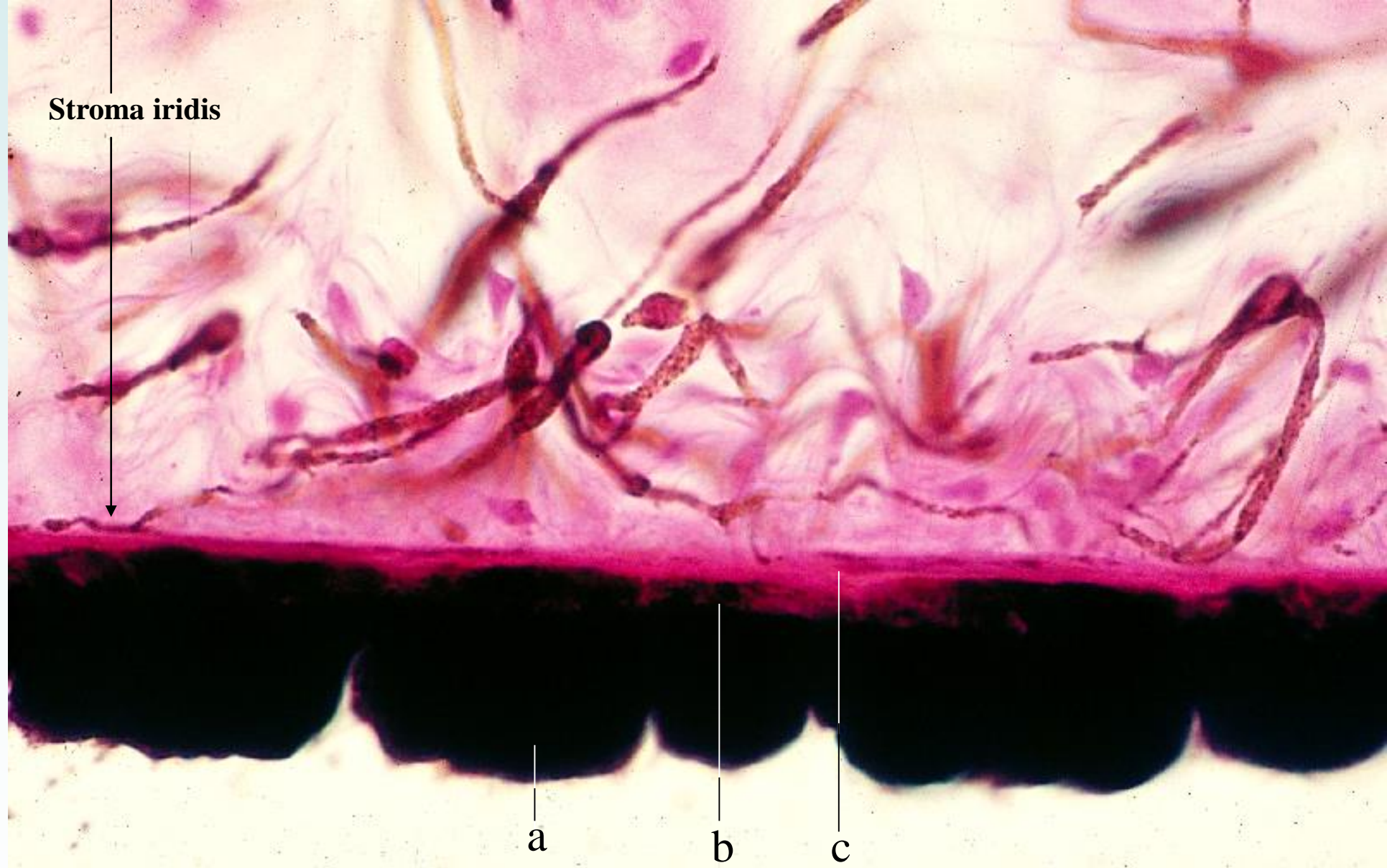
19-31 Lens and zonule fibers. Monkey, H-E stain, x 100.



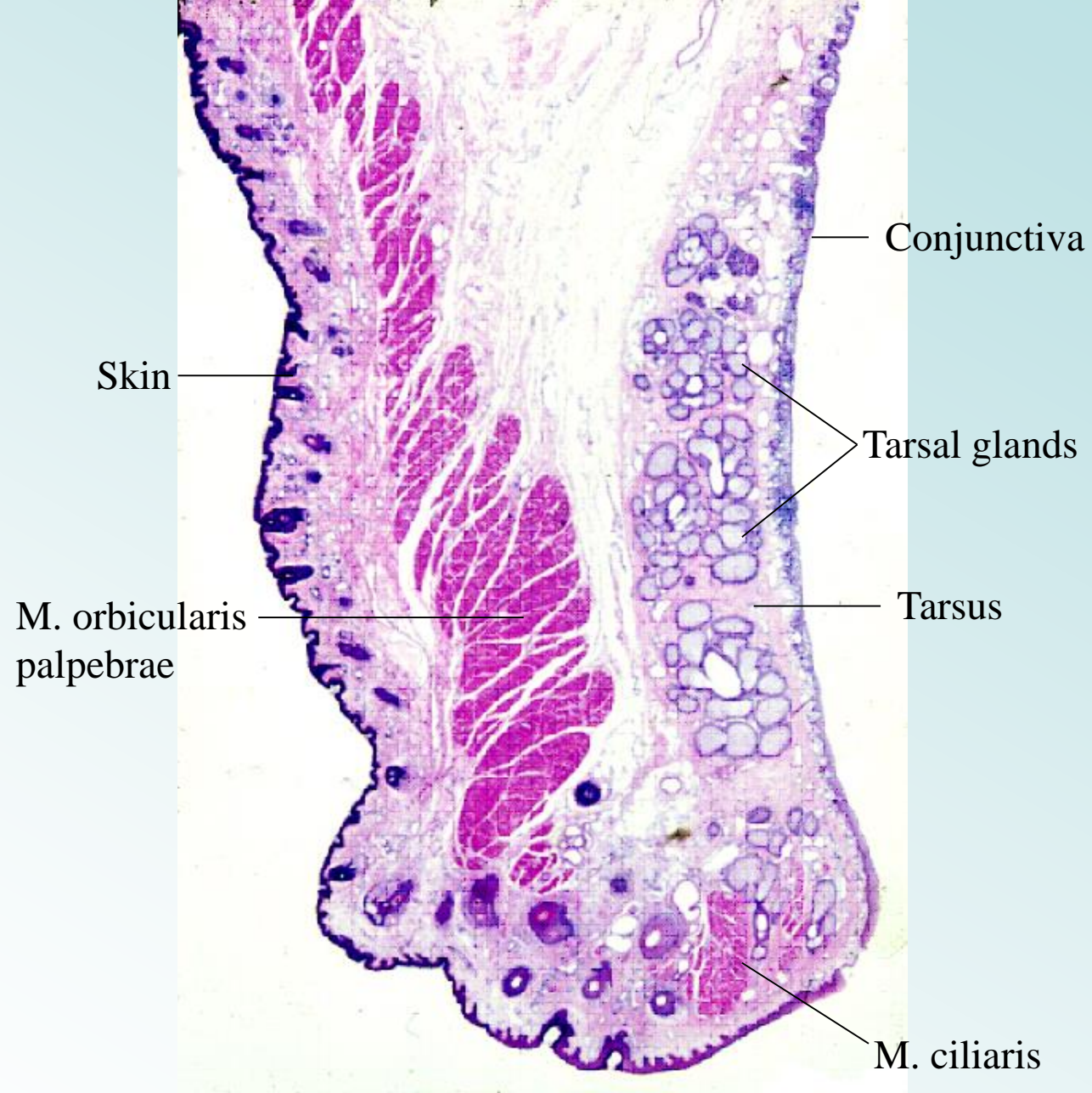
19-32 Lens and pupillar edge of iris. Monkey, H-E stain, x 30.



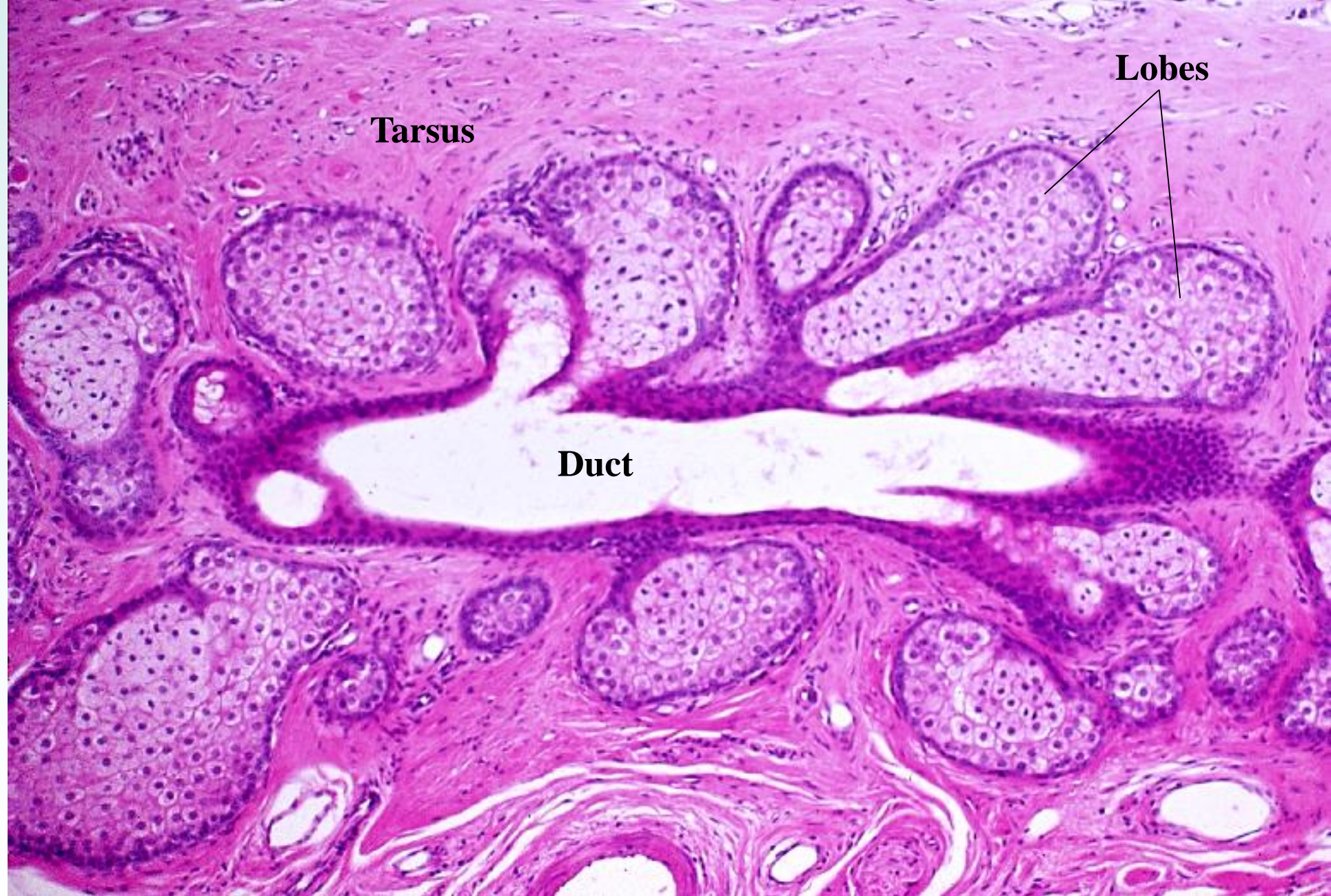19-33 Iris, the whole thickness. Monkey, H-E stain, x 50.



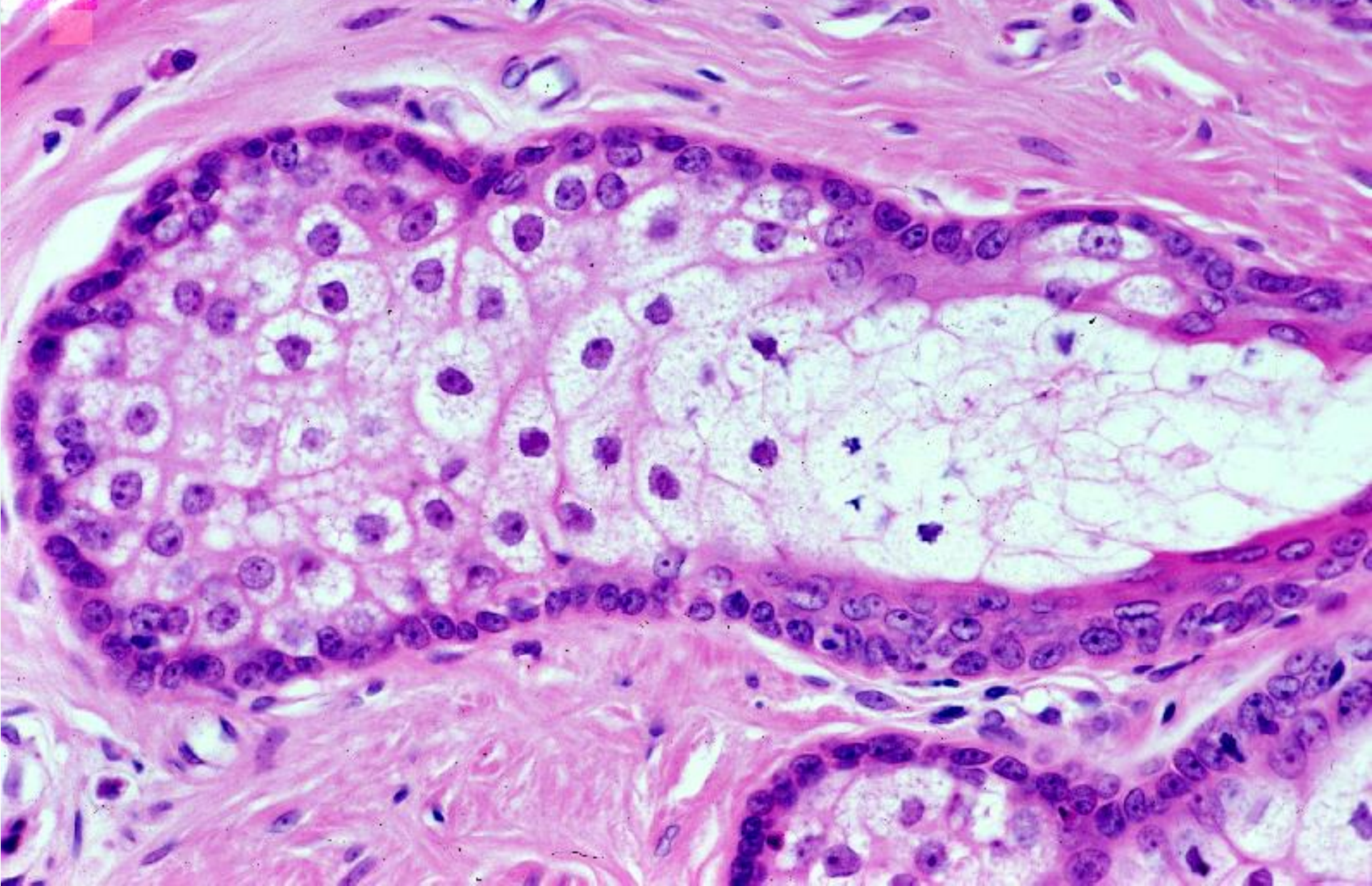
19-34 Posterior portion of iris. Monkey, H-E stain, x 160.



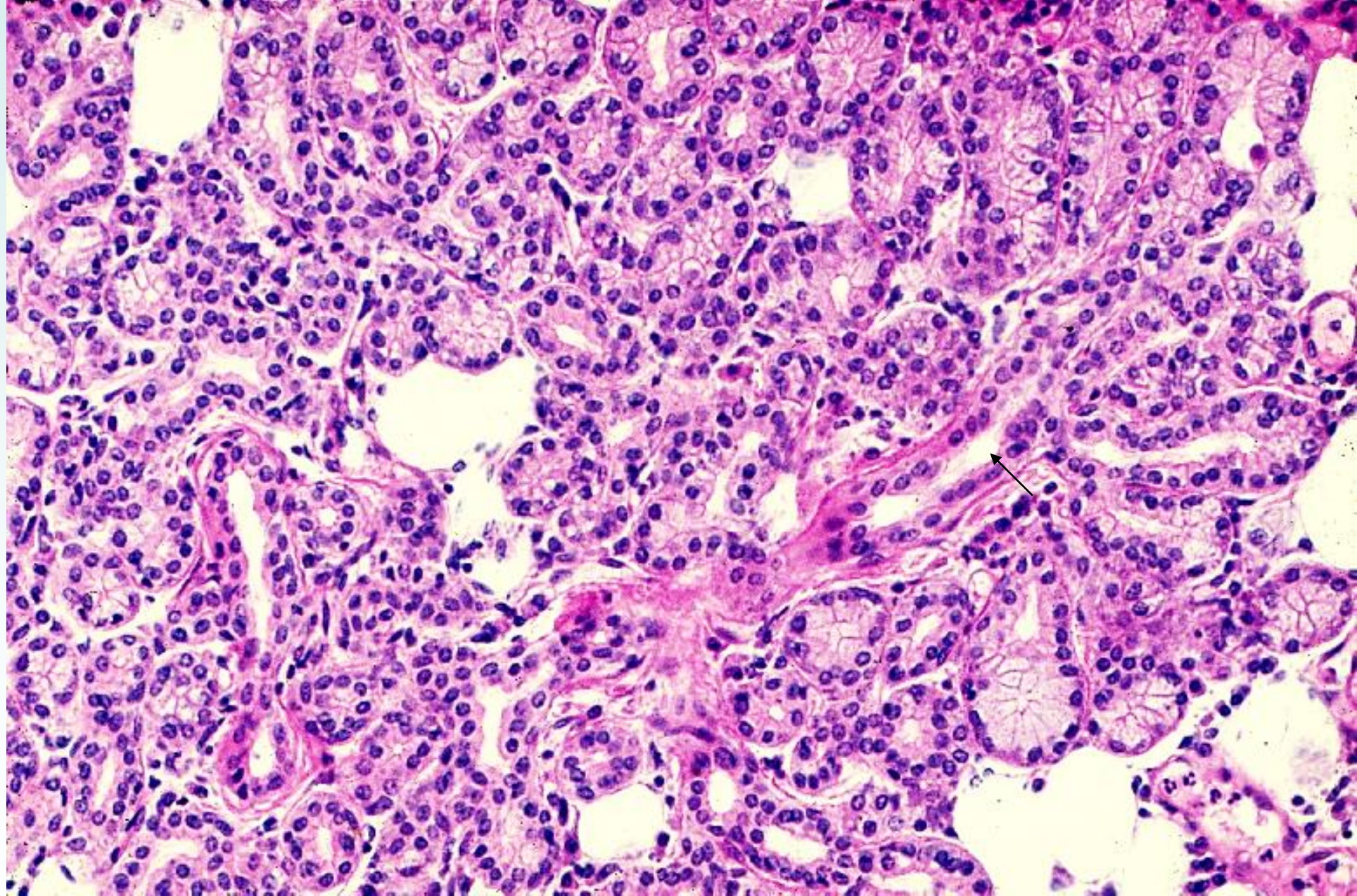
19-35 Eyelid, sagittal section. Human, H-E stain, x 4.0.



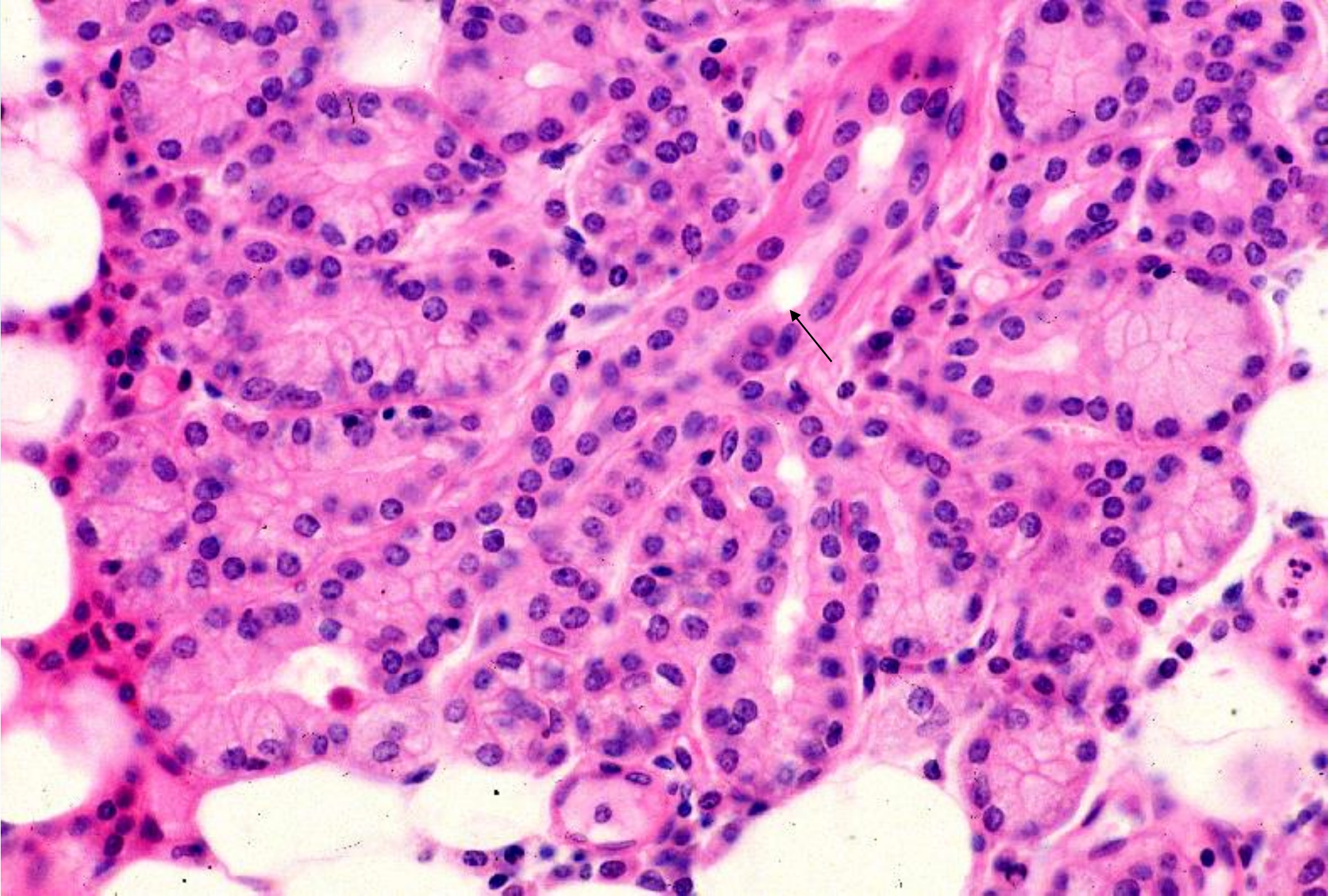
19-36 Tarsal glands. Human, H-E stain, x 10.



19-37 A lobe of tarsal gland. Human, H-E stain, x 100.



19-38 Lacrimal gland, 1. Human, H-E stain, x 64.



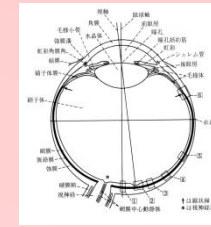
19-39 Lacrimal gland, 2. Human, H-E stain, x 100.

19-00 Visual Organs

- The visual organs are one of the most highly differentiated sensory organs and consist of the eyeballs and accessory organs, namely eye muscles, lacrimal glands and eye lids. The eyeballs perceive bright- and darkness of the environment and form and color of the objects in environment.

19-001 Eyeballs

19-01 Scheme showing the horizontal section of right eyeball.



- The eyeball is a somewhat elongated spherical body, of about 24 mm in diameter, with a hemispherical projection in front. The axis through the anterior and posterior poles is called the anatomical axis and that through the center of the lens and the center of the central fovea is the visual axis.
- The lines of the surface of the eyeball crossing the plane including the anatomical axis are called the meridian lines and that crossing the plane perpendicular to the anatomical axis are the altitudes, the largest of that is the equator.
- The eyeball consists of the outer wall and inner contents.
- The anterior segment of the eyeball is the transparent cornea, and posterior segment, the sclera, consists of dense connective tissue layers. The cornea and sclera compose the thick fibrous coat which protects the delicate inner structures of the eye and, together with the intraocular fluid pressure, serves to maintain the shape and turgor of the eyeball. The inner surface of the sclera is covered by the dark chorioidea, rich in blood vessels and pigment cells, and the retina, the layer of the photocensitive cells.
- The cavity of the eyeball is filled by the transparent media. Posterior to the cornea, the anterior chamber is filled by aqueous humor, which fills also the posterior chamber, posterior to the iris and anterior to the lens. Posterior to the iris is a big transparent bi-convex lens and further posteriorly, a large cavity, the vitreous cavity, is filled by vitreous body.
- About 3 mm medial (nasal) to the posterior pole of the eyeball there is a pink disk, about 1.4 mm in diameter, the papilla of the optic nerve. From here the optic nerve leaves the eyeball and goes to the brain. At about 1 mm lateral (temporal) to the posterior pole there is a small round shallow depression, the fovea centralis, the site of the maximal visual acuity.
- Around the lens, the chorioidea constitutes the ciliary body and iris. The ciliary body consists of smooth muscle fibers and forms a flat and long triangular protrusion into the posterior chamber. The iris is a thin membranous projection covering anterior surface of the lens, at the central portion of which there is a round hole, the pupil. The diameter of the pupil is changed according to the brightness of the environment and thus the light entering the eyeball is controlled. The surface of the ciliary body and the posterior surface of the iris are covered by the pars caeca retinae, namely, pars ciliaris retinae and pars iridica retinae, respectively.

19-02 Table showing the structure of the eyeball.

		前 部	後 部
眼 球 壁	眼球繊維膜	角 膜	強 膜
	眼球血管膜	虹彩と毛様体	脈絡膜
	眼 球 内 膜	網膜首部* (網膜虹彩部と 網膜毛様体部)	網膜(視部)
内 容 物		眼房水と水晶体	硝子体

*網膜首部は虹彩と毛様体の構成要素となっている。

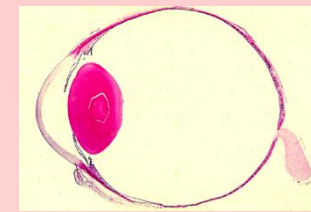- This table is to show the constituents of the eyeball, that are described in 19-01.

19-03 Eyeball, horizontal section 1. General view. Monkey, H-E stain, x1.2.



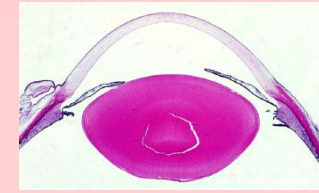
- This is a general view of a horizontally sectioned right eyeball. All structures of the eyeball, described in 19-01, are well demonstrated. This section, made in the year 1988, is about $30\text{ }\mu\text{m}$ thick, so that this is suitable for low power magnification but not for the precise observation of details. Compare with 19-04, of about $20\text{ }\mu\text{m}$ thick !

19-04 Eyeball, horizontal section 2. General view. Monkey, H-E stain, x1.6.



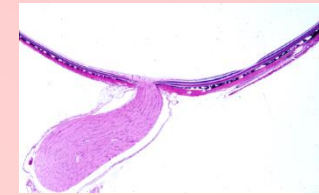
- This specimen was made in the year 1964 and is about $20\text{ }\mu\text{m}$ thick. Because of the thinness, details of the structures are more precisely observed than in the 19-03. Following figures 19-05 to 19-08, 19-14 to 19-20, 19-22 to 19-25, 19-27 and 19-29 to 19-34 are all made from this specimen.
- Although the substance of the cornea and the sclera consists commonly of dense collagenous fiber bundles, but their appearance and stainability are quite different. The cornea is perfectly transparent and stains light pink in H-E stain, whereas the sclera is opaque white and stains deep red. In this figure such difference in color is evident. Along the boundary between the cornea and sclera there is a line, sulcus sclerae, which is caused by the difference of their radius.

19-05 Anterior portion of the eyeball. Monkey, H-E stain, x 2.0.



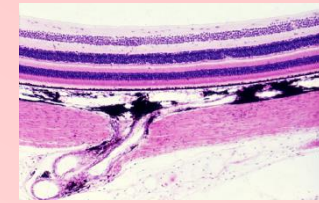
- At the center of the figure, is a large biconvex lens, stained deep red, and directly anterior to it covers a thin membrane, the iris, with a central hole, the pupil. The cavity anterior to the lens and iris is the anterior chamber which is enclosed anteriorly by the hemispherical cornea, stained faint pink, that shifts posteriorly into the sclera, stained deep red. The angle between the periphery of the cornea and the root of the iris is called the iridocorneal angle (arrow). The cavity posterior to the iris and around the lens is called the posterior chamber, into which protrudes a long flat triangular body, the corpus ciliare, from the inner surface of the sclera. The large cavity posterior to the lens is the vitreous cavity, filled by vitreous body.

19-06 Posterior portion of eyeball. Monkey, H-E stain, x 4.0.



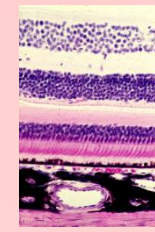
- About 3 mm medial (nasal) to the posterior pole of the eyeball there is a pink disk, about 1.4 mm in diameter, the papilla of the optic nerve (✕). From here the optic nerve leaves the eyeball and goes to the brain. At about 1 mm lateral (temporal) to the posterior pole there is a small round shallow depression, the fovea centralis, the site of the maximal visual acuity.
- The wall of the eyeball consists of three layers, the retina, the chorioidea, and the sclera. The sclera continues to the dural sheath of the optic nerve.

19-07 Posterior wall of eyeball. Monkey, H-E stain, x 30.



- Higher magnification of 19-06. Here the wall of the eyeball consists of three layers: the retina, the chorioidea, and the sclera. The retina is the thickest and composed of orderly arranged several layers (see later !). The chorioidea consists of numerous blood vessels, of large and small calibers, intermingled by numberless pigment cells. The sclera is composed of very densely arranged collagen fiber bundles. In the middle of this figure, arteries are entering into the chorioidea; they are long posterior ciliary arteries.

19-08 Retina, 1. Monkey, H-E stain, x 100.

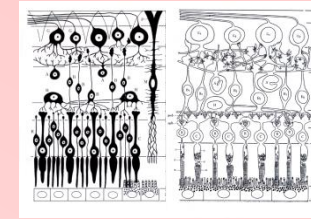


- Higher magnification of the portion temporally adjacent to the fovea centralis, indicated with [3] in the figure 19-01. The orderly stratified structure of the retina is here very conspicuous, namely ten parallel layers are distinguished from top downward:
 1. Inner limiting membrane.
 2. Layer of optic nerve fibers.
 3. Layer of ganglion cells.
 4. Inner plexiform layer.
 5. Inner granular (nuclear) layer.
 6. Outer plexiform layer.
 7. Outer granular (nuclear) layer.
 8. Outer limiting membrane.
 9. Layer of cones and rods.
 10. Pigment epithelium.

Surrounding the retina follow the chorioidea and sclera:

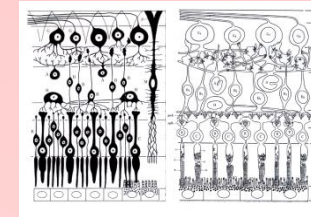
 11. Lamina choriocapillaris.
 12. Lamina vascularis.
 13. Sclera.
- Around the fovea centralis, exterior to the outer plexiform layer there is a thick layer of parallel nerve fibers, layer of Henle (6b).

19-09 Scheme showing the structure of retina, based on the Golgi method and electron microscopy. (1/2)



- Among the constituents of the retina, the photosensitive cells are exclusively cone- and rod-cells. Cones and rods are the photosensitive protoplasmic processes of the cone- and rod-cells, respectively, connected to the main cytoplasm with a tiny stalk. The cone- and rod-cells are neurons, consisting of cones and rods, the cytoplasm proper containing the nucleus, and the proximal axon with a terminal swelling, which makes synapses with the bipolar cells, neurons of the second order.
- Cones mediate the daylight vision, namely, they discriminate the two points as two points and sense colors, whereas rods mediate brightness, especially in dim light.
- The retina consists of neurons, arranged in three orders.
- The first order is photosensitive cells, the cone- and the rod-cells, whose cones and rods react to light and generate the nervous signals. These signals are relayed at the proximal ends of the axon to the neurons of the second order, the bipolar cells, with synapses at the outer plexiform layer. The nucleus and surrounding cytoplasm of the cone- and rod-cells constitute the outer granular layer.
- The neurons of the second order, bipolar cells, constitute the inner granular layer. Their distal axons make synapses with the proximal ends of the cone- and rod-cells and accept the nervous signals, which are, in turn, transferred by their proximal axons to the neurons of the third order, optic nerve cells, with synapses in the inner plexiform layer. In the inner granular layer there are more two kinds of neurons, horizontal cells and amacrine cells; the former connect horizontally the cone- and rod-cells and the latter, the optic nerve cells, the third neurons.

19-09 Scheme showing the structure of retina, based on the Golgi method and electron microscopy. (2/2)



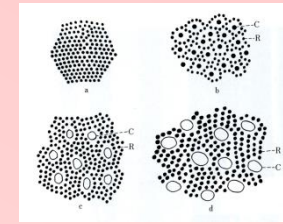
- The neurons of the third order are the optic nerve cells, which accept the nervous signals from the bipolar cells by the synapses on their dendrites in the inner plexiform layer and send them to the brain by their axons. Their nucleus and cytoplasm are small and densely packed in the vicinity of the fovea centralis, but as leaving there they become larger in size and less numerous in number. The nucleus and cytoplasm constitute the layer of ganglion cells and their axons, the layer of optic nerve fibers.
- In the inner granular layer there are nuclei of the special supporting cells: Mueller cells. Their cytoplasm is long and penetrates the whole thickness of the retina and their proximal and distal ends constitute the inner and outer limiting membrane, respectively.
- The pigment epithelium is a sheet of heavily pigmented epithelial cells, which derived from the outer layer of the cup-like embryonic optic vesicle. Each cell provides at the apical surface numerous long processes densely containing the melanin pigments which interdigitate with the external segments of cones and rods. But there is no actual anatomical connection between the photosensitive and the pigmented layers. The pigment epithelium is opaque and absorbs the light coming through the retina.
- Such structural details were first clarified by the observations using Golgi method and recently by the electron microscopy.

19-10 Table showing the path-way of light and neuronal conduction.

光の入射する方向	網膜の層構造	網膜を構成する細胞	視覚情報伝達の方法	
↓	1. 内障界面	d. 視神経細胞	↑	
	2. 視神経線維層			
	3. 視神経細胞層			
	4. 内網状層	c. 双極神経細胞		
	5. 内網状層			
	6. 外網状層	b. 網状体細胞と杆状体細胞		
	7. 外網状層			
	8. 外障界面			
	9. 網状体・杆状体層	a. 色素上皮細胞		
	10. 網状色素上皮層			

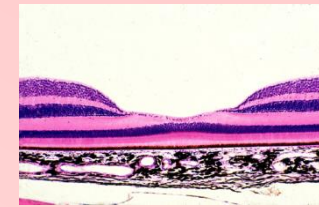- This table shows the stratified arrangement of the retinal structures and also of the constituent neurons of three orders. It is clear, that the photosensitive cones and rods are located at farthest from the lens and structures proximal to them hinder, more or less, the visual acuity (see 19-11 and 19-12 to 19-15 !).

19-11 Scheme showing the distribution of cones and rods.



- This is to show the distribution of cones and rods, reported by R. W. Young (1971).
- As described in 19-09, the visual acuity, discrimination of two points and sense of color, is concerned exclusively with the function of the cones, this scheme gives us the substantial basis. At the center of the fovea centralis there are exclusively cones, slender in form, and very densely packed. As leaving the fovea centralis cones become rapidly thick and less numerous and, on the contrary, rods increase in number and densely packed.

19-12 Fovea centralis, 1. Monkey, H-E stain, x 25.



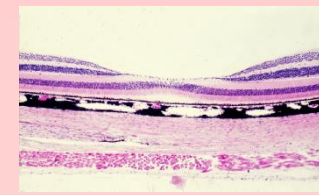
- To realize the highest visual acuity at the fovea centralis, cones should be very densely packed, so that they become slender and tall in shape. As is seen in this figure, at the center of the fovea centralis the outer limiting membrane makes a gentle rising. As described in 19-09 and 19-10, all structures proximal to the layer of cones hinder, more or less, the visual acuity, they make way for the light ray coming through the center of the lens to the fovea centralis. As these structures move away from the visual axis a hollow is realized, the fovea centralis. As is seen in this figure all structures proximal to the outer granular layer are shifted away from the visual axis. The bottom of this hollow corresponds to the top of the rising of the outer limiting membrane.

19-13 Fovea centralis, 2. Monkey, H-E stain, x 50.



- Higher magnification of the temporal half of 19-12.
- At the central area of the fovea centralis cones are the most slender and the tallest and very densely packed, and as leaving there they become gradually thicker and lower, so that the outer limiting membrane makes a gentle rising with a top at the central area. As all structures proximal to the outer granular layer hinder, more or less, the visual acuity, to realize the highest acuity they move away from the visual axis and a hollow is developed; this is the fovea centralis. Between the top of the rising of the outer limiting membrane and the bottom of the hollow there are only a few nuclei and nerve fibers, except for outer granular layer. Inferior to the layer of cones the pigment epithelium and the chorioidea are orderly arranged.
- As the bipolar cells and optic nerve cells move away from the fovea centralis, the proximal axons of cone-cells run radially some distance from the center to the periphery and then turn upward in the outer plexiform layer to make symapses. Thus, around the fovea centralis a thick layer of the radially running axons of cone-cells is developed; this is called the layer of Henle (LH).

19-14 Fovea centralis, 3. Monkey, H-E stain, x 25.



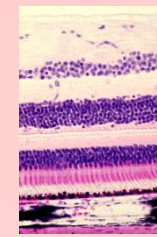
- Higher magnification of 19-04. This specimen was made in the year 1964 and succeeded in sectioning of about $20\text{ }\mu\text{m}$ thick and in staining with good hue. In this specimen structures of eyeball are well observed in detail. About the structural specificities see the descriptions of 19-12 !
- In this figure, the retina, chorioidea and sclera are well identified. In the left half of the figure the N. ciliaris longus runs transversely in the sclera and at the lowermost portion of the figure M. obliquus inferior is seen.

19-15 Fovea centralis, 4. Monkey, H-E stain, x 64.




- Higher magnification of the temporal half of 19-14. As this specimen is thin, structural details are precisely observed. At the right end of this figure constituents of the layer of cones and rods, practically only cones, are somewhat thick. Approaching the left end they become thinner and taller and concomitantly the outer limiting membrane rises and arrives at top at the center of fovea centralis, where nuclei of the outer granular layer, of cone-cells, are arranged loose and layer of their axons is extremely thin, so that the ray coming through the center of the lens arrives directly at the cones. Thus the highest acuity of sight is realized. Axons starting the cones locating in the central area of the fovea centralis radiate and run some distance, then turn upward shortly and end with terminal swelling, with which make synapses the bipolar cells of the inner granular layer. In this figure the thick layer of the axons of cone- (and rod-) cells, the layer of Henle (LH), is evident.
- In this figure structures of the chorioidea, lamina choriocapillaris and lamina vasculo- laris, are well identified.

19-16 Retina, 2. Monkey, H-E stain, x 100.



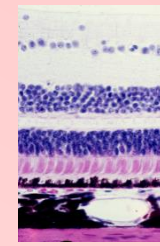
- Higher magnification of the portion between the fovea centralis and optic nerve papilla, indicated with [1] in the figure 19-01. As this portion is neighboring of the optic nerve papilla, the layer of the optic nerve is very thick but the ganglion cells in the ganglion cell layer are less numerous. The outer plexiform layer consists of the plexiform layer proper (6a) and the layer of Henle (6b). In the 6a the terminal swellings of the axons of cone- (and rod-) cells, orderly lined tiny elliptic points, are obviously recognized.
- In the layer of cones and rods (9) rods are identified as thin filaments among the cones, of which thick and deep red stained inner segments and thin filamentous outer segments are clearly identified. Interdigitation of these outer segments with the pigmented cilia of the pigment epithelial cells is conspicuous.
- The lamina choriocapillaris (11) and lamina vascularis (12) of the chorioidea are clearly distinguished.

19-17 Retina, 3. Monkey, H-E stain, x 100.



- Higher magnification of the portion, further temporal to [3], indicated with [4] in the figure 19-01. In this portion optic nerve cells in the layer of ganglion cells (3) are markedly reduced in number and in the inner plexiform layer (6) the layer of Henle is no longer recognized. Nuclei in the outer granular layer are very densely packed. In the layer of cones and rods (9) cones and rods are distinctly identified.

19-18 Retina, 4. Monkey, H-E stain, x 160.



- Higher magnification of the portion, temporal to [4], indicated with [5] in the figure 19-01. In this portion optic nerve cells in the layer of ganglion cells are only a few and the size of their nuclei is evidently larger than in the previous figures. The arrangement of nuclei in the inner granular layer is conspicuously looser than 19-16 and 19-17. The inner segments of cones are here very thick and stained deep red and easily identified from the thin filamentous outer segments. Among cones numerous rods are seen. The long pigmented cilia of the pigment epithelial cells are evident. In the outer plexiform layer terminal swellings of the proximal axons of the cone- and rod-cells are here elliptic in shape and horizontally arranged in one line.

19-19 Retina, 5. Ora serrata. Monkey, H-E stain, x 30.



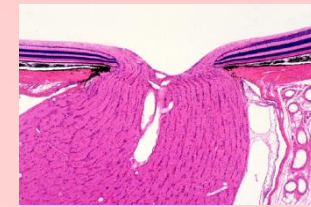- This is to show the ora serrata, indicated by an arrow, the boundary between the optical retina and the blind retina, pars caeca retinae. The optical retina, the right half of the figure, consists of several orderly layers, which here merge into the blind retina, the left half of the figure, consisting of only one layer of nuclei.
- The pigment epithelium, chorioidea, and sclera continue and underlie the blind retina. The sclera is here very thick.

19-20 Chorioidea. Monkey, H-E stain, x 160.




- In this figure, a part of retina (outer granular layer (7), outer limiting membrane (8), layer of cones and rods (9), and pigment epithelium (10)), chorioidea (11 and 12), and sclera (13) are shown.
- In the retina thick and deep red stained inner segments of cones and rods are distinctly identified from their thin filamentous outer segments. The long pigmented cilia of the pigment epithelial cells interdigitate with the outer segments of cones and rods.
- The chorioidea consists of lamina choriocapillaris (11), capillary network arranged in one plane directly underlain the pigment epithelium, and lamina vasalis (12), consisting of multitude of large and medium-sized arteries and veins. The spaces between the vessels are filled with loose connective tissue rich in melanocytes.
- The sclera consists of dense lamellar connective tissue, whose fiber bundles run various directions parallel to the surface.

19-21 Papilla nervi optici. Monkey, H-E stain, x 10.



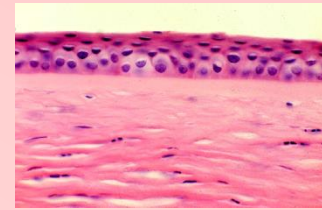
- Higher magnification of the optic nerve papilla of the figure 19-03. About 3 mm medial (nasal) to the posterior pole of the eyeball there is a pink disk, about 1.4 mm in diameter; this is the papilla of the optic nerve. Optic nerve fibers starting every part of the retina converge here and turn backward, penetrate the sclera, and then constitute all together one thick “optic nerve” and leave the eyeball. At the penetrating place the arrangement of the collagen fibers of sclera becomes loose. This place is called lamina cribrosa sclerae. Within the retina, optic nerve fibers have no myelin sheath but directly after the penetration, they are given the myelin sheath by the oligodendroglia.
- The optic nerve is essentially not one of the peripheral nerves but a part of the brain, so that it is covered by the meninges, namely, pia mater, arachnoidea, and dura mater. In this figure, they are indicated by P, A, and D, respectively. The dural sheath (D) unites with sclera tightly.
- Through the axial portion of the optic nerve the central artery (a) enters into the interior of the eyeball. It divides into four main branches that disperse from the center of the optic nerve papilla and run on the inner surface of the retina and nourish the inner two thirds of the retina, namely, the bipolar cells and optic nerve cells. The central vein (v) runs concomitantly with the central artery and leaves the eyeball through the axial portion of the optic nerve.
- Within the area of the optic nerve papilla, because there are no photosensitive elements, the light ray falling this area is not perceived.

19-22 Cornea 1. Monkey, H-E stain, x 64.



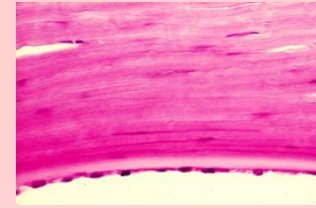
- The cornea constitutes anterior one fifth of the wall of the eyeball, measuring about 11 mm in diameter, 0.8 ~ 0.9 mm at the center and 1.1 mm at the periphery in thickness, and its radius is about 7.8 mm. It is transparent and its refractive index is 1.376. At the posterior end it continues with sclera, where a faint groove, sulcus sclerae, is caused by the difference of radius of the cornea and sclera,
- The cornea consists of ① epithelium, ② Bowman's membrane, ③ substantia propria, ④ Descemet's membrane, and ⑤ endothelium, from front backward.

19-23 Cornea 2. Anterior portion. Monkey, H-E stain, x 130.



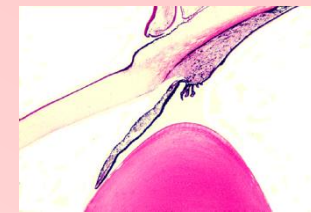
- The epithelium is the non-keratinizing squamous epithelium consisting of five to seven layers of cells, connected with one another by many short processes. The surface cells are quite flat but still contain nucleus. The basal cells are cylindrical in shape and rest on a thick and conspicuous homogeneous layer, Bowman's membrane, which has been traditionally described as basement membrane.
- The Bowman's membrane, 6 to 9 μ m thick, stains homogeneously pink, and is the outermost layer of the substantia propria, from which it cannot be separated. Electron-microscopically it consists of a feltwork of randomly arranged collagen fibrils and does not contain elastin.
- The substantia propria forms about 90% of the thickness of the cornea. It is a transparent regular lamellar connective tissue whose collagen bundles form thin lamellae arranged in numerous layers. In each layer, the direction of the bundles changes and those in successive layers cross at various angles. The lamellae everywhere interchange fibers and, thus, are kept tightly together. The fibrils are regularly arranged with an interspace of 55 nm from one another, and spaces between them and those between bundles and lamellae are filled with ground substance. The cells of the substantia propria are long, slender fibroblasts lodged in narrow clefts among the parallel bundles of collagen fibrils.

19-24 Cornea 3. Posterior portion. Monkey, H-E stain, x 160.



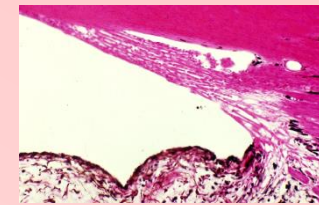- The posterior surface of the cornea is covered by the endothelium, a layer of flat squamous cells, that originate from the embryonic mesenchyme. They rest on a thin homogenous zone, the membrane of Descemet.
- The membrane of Desemet is about $5\mu\text{m}$ thick and can be isolated from the posterior surface of the substantia propria. It is essentially a very thick basal lamina of the endothelium.

19-25 Iridocorneal angle, 1. Monkey, H-E stain, x 6.



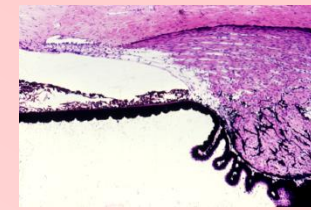
- At the junction of cornea and sclera a faint groove is formed because of the difference of radius of cornea and sclera; this is sulcus sclerae. On the inner surface of the cornea, corresponding the sulcus sclerae, is the iridocorneal angle. This angle, between the iris and cornea, is an important place for the eye function, together with surrounding structures, namely, ligamentum pectinatum, canal of Schlemm, corpus ciliare, and iris.
- On the inner surface of the posterior end of the cornea, corresponding the sulcus sclerae, there is a special area consisting of a trabecular meshwork and the canal of Schlemm. They constitute the outflow system for the aqueous humor. This trabecular meshwork is called ligamentum pectinatum.
- Posterior to this meshwork follows a long triangular rising, consisting of smooth muscle fibers, which protrudes from the inner surface of the sclera into the interior of the eyeball. This is the corpus ciliare. From its anterior end projects a thin disc, with a central circular opening, anterior to the lens; this is the iris and the central opening is called the pupil. The space posterior to the iris and surrounding the lens is called the posterior chamber.

19-26 Iridocorneal angle, 2. Canal of Schlemm. Monkey, H-E stain, x 40.



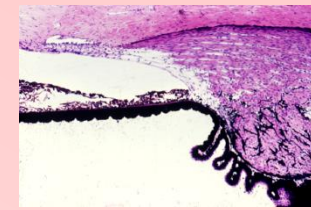
- Higher magnification of 19-03, showing the details of the ligamentum pectinatum and canal of Schlemm.
- On the inner surface of the posterior end of the cornea, from the place, where the membrane of Descemet ends, begins a trabecular meshwork (b) and outside to this is the canal of Schlemm (sinus venosus sclerae). A part of scleral substance projects toward the posterior end of the trabeculae giving them an anchoring ground; this is called the scleral spur (*). Posterior to the trabeculae and interior to the scleral spur continues a more loose trabecular meshwork (a), which is connected with the ciliary body. These trabecular meshworks, together (a) and (b), are called the ligamentum pectinatum and the mesh itself, the space of Fontana. The (a) is called pars chorioidea and (b), pars scleraris of ligamentum pectinatum, respectively.

19-27 Iridocorneal angle, 3. Monkey, H-E stain, x 30. (1/2)



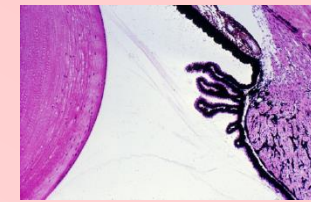
- At the upper left corner is the canal of Schlemm and inferior to this is the pars scleralis (b) of the lig. pectinatum, from which follows right downward the pars chorioidea (a), connecting to the ciliary muscles, constituents of the ciliary body. From the right and inferior end of the pars chorioidea (a), projects the iris leftward.
- If the eyeball is cut across along the equator and its anterior half is seen from within, after removal of the vitreous body, a sharply outlined, dentate border is seen running around the inner surface of the wall in front of the equator. This is the ora serrata, the boundary between the photosensitive and non-photosensitive retina. From the ora serrata to the edge of the lens is the ciliary body, a thickening of the chorioid. Looking at a meridional section of the eyeball, the ciliary body appears as a thin triangle with its small base facing the anterior chamber and attached by its anterior and outer angle to the scleral spur. The long, narrow posterior angle extends backward and merges with the chorioid. The inner aspect of the ciliary body is divided into a narrow anterior zone, ciliary crown, and a broader posterior zone, ciliary ring. On its inner surface, the ciliary crown has 70 radially arranged ridges, the ciliary processes.

19-27 Iridocorneal angle, 3. Monkey, H-E stain, x 30. (2/2)



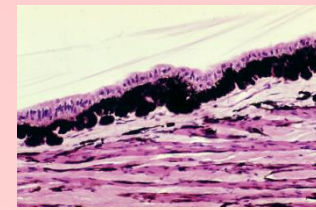
- The bulk of the ciliary body consists of smooth muscle fiber bundles; they are roughly divided into three groups of different directions: ① meridional fibers, ② radial fibers, and ③ circular fibers. Meridional fibers (muscles of Bruecke) begin from the scleral spur and lig. pectinatum and attain the posterior end of the ciliary body and constitute the outermost layers of the ciliary body. Radial fibers begin from the same places as the former and disperse postero-radially and constitute the middle layers of the ciliary body. The muscles, ① and ②, stretch the chorioid and are called the tensor muscle of the chorioid. The contraction of these muscles increases the tension on the lens and makes the lens flatter and sets the focus far. Circular fibers (muscles of Mueller) run circularly and constitute the innermost layers of the ciliary body. The contraction of these muscles relax the tension on the lens and, thus, is important for near vision.
- Inner aspect of the ciliary body is covered by the pars ciliaris retinae, consisting of the ciliary epithelium (pars ciliaris retinae in narrow sense) and the pigment epithelium. The former consists of simple cuboidal cells with round nucleus and faintly pink staining cytoplasm. They produce the aqueous humor. The latter is the anterior continuation of the pigment epithelium of the optic retina. The pars ciliaris retinae forms at the anterior portion of the ciliary body the ciliary processes. Spaces among these muscle fiber bundles are filled by the loose connective tissue containing abundant pigment cells; they are especially dense along the outer aspect of the ciliary body.

19-28 Corpus ciliare, iris, and lens. Monkey, H-E stain, x 25.



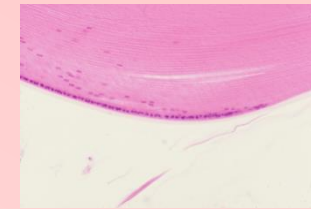
- The inner aspect of the ciliary body and posterior aspect of the iris are covered by the pars ciliaris retinae and pars iridica retinae, respectively. As they originate embryo- logically from the edge of the double-walled optic cup, the apical surface of the non-pigmented ciliary epithelial cells is directed to the apical surface of the pigment epithelial cells. The non-pigmented ciliary epithelial cells shift to the pigmented pars iridica cells. The relationship of them with the pigment epithelial cells is the same as that of the ciliary body.
- The inner surface of the non-pigmented ciliary epithelial cells is the basal surface, invested by the basal lamina, which is continuous with the inner limiting membrane of the retina. The outer surface of the pigment epithelial cells facing the ciliary muscles is also the basal surface, covered by the basal lamina which is continuous with the Bruch's membrane of the chorioidea.
- The lens consisted of the lens epithelium, covering the anterior surface of the lens, and lens fibers, constituting the substance of the lens. The surface of the lens is encapsulated by a thin homogeneous lens capsule. Between the equatorial portion of the lens and the surface of the ciliary body, numerous thin fibers are stretched to hold the lens in position. These fibers constitute the ciliary zonule. The zonule fibers arise from the basal lamina of the ciliary epithelium. Near the ciliary crown, they fuse into the thicker fibers and finally form about 140 bundles. At the anterior margin of the ciliary processes, they leave the surface of the ciliary body and radiate toward the equator of the lens. The larger ones are straight and reach the lens capsule in front of the equator of the lens. The thinner fibers assume a slightly curved course and are attached to the lens capsule of the posterior surface of the lens. The contraction of the meridional and radial muscles of the ciliary body give tension to the ciliary zonule and that of circular fibers relax this tension.
- The left one third of this figure is the equatorial portion of the lens and the right one third is the ciliary crown, from which project three long ciliary processes. Between the surface of the ciliary body posterior to these processes and the anterior surface of the lens the zonule fibers are conspicuous, running through the posterior chamber. At about lower one third of this figure a faint line, convex toward the top, indicated by two small arrows, is recognized. This is the frontal limit of the vitreous body.

19-29 Pars ciliaris retinae. Monkey, H-E stain, x 64.




- The lower one third of this figure occupy the ciliary muscle bundles. The upper surface of this is covered by the pars ciliaris retinae, consisting of pigment epithelium and non-pigmented ciliary epithelium, which is composed of simple cuboidal or columnar cells containing deep blue stained nucleus in the pink stained cytoplasm. From their surface arise numerous zonule fibers. Beneath the pigment epithelium there is a thin layer, rich in capillary vessels, that corresponds to the lamina choriocapillaris of the chorioidea.

19-30 | Equatorial portion of lens. Monkey, H-E stain, x 50.



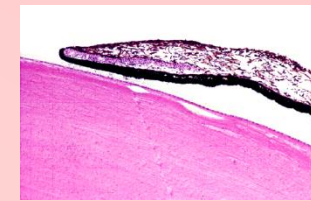
- The lens is a transparent and bi-convex body, measuring about 10 mm in diameter and about 4 mm in thickness, and situated immediately posterior to the iris..
- The lens consists of lens epithelium, which covers the anterior (frontal) surface of the lens, and lens fibers, composing the substance of the lens.
- Embryologically, the lens develops from the paired spherical lens vesicles, that are invaginations from the surface ectoderm of the head region. They are enclosed by simple cuboidal cells. These ectodermal cells are divided into two groups. The cells constituting the external (anterior) half of the lens vesicle increase in number but keep the status of simple cuboidal epithelial cells and finally form the lens epithelium. The cells of the internal (posterior) half of it, on the contrary, become long slender cells arranged in the antero-posterior direction and protrude into the lumen of the lens vesicle. They contain a nucleus at their center and are called the lens fibers. As the development progresses, the lens fibers increase in number and protrude into the lumen highly and finally attain the posterior (apical) surface of the lens epithelium, and close the lumen entirely. In the course of the further development, at the equatorial portion of the lens the epithelial cells divide actively and send new constituents to the epithelium on one side, and new lens fibers on the other.
- Toward the equator, lens epithelial cells approach a columnar form and become arranged in meridional rows. Becoming progressively elongated, the cells at the equator are transformed into lens fibers that constitute the bulk of the substance of the lens. In this transitional area, called nuclear zone, the cells have a characteristic arrangement.
- The posterior surface of the lens is constituted by lens fibers and directly invested by the lens capsule.
- This figure shows the equatorial portion of the lens where the transition of the lens epithelial cells into the lens fibers (indicated by an arrow). The lens capsule covering the lens is clearly recognized. The zonule fibers merging with the capsule are shown.

19-31 Lens and zonule fibers. Monkey, H-E stain, x 100.



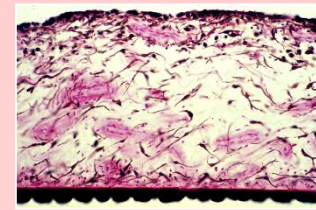
- The surface of the lens is covered by lens capsule with which merge numerous zonule fibers. Beneath the capsule the lens epithelial cells arrange in one row and the bulk of the substance of the lens consists exclusively of lens fibers.

19-32 Lens and pupillar edge of iris. Monkey, H-E stain, x 30.



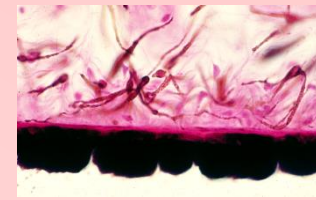
- The iris is a thin disc with a central round opening, the pupil, locating directly anterior to the lens. Near the pupil its posterior surface rests on the surface of the lens. The iris separates the anterior chamber from the posterior chamber. The periphery of the iris is connected with the ciliary body at its anterior extremity, ciliary margin.
- The iris consists of the epithelial portion, pars iridica retinae, and the stroma iridis, loose connective tissue rich in pigment cells and blood vessels. The pars iridica retinae is composed by two layers of epithelial cells: anterior, pigment epithelium, facing the stroma, and posterior, pars iridica retinae in narrow sense, facing the posterior chamber. At the pupillar edge the former turns into the latter (indicated by arrow).
- Embryologically they both originate from the double walled optic cup. The cells of the outer wall are pigmented and finally become the pigment epithelial cells. The cells of the inner wall differentiate into neurons and photosensitive cells and constitute finally the optic retina. But on the surface of the ciliary body and iris, they keep the status of the simple cuboidal epithelial cells and become finally the ciliary epithelium and pars iridica retinae, in narrow sense, respectively. The cells of the pars iridica retinae in narrow sense are filled by melanin granules and block the light ray to pass through. Thus they constitute, together with pigment epithelial cells, the light ray blocking structure.
- Around the pupillar edge, anterior to the pigment epithelium, there is a thin layer of circularly oriented smooth muscle fibers, called M. sphincter pupillae. These muscle fibers originate, embryologically, from the pigment epithelial cells
- In this figure the lens epithelium, lining the surface of the lens, and lens capsule covering the lens epithelium, are evidently recognized.

19-33 Iris, the whole thickness. Monkey, H-E stain, x 50.



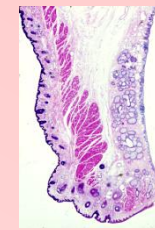
- This figure shows the whole thickness of the iris. The main mass of the iris, stroma iridis, consists of loose connective tissue, rich in melanocytes and blood vessels. The anterior surface of the stroma is lined with a thin layer of somewhat densely arranged melanocytes and fibroblasts. Within the stroma there are numerous blood vessels, whose walls consist of endothelium, pericytes and thick adventitia. The posterior surface of the iris is covered with two layers of heavily pigmented epithelium, pigment epithelium and pars iridica retinae in narrow sense.
- The anterior surface of the pigment epithelium is covered by an evident red line. This is the M. dilatator pupillae. See the next figure, 19-34 !

19-34 Posterior portion of iris. Monkey, H-E stain, x 160.



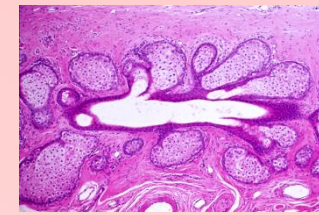
- The lower portion of this figure consists of two layers of heavily pigmented epithelial cells: the lower is the pars iridica retinae in narrow sense (a), and the upper, pigment epithelium (b and c). The lower half of the pigment epithelial cells (b) is heavily pigmented but the upper (basal) half of them becomes smooth muscle fibers (c) which radiate from the pupil to the periphery. These smooth muscle fibers constitute the M. dilatator pupillae.
- The upper to these muscles follows the stroma iridis, consisting of very loose connective tissue rich in pigment cells.

19-35 Eyelid, sagittal section. Human, H-E stain, x 4.0.



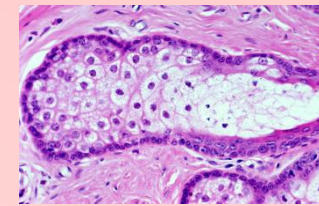
- The eyelids are the folds of the skin, overlying the eyeball from top and down. The outer surface of lids is covered by a stratified squamous epithelium with keratinization,
- and the posterior surface, by a stratified columnar epithelium of the conjunctiva palpebrae, which is reflected at the upper and lower fornices onto the eyeball as the conjunctiva bulbi. The space between the palpebrae and eyeball, lined by conjunctiva and corneal epithelium, is called conjunctival sac, which is always moistened by tear.
- The skin is provided with sweat glands, numerous fine hairs, downy hairs, and associated sebaceous glands. In the depth of the tela subcutanea there is a conspicuous layer of the circularly oriented skeletal muscle fiber bundles, M. orbicularis palpebrae. Posteriorly, near the conjunctiva, there is a plate of the fibrous cartilage, the tarsus, in which numerous glands, tarsal glands, are embedded. At the margin of the lids, where the transition from the skin to the conjunctiva takes place, there are three or four rows of large hairs, eyelashes. Their follicles penetrate deeply into the underlying connective tissue and between them there are small apocrine sweat glands, the glands of Moll. Posterior to the follicles of the eyelashes there is a small group of the circularly oriented skeletal muscle, called ciliary muscle. The space between the M. orbicularis palpebrae and the tarsus is filled by very loose connective tissue, containing no fat cells.

19-36 Tarsal glands. Human, H-E stain, x 10.



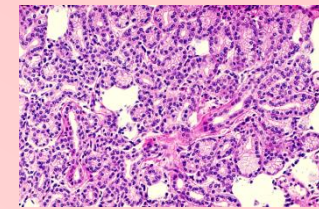
- The tarsal glands, glands of Meibom, are sebaceous glands, embedded in the substance of the tarsus. They are about 25 in the upper lid and about 20 in the lower. They are arranged parallel to one another and perpendicular to the margin of the lid. Each of them has a thick central duct, penetrating the axial portion of the tarsus and opening at the margin of the lid. Into the duct open numerous lobes, as the bunch of grapes.

19-37 A lobe of tarsal gland. Human, H-E stain, x 100.



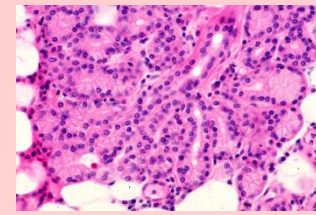
- Higher magnification of a lobe of the tarsal gland. The processes of the holocrine secretion are typically observed. The cells lining the periphery of the lobe are low cuboidal and have basophilic cytoplasm; from the cells adjacent to them contain numerous fat droplets and the cells locating at the axial portion of the lobe are filled by fat and become secretion droplet.

19-38 Lacrimal gland, 1. Human, H-E stain, x 64.



- The lacrimal gland secretes the tear and through this moistens the conjunctival sac,
- especially the surface of the cornea. It is a flat oval in shape, about 1.5 cm long, 1.0 cm wide and 2 mm thick, and lodged beneath the conjunctiva at the upper lateral side of the eyeball. Its 6 to 12 excretory ducts open along the upper and lateral quadrant of the superior conjunctival fornix.
- The lacrimal gland is a tubuloalveolar gland with a relatively wide lumen and the cells surrounding it have light basophilic cytoplasm and basally located round nucleus. They resemble those of the serous salivary glands. But different from the parotid gland, the lacrimal gland has neither striated ducts nor intercalated ducts and the lumen of the secretory portions drains directly into the excretory duct.
- In this figure the direct continuity of the secretory portion with the duct is observed (arrow).

19-39 Lacrimal gland, 2. Human, H-E stain, x 100.



- Another specimen of the lacrimal gland. This figure is filled by the secretory portions with relatively wide lumen. The cells enclosing the lumen are tall cuboidal and stain light basophilic. Their nuclei are round and locate basally. At the center of this figure several secretory portions drain directly into a duct (arrow).