10-00
Digestive System
2
Esophagus & Stomach

10 Digestive System 2
Menu

10-001
Esophagus

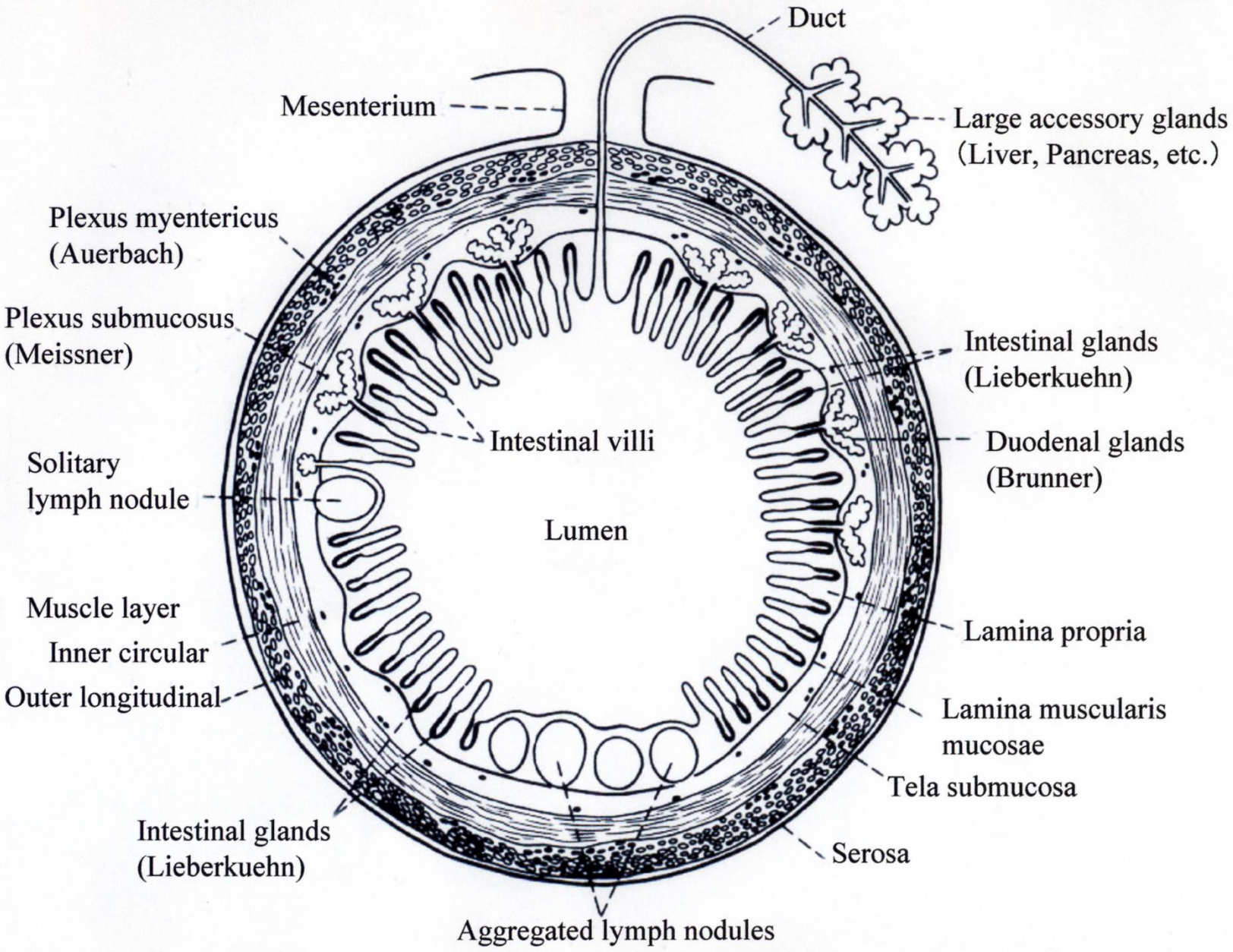

10-01 General structure of the digestive system (Scheme)

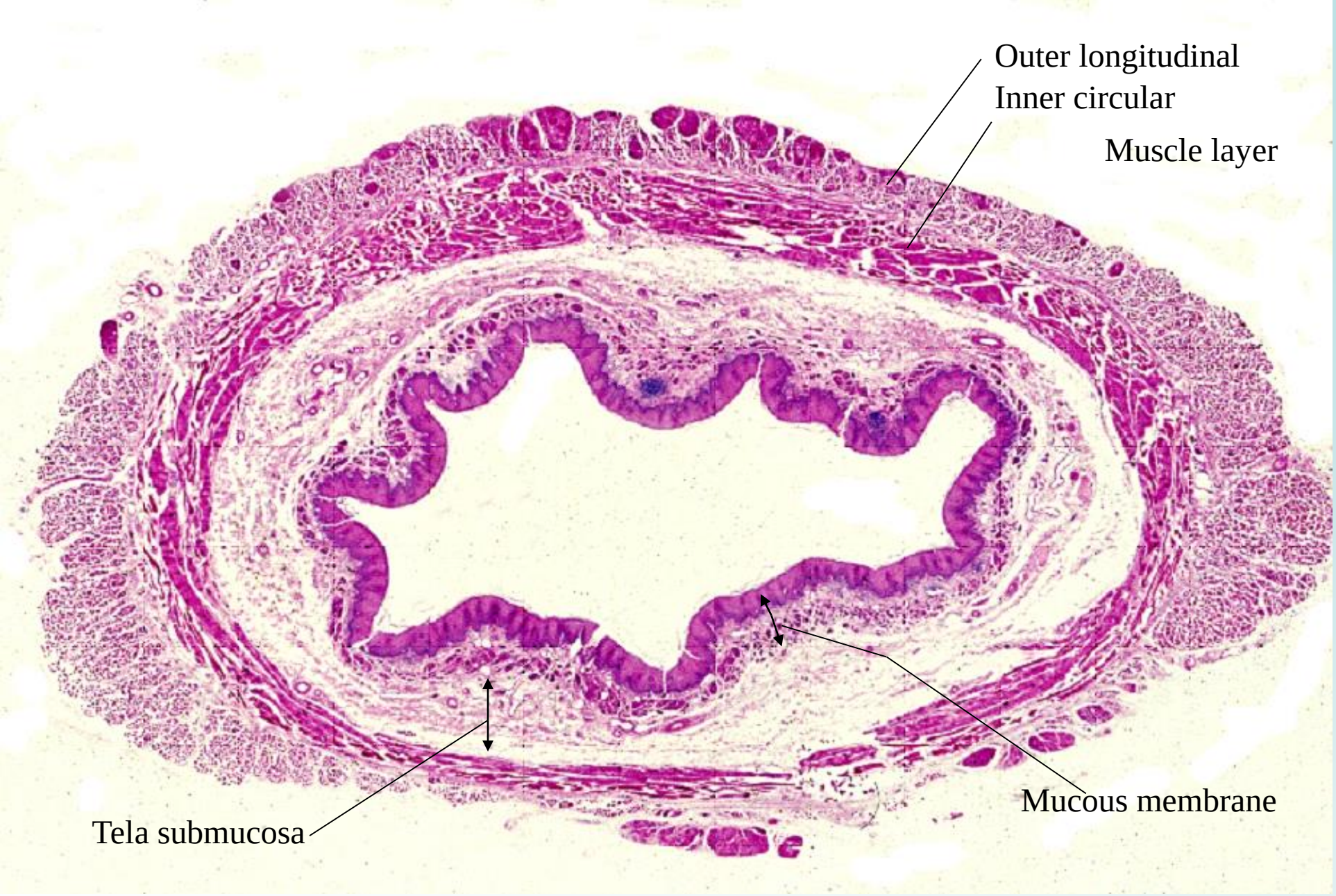

10-02 Esophagus, transverse section. Human, H-E stain, x 1.9.

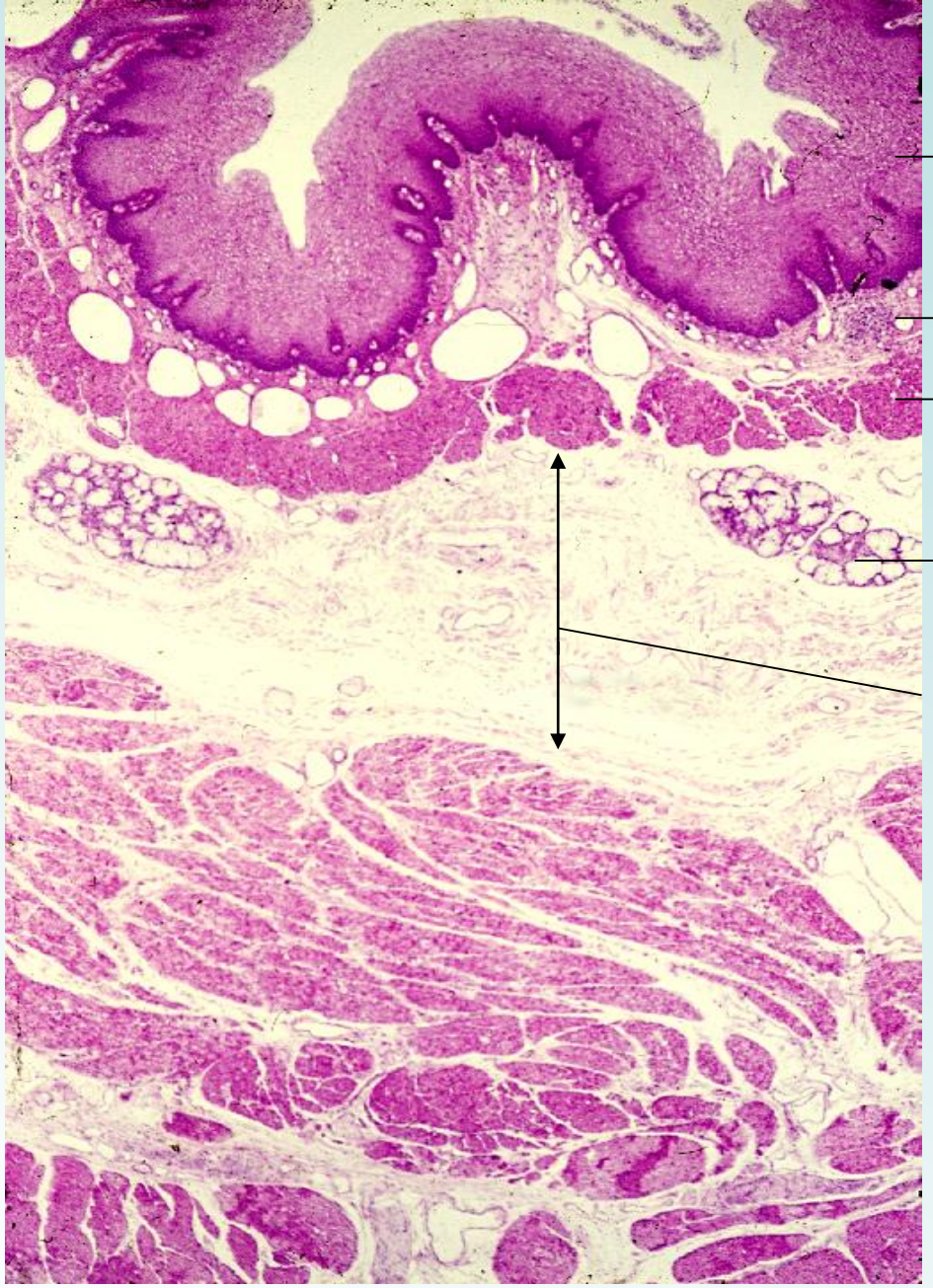

10-03 Esophagus, transverse section. Human, H-E stain, x 10.

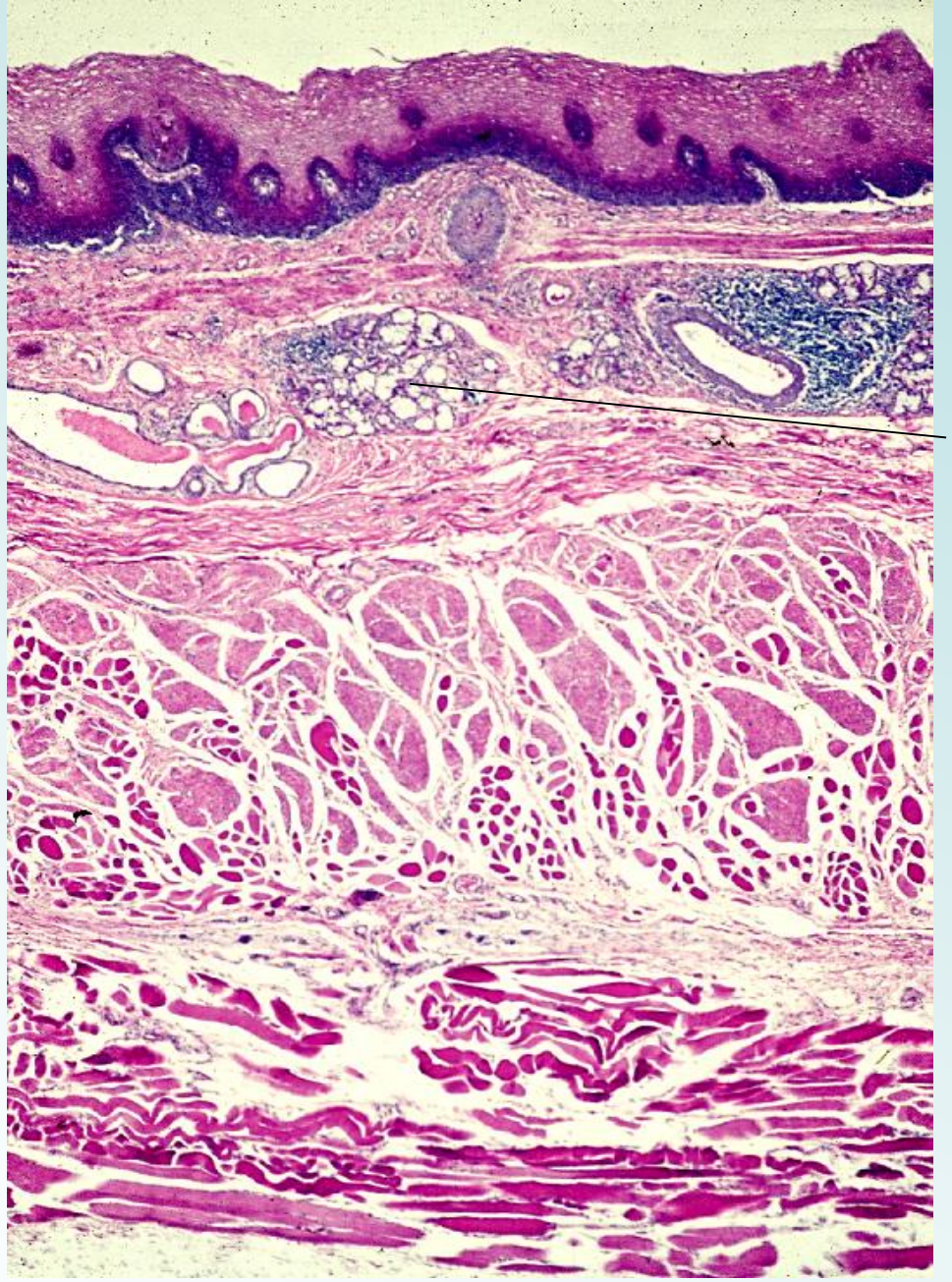

10-04 Esophagus, longitudinal section. Human, H-E stain, x 10.

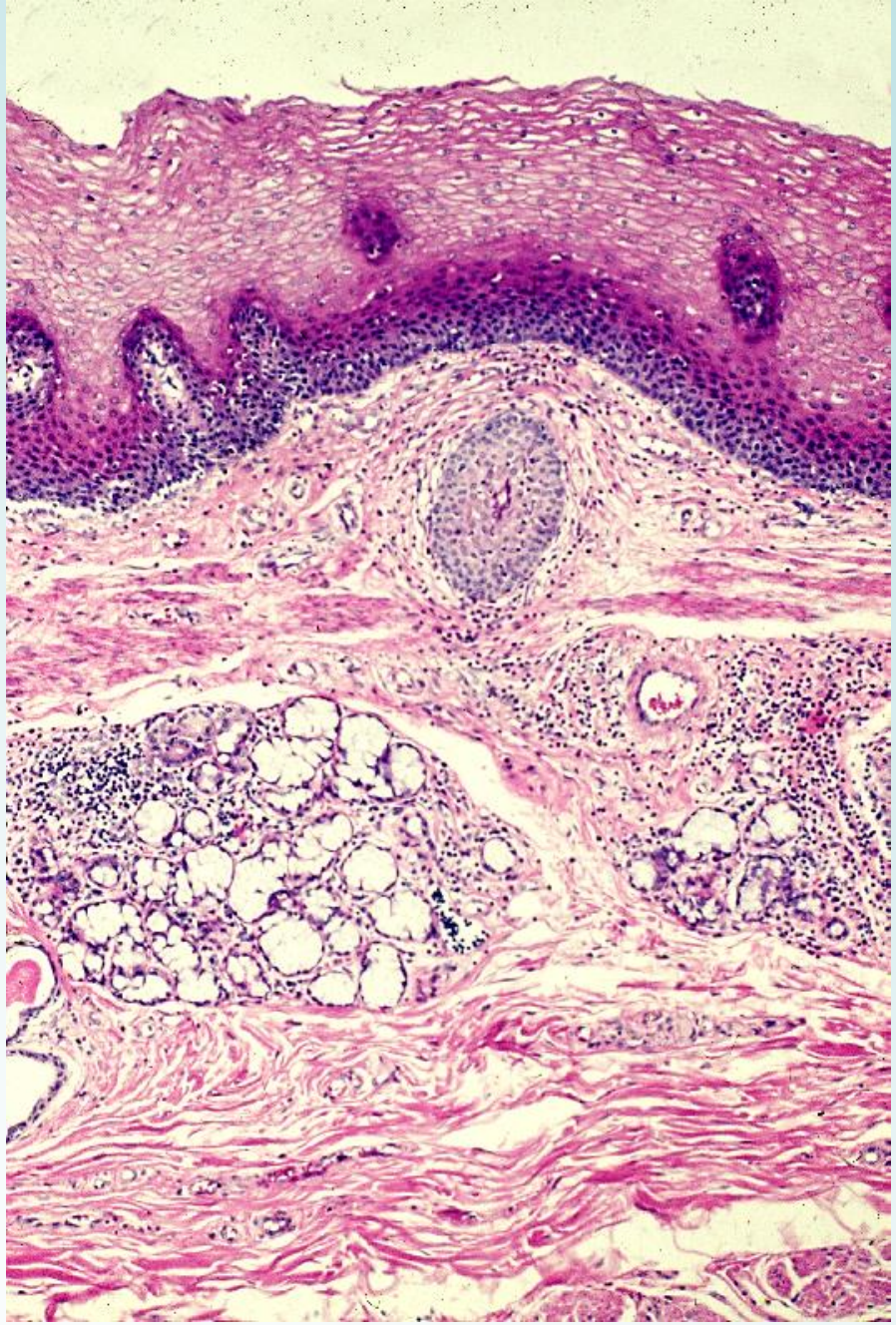

10-05 Esophagus, longitudinal section. Human, H-E stain, x 25.

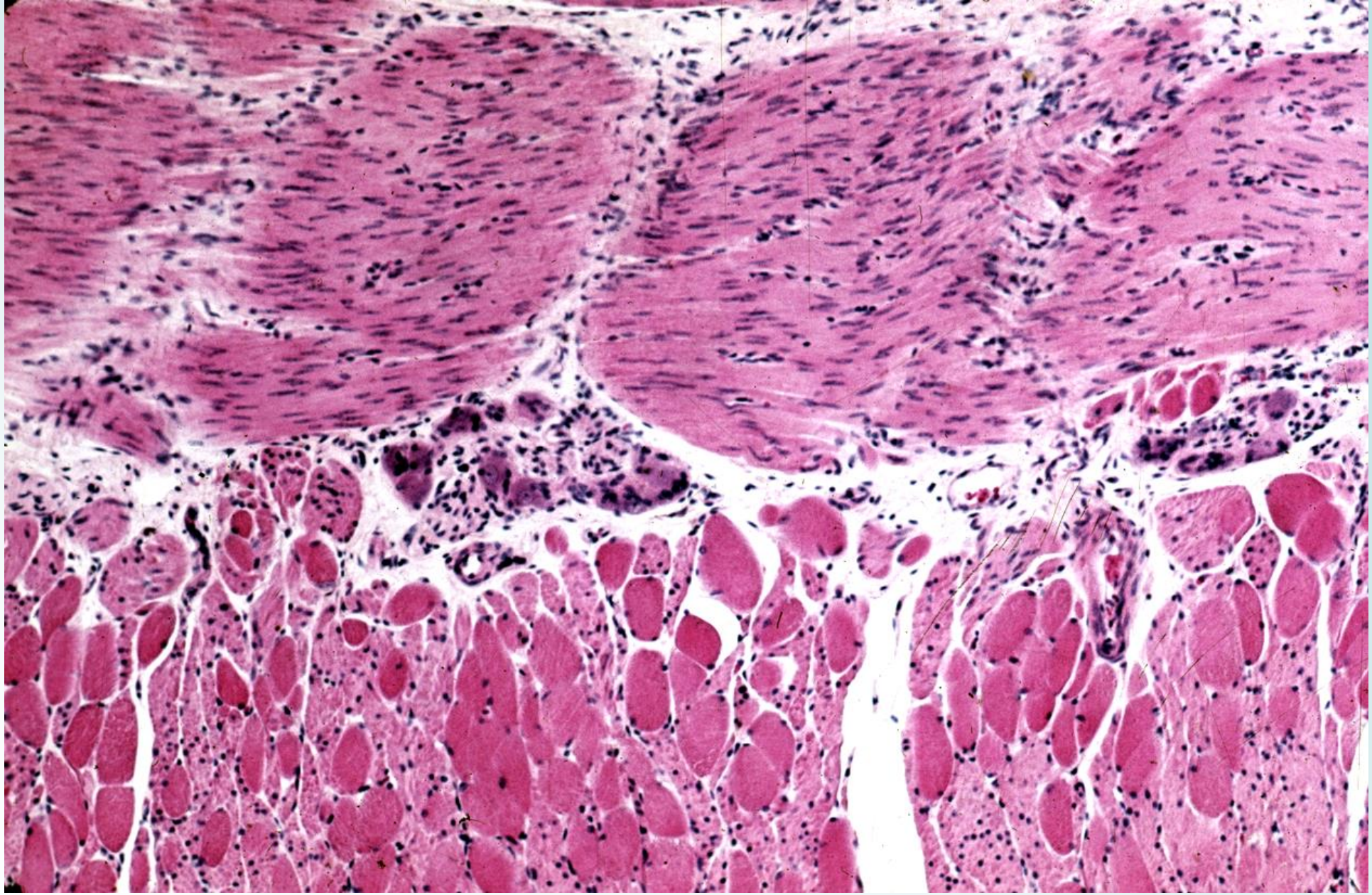

10-06 Auerbach's plexus, 1. Monkey, H-E stain, x 30.

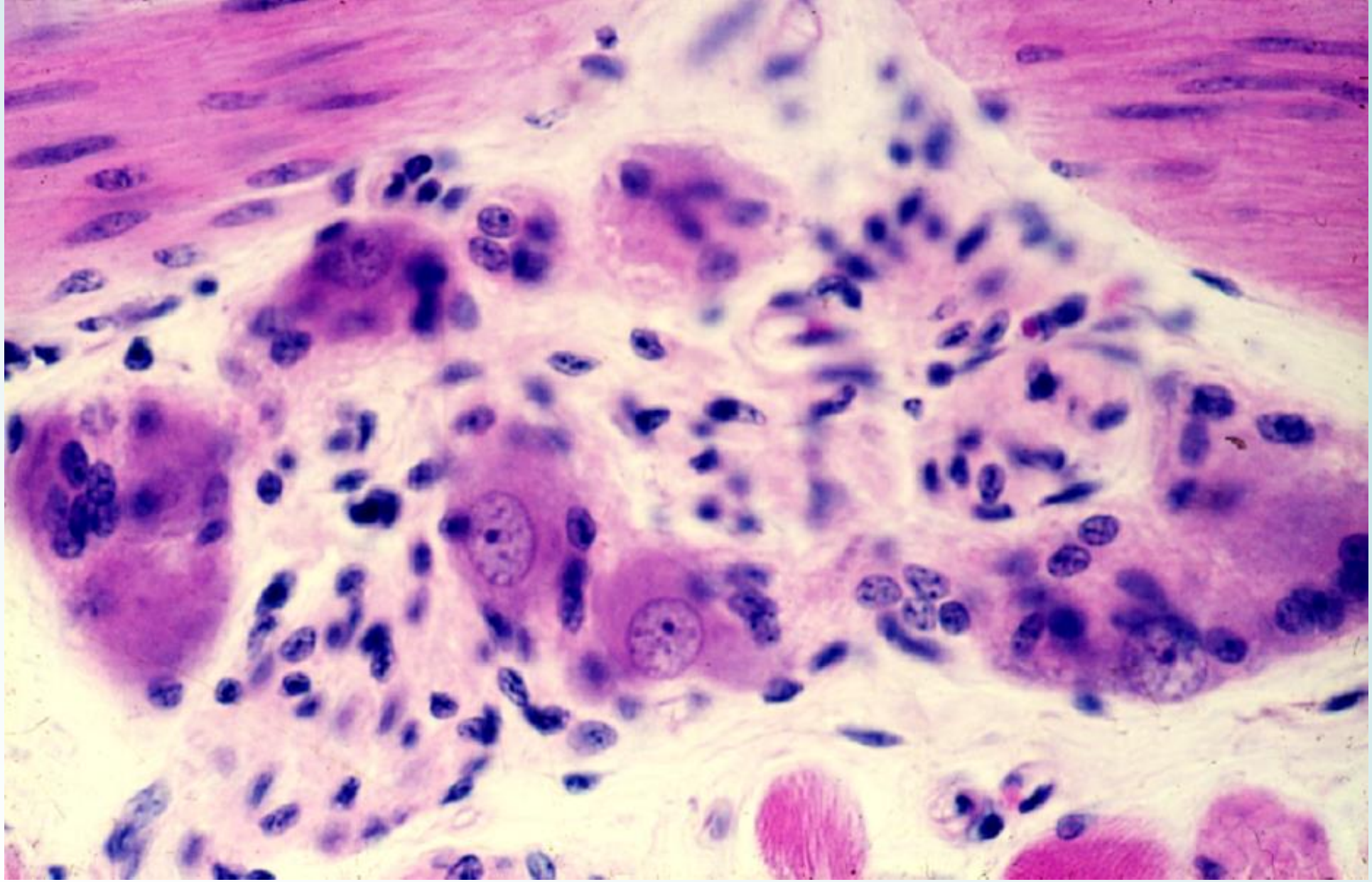

10-07 Auerbach's plexus, 2. Monkey, H-E stain, x 160.

10-002
Stomach

10-08 Cardia, 1. General view. Monkey, H-E stain, x 3.

10-09 Cardia, 2. Esophagogastric junction. Monkey, H-E stain, x 10.

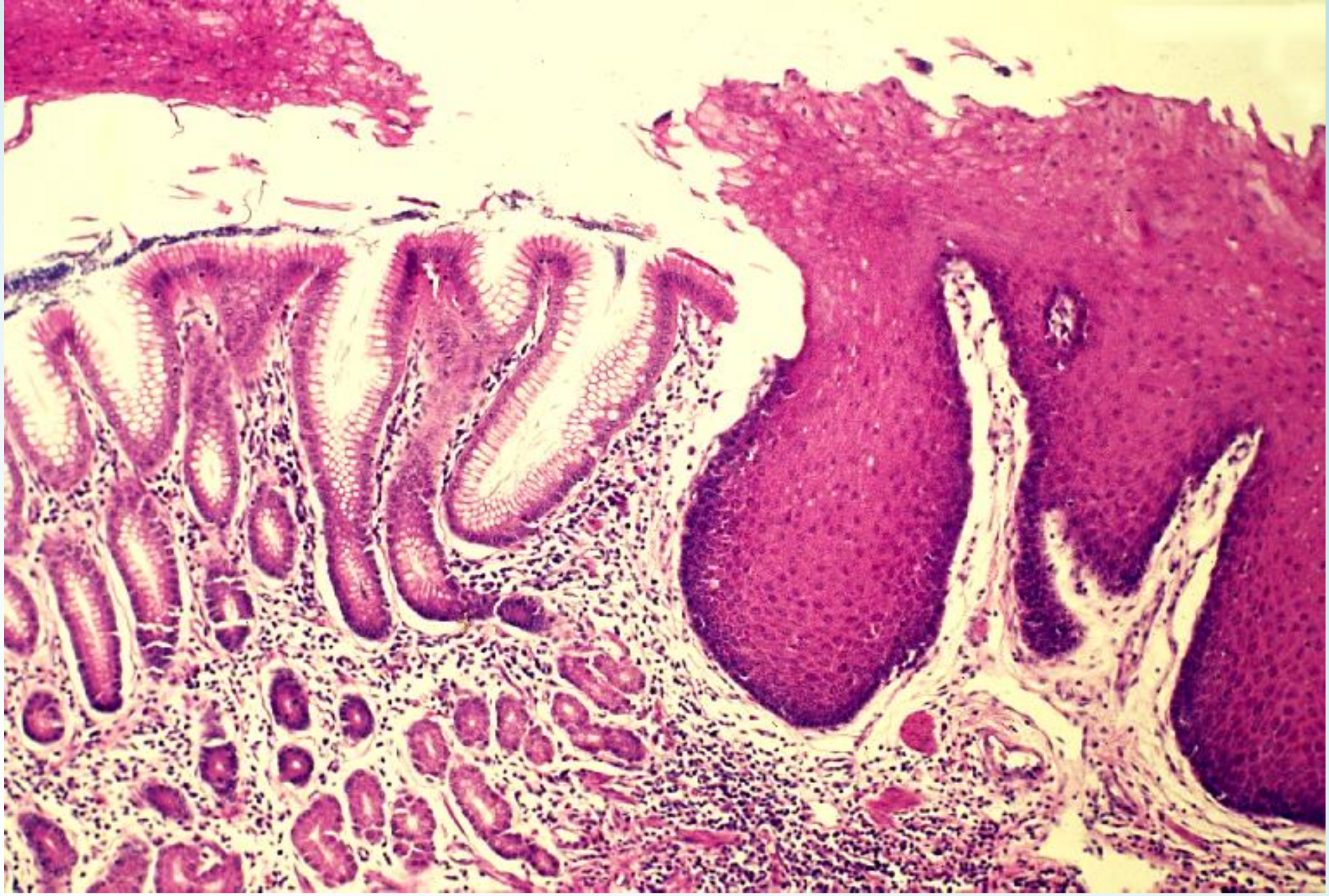

10-10 Cardia, 3. Abrupt transition of epithelium. Monkey, H-E stain, x 25.

10-11 Cardiac glands. Monkey, H-E stain, x 65.

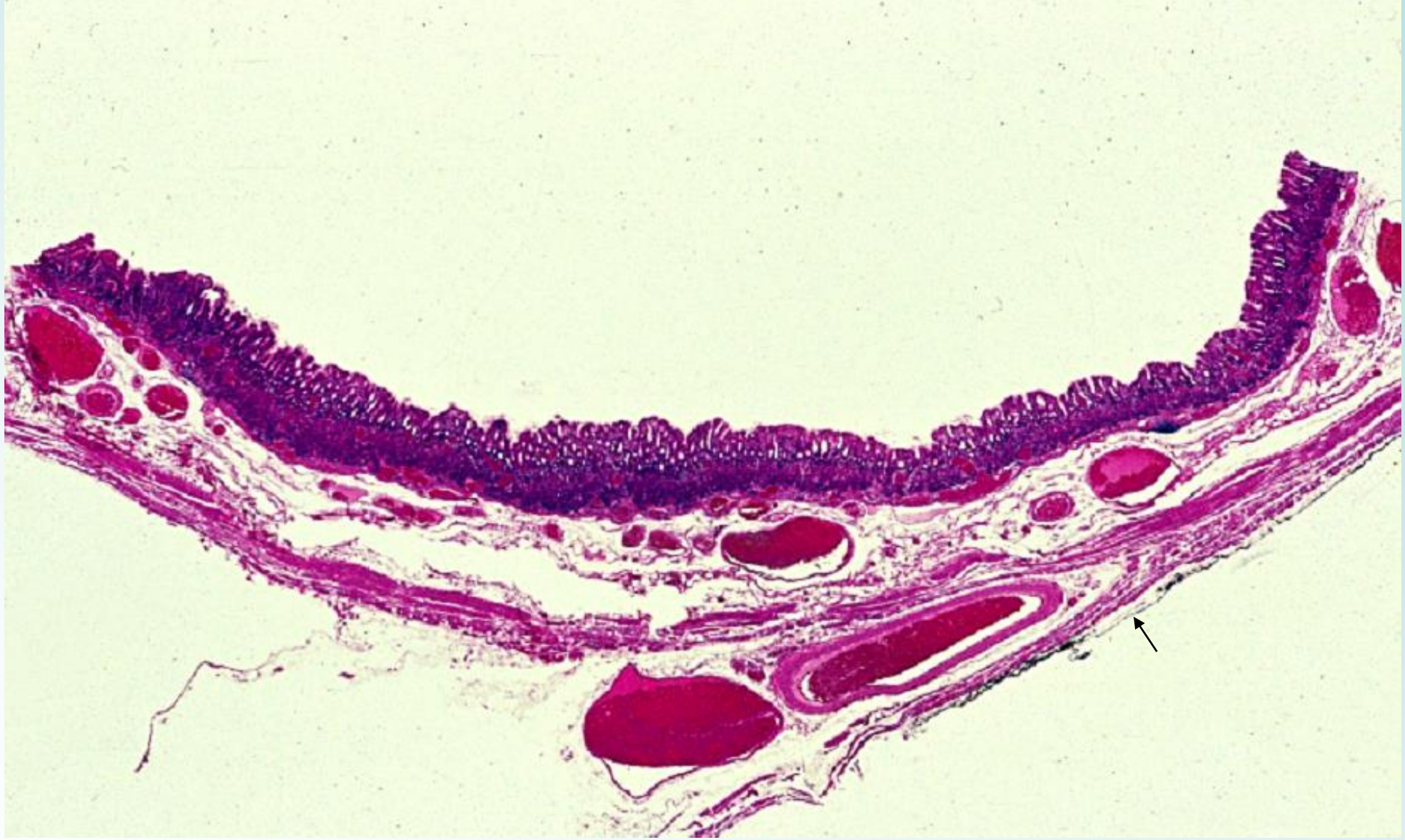

10-12 Wall of the stomach body. Human, H-E stain, x 2.7.

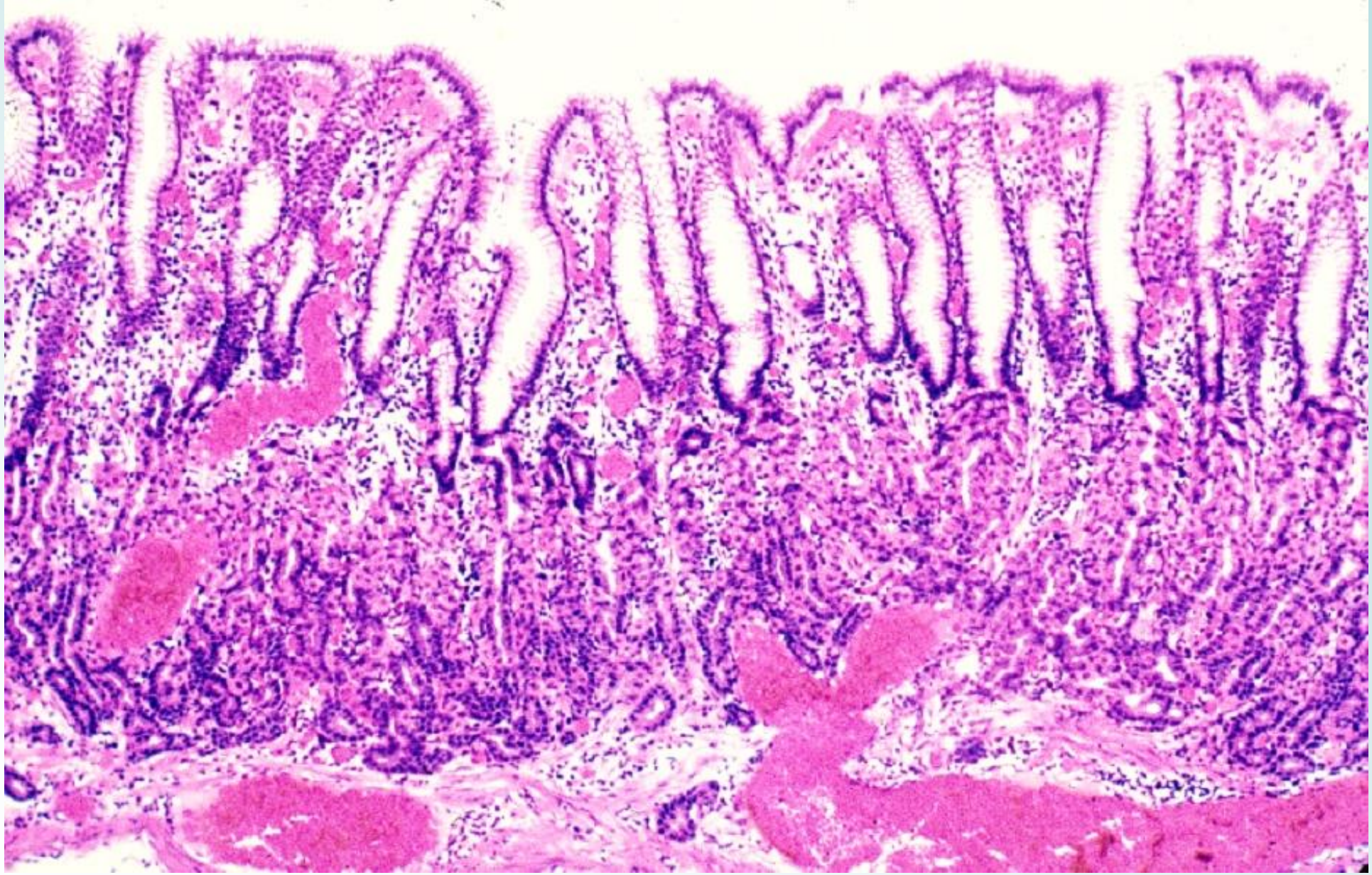

10-13 Mucous membrane of the stomach body, 1. Human, H-E stain, x 25.

10-14 Mucous membrane of the gastric body, 2. Human, H-E stain, x 30.

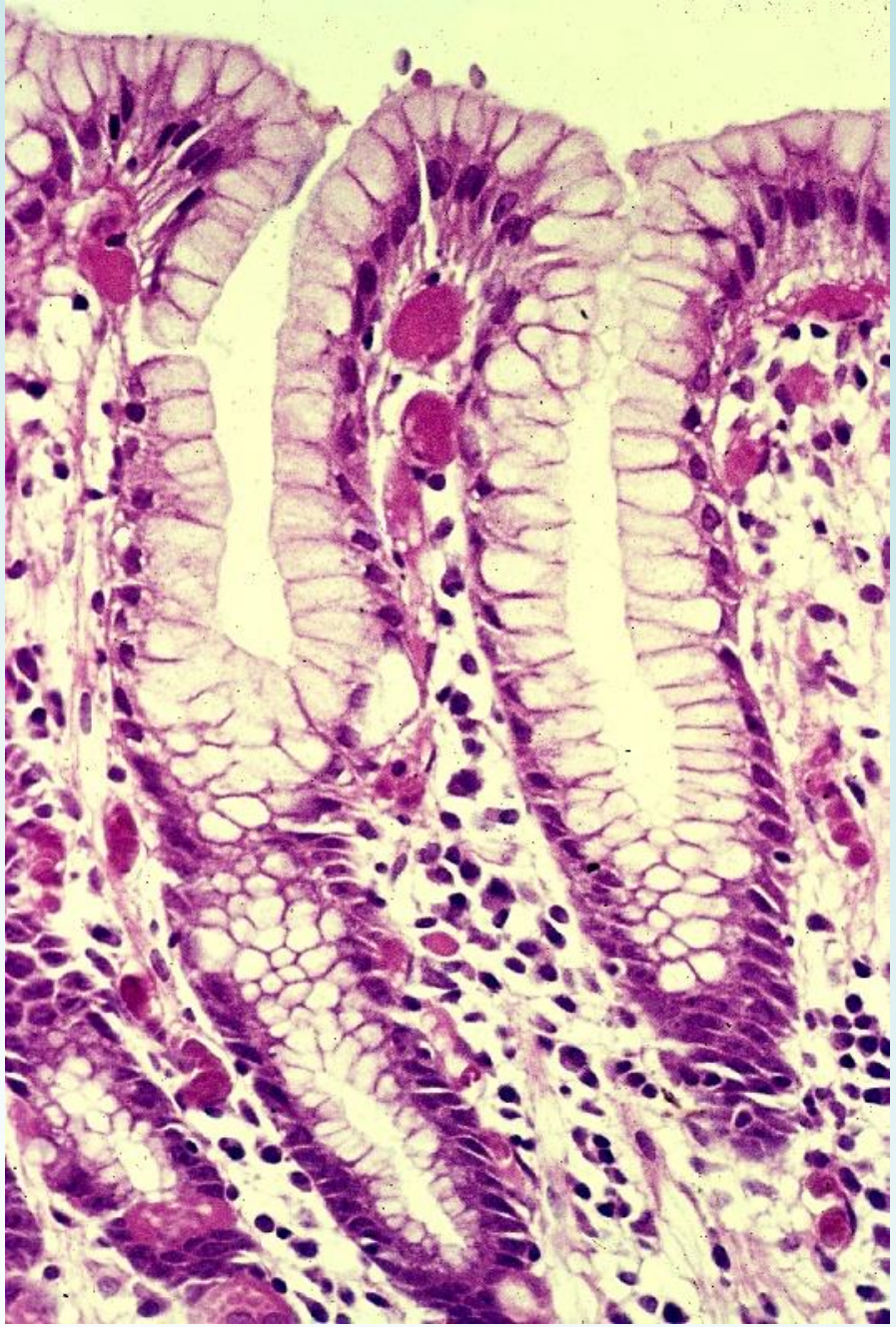

10-15 Surface epithelium and gastric pits, 1. Human, H-E stain, x 100.

10-16 Surface epithelium and gastric pits, 2. Human, H-E stain, x 130.

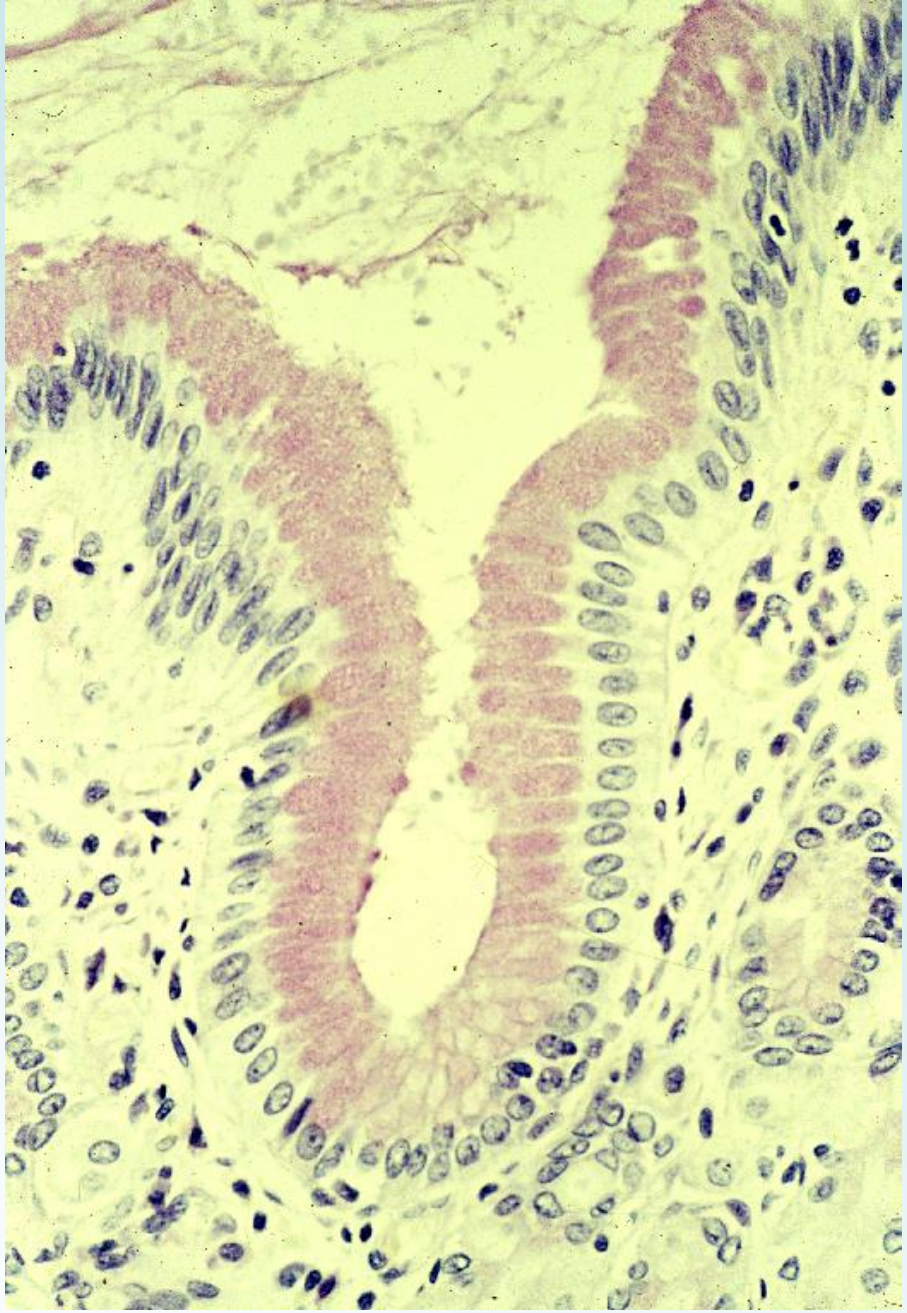

10-17 Gastric epithelium. Human, mucicarmin and hematoxylin stain, x 100.

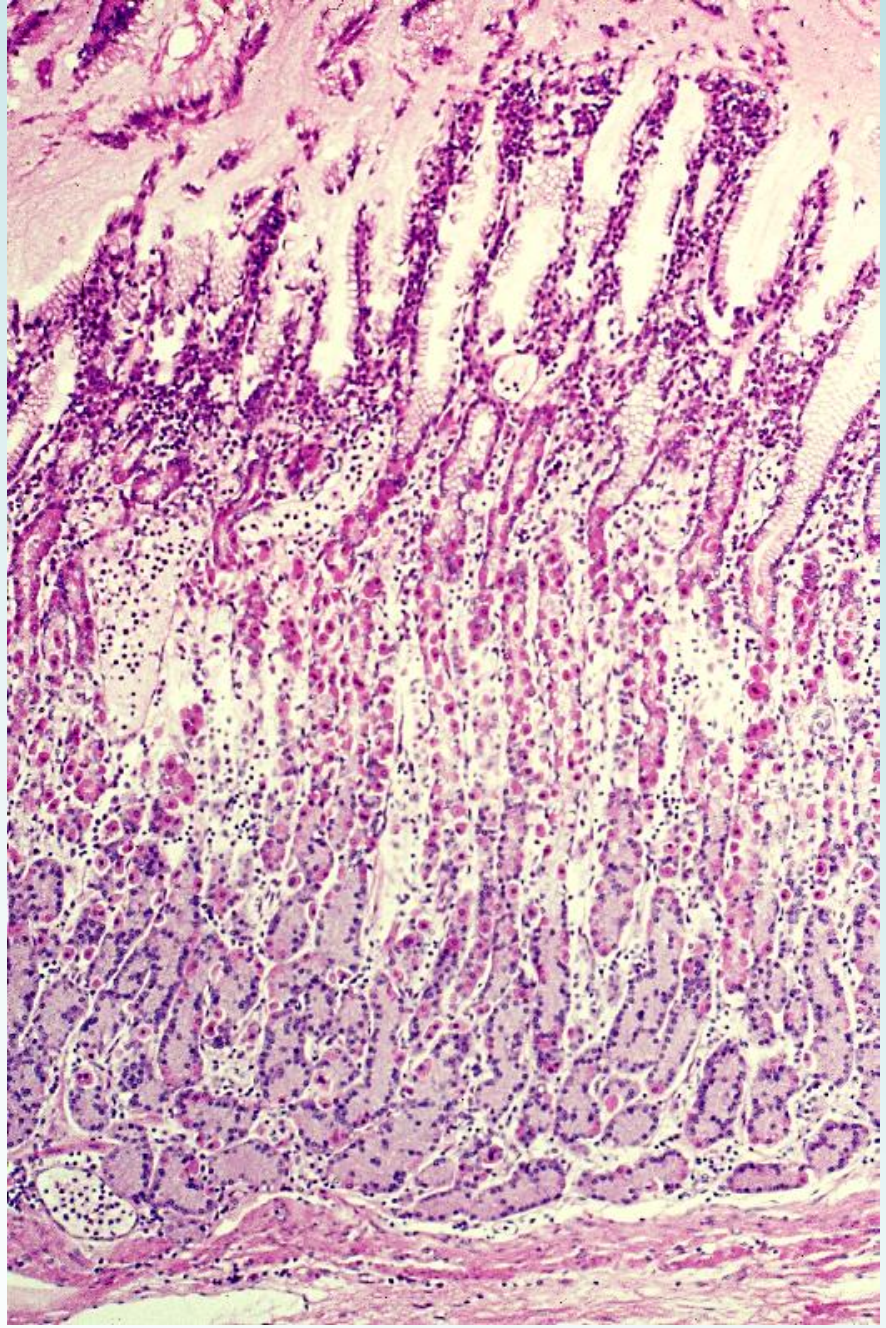

10-18 Mucous membrane of stomach body, showing the hole length of the fundus glands. Human, H-E stain, x 25.

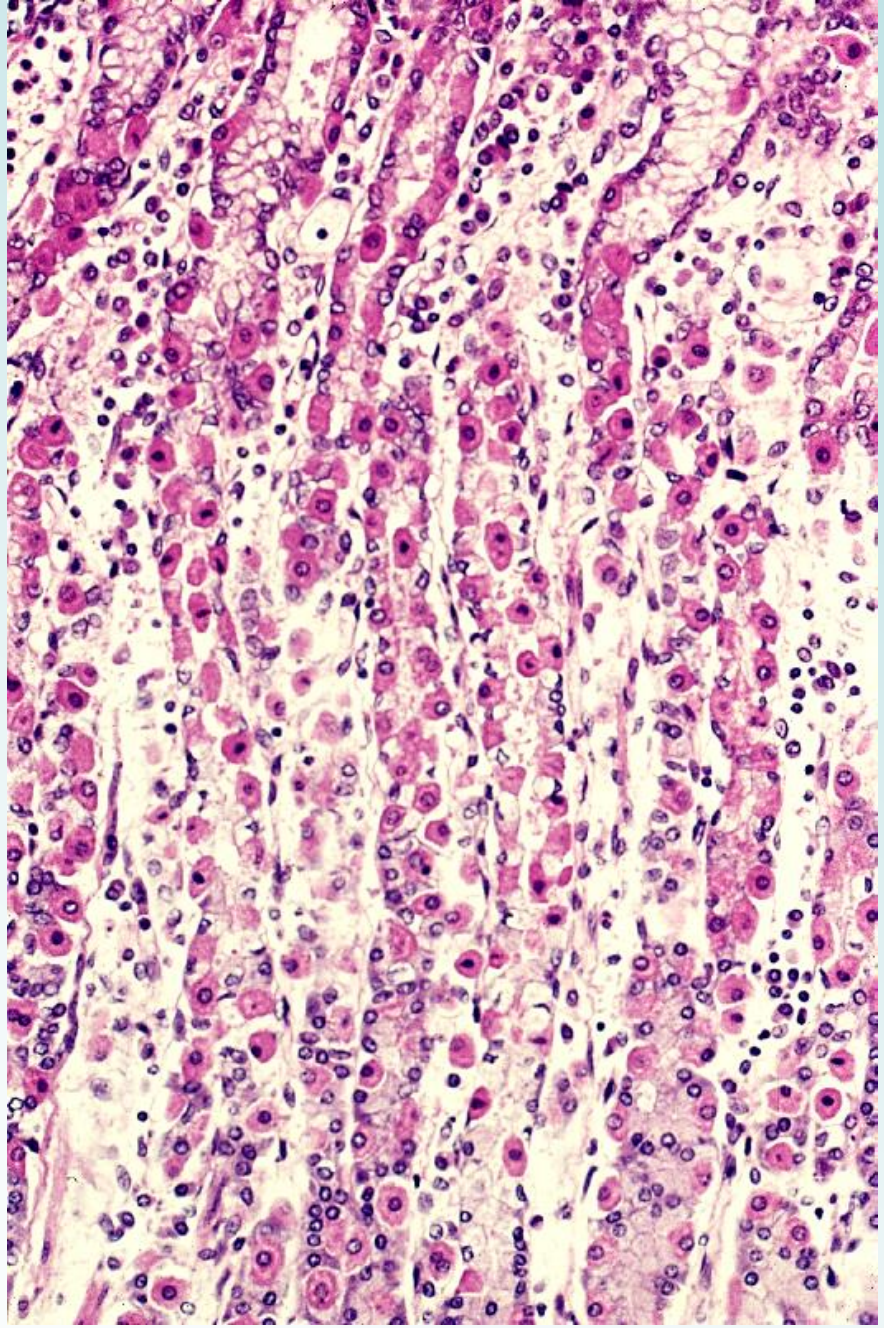

10-19 Fundus glands, neck 1. Human, H-E stain, x 64.

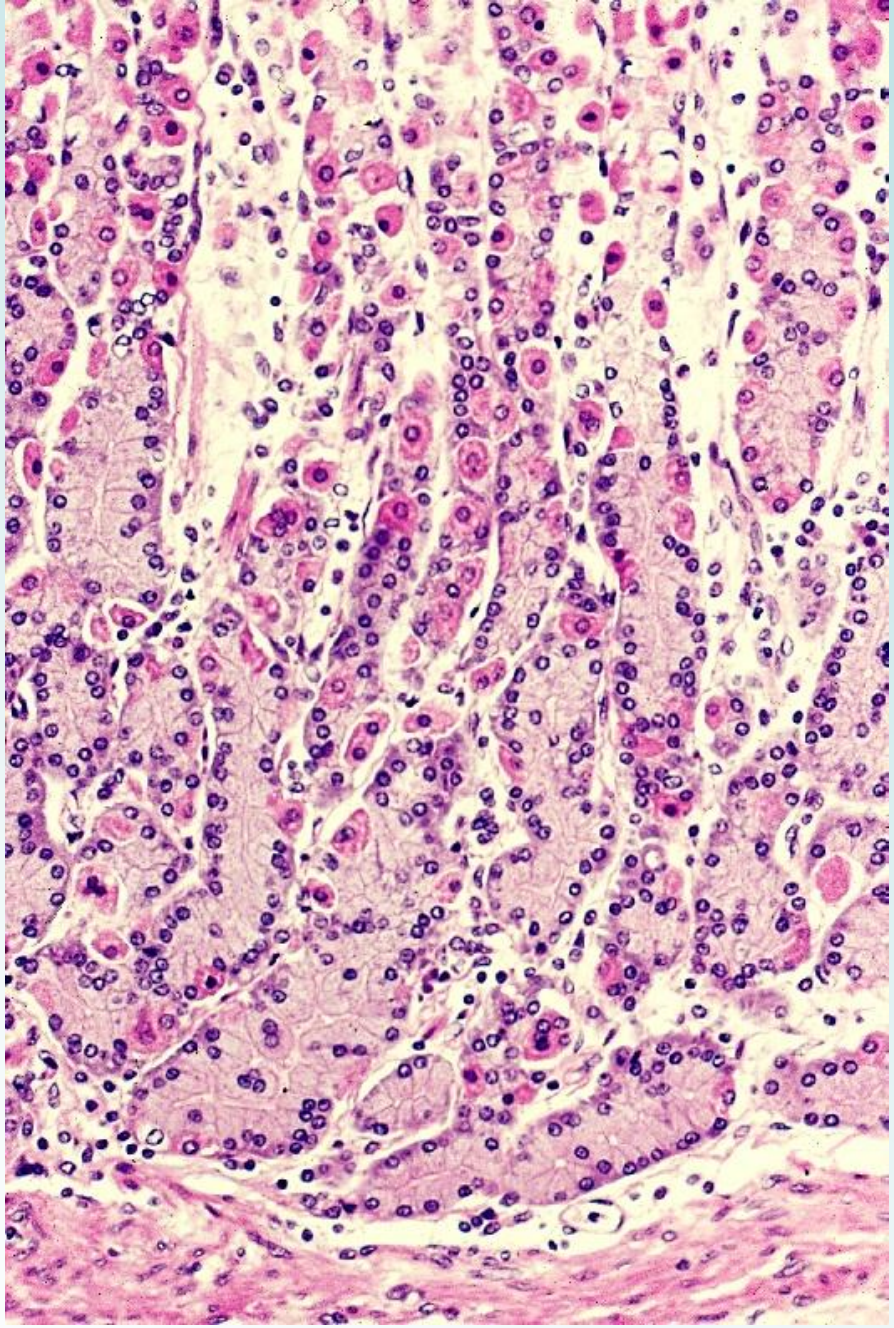

10-20 Fundus glands, bottom 1. Human, H-E stain, x 64.

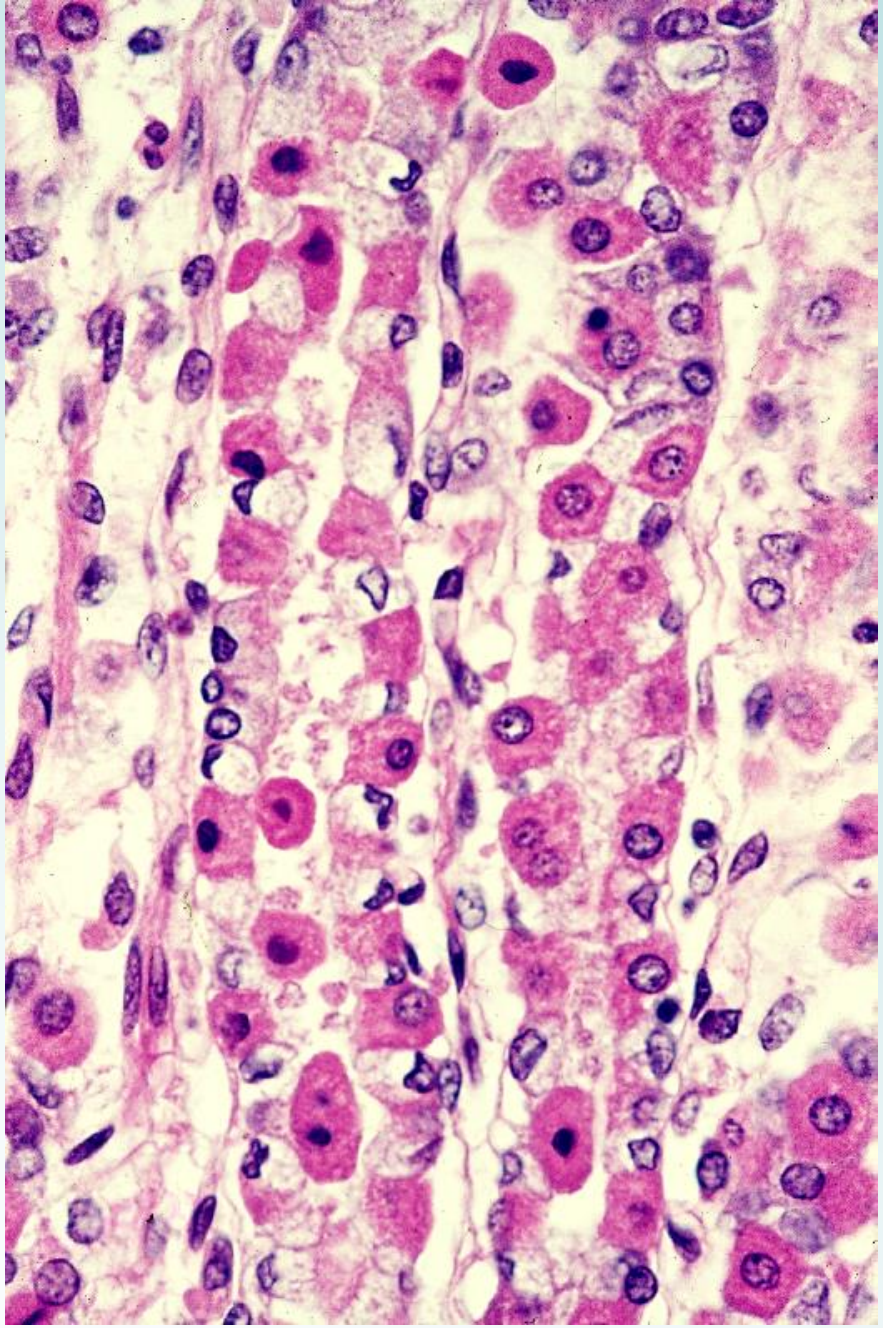

10-21 Fundus glands, neck 1. Human, H-E stain, x160.

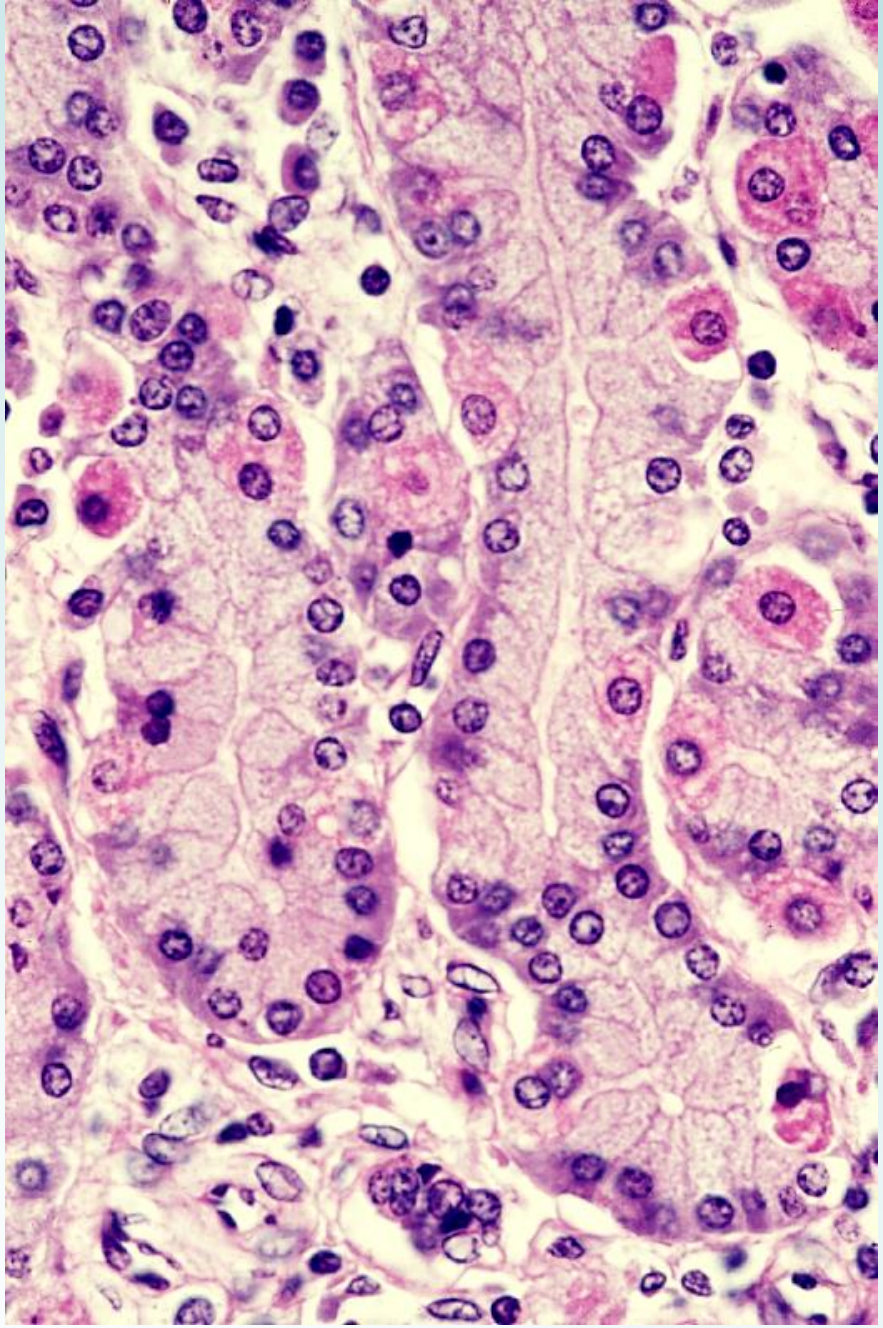

10-22 Fundus glands, bottom 2. Human, H-E stain, x 160.

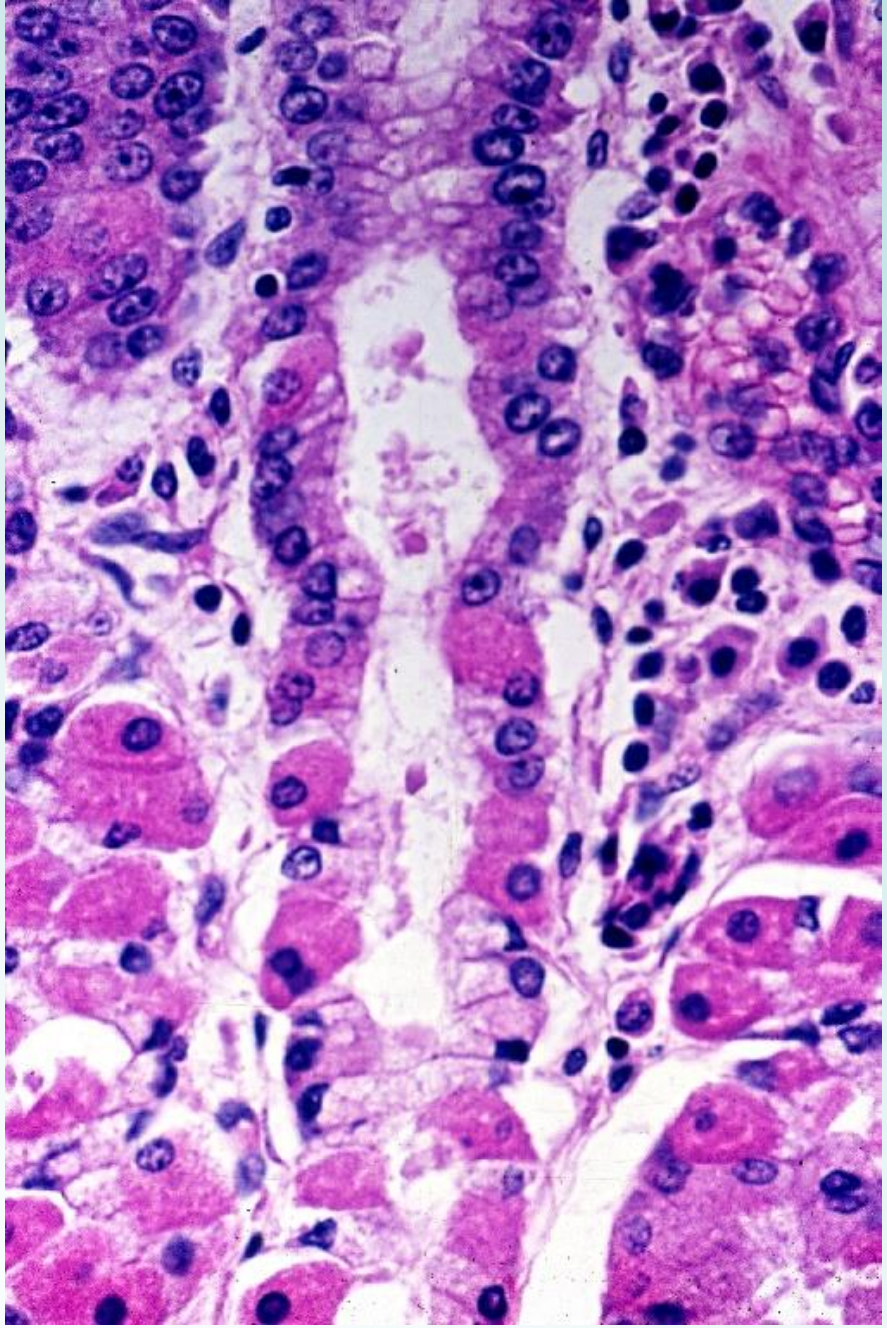

10-23 Fundus glands, neck 3. H-E stain, x 160.

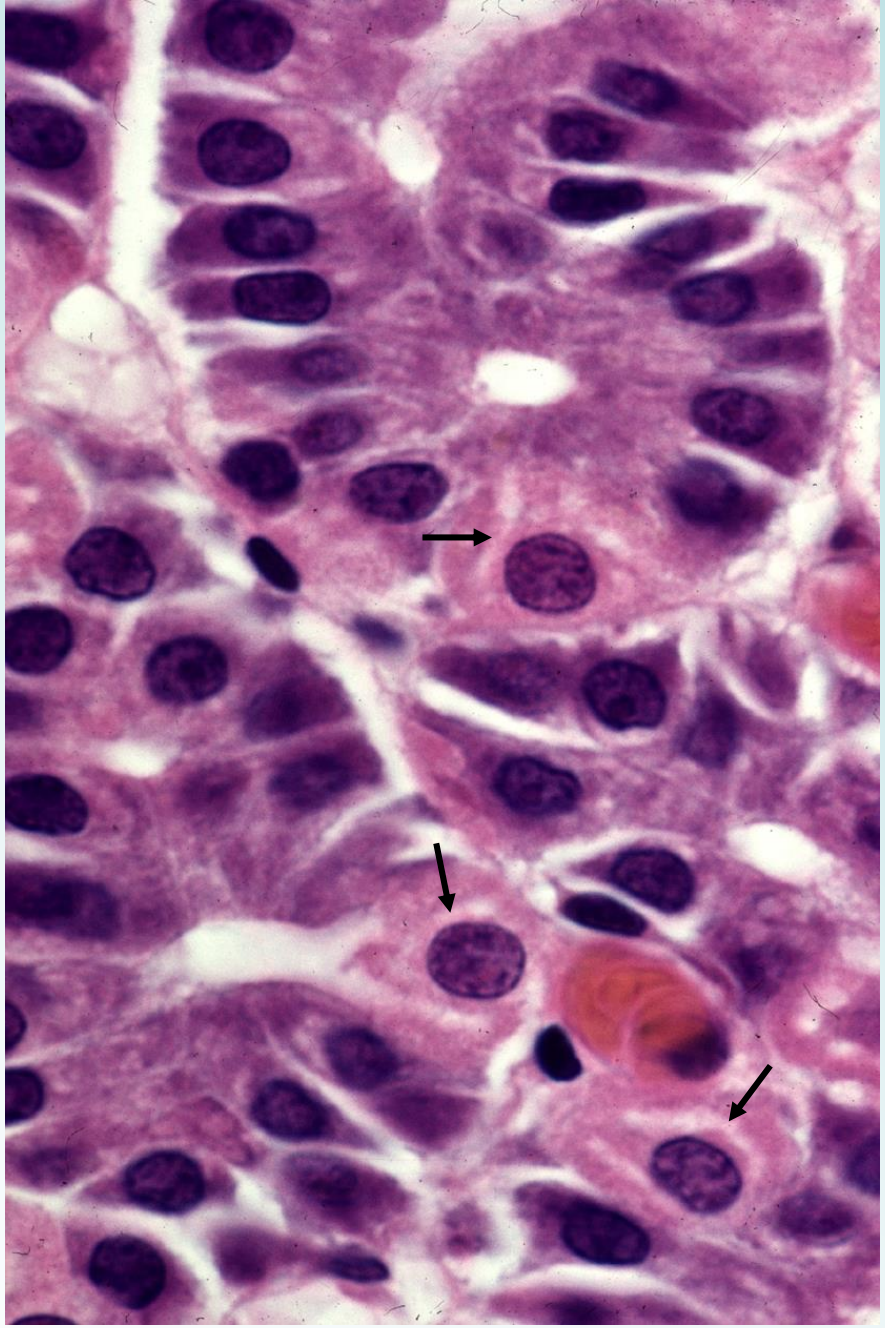

10-24 Fundus glands, bottom 3. H-E stain x 400.

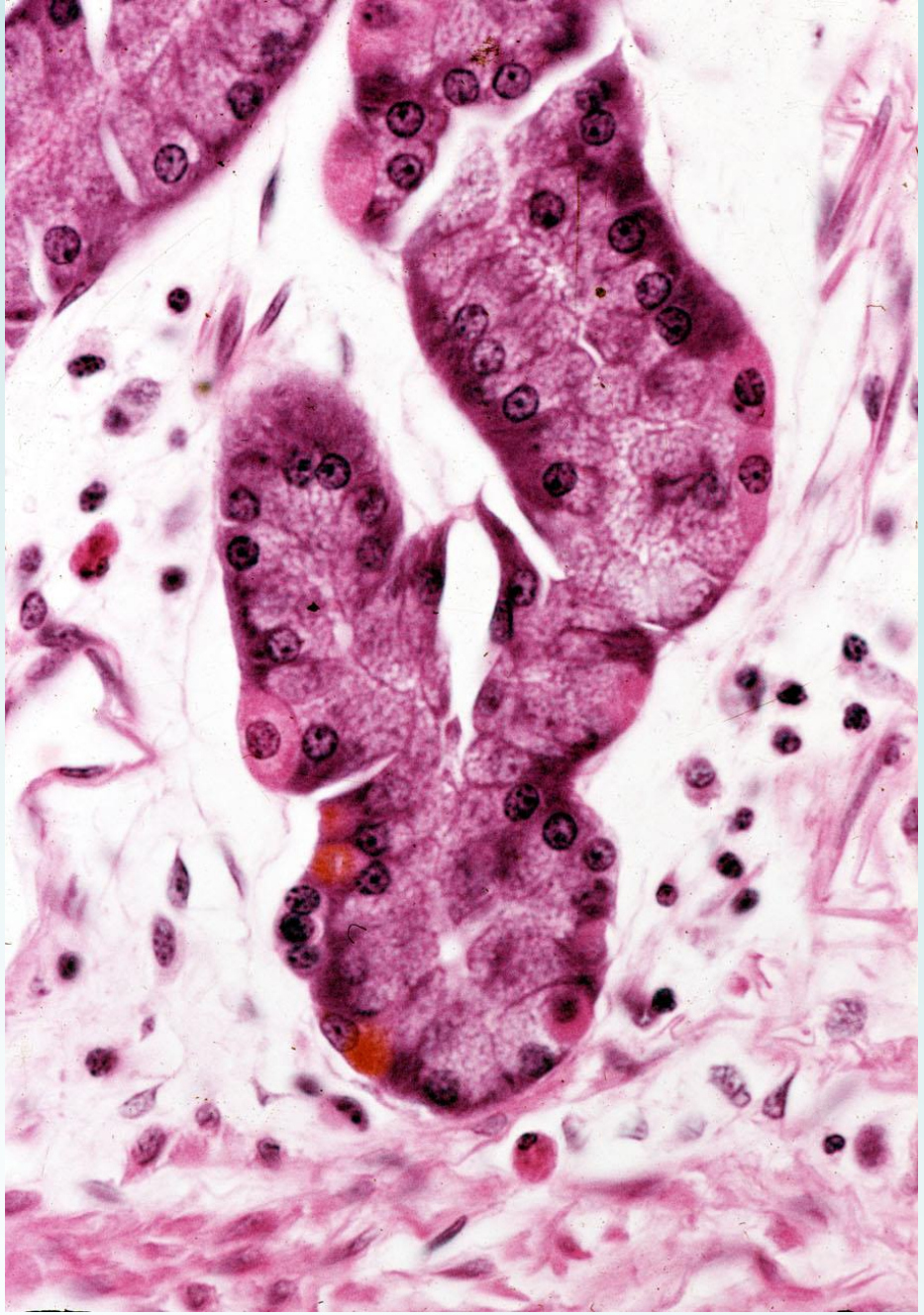

10-25 Fundus glands, bottom 4. Monkey, H-E stain, x 160.

10-26 Fundus gland, bottom 5. Monkey, H-E stain, x 400.

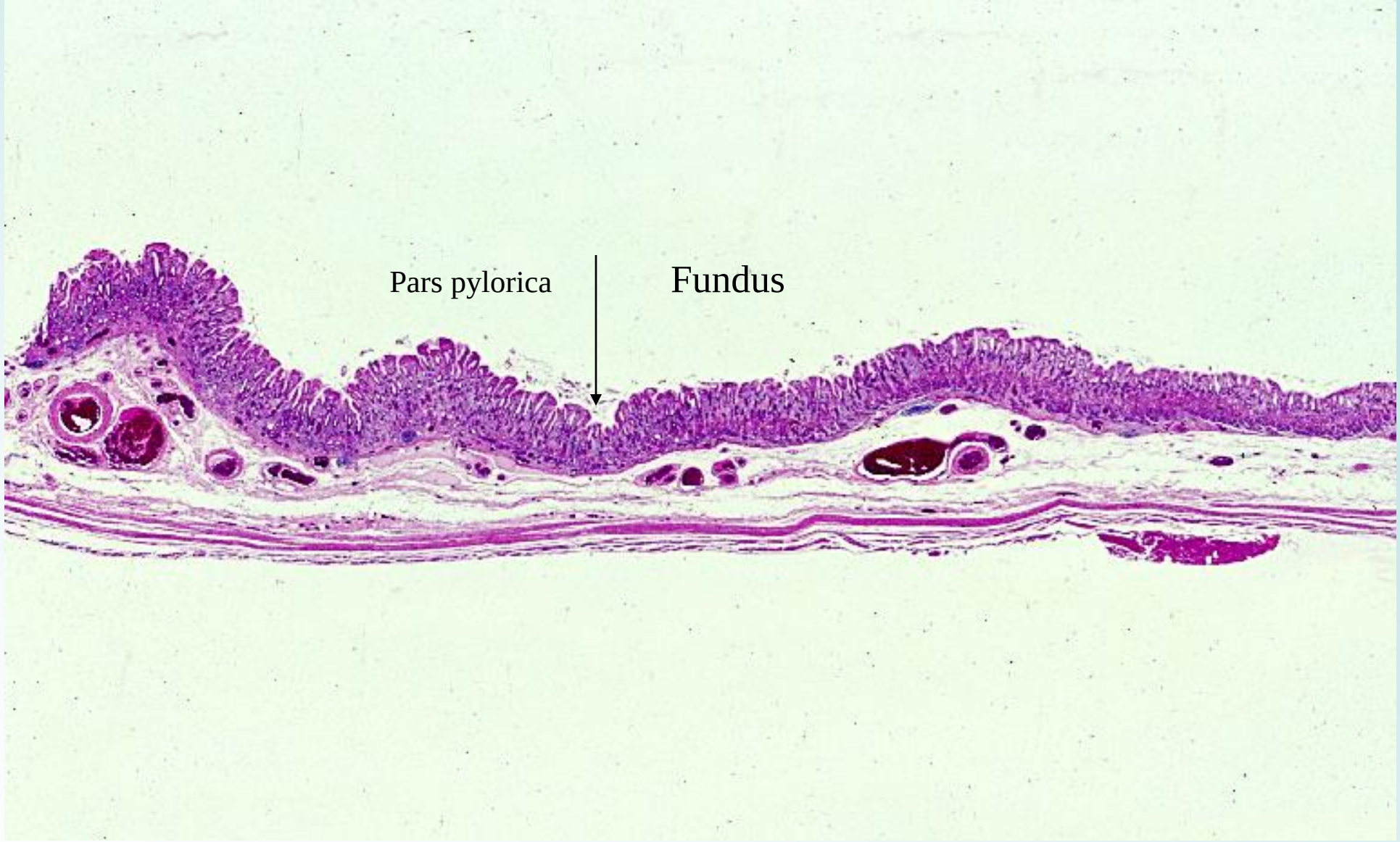

10-27 Wall of the pyloric region, general view. Human, H-E stain, x 2.0.

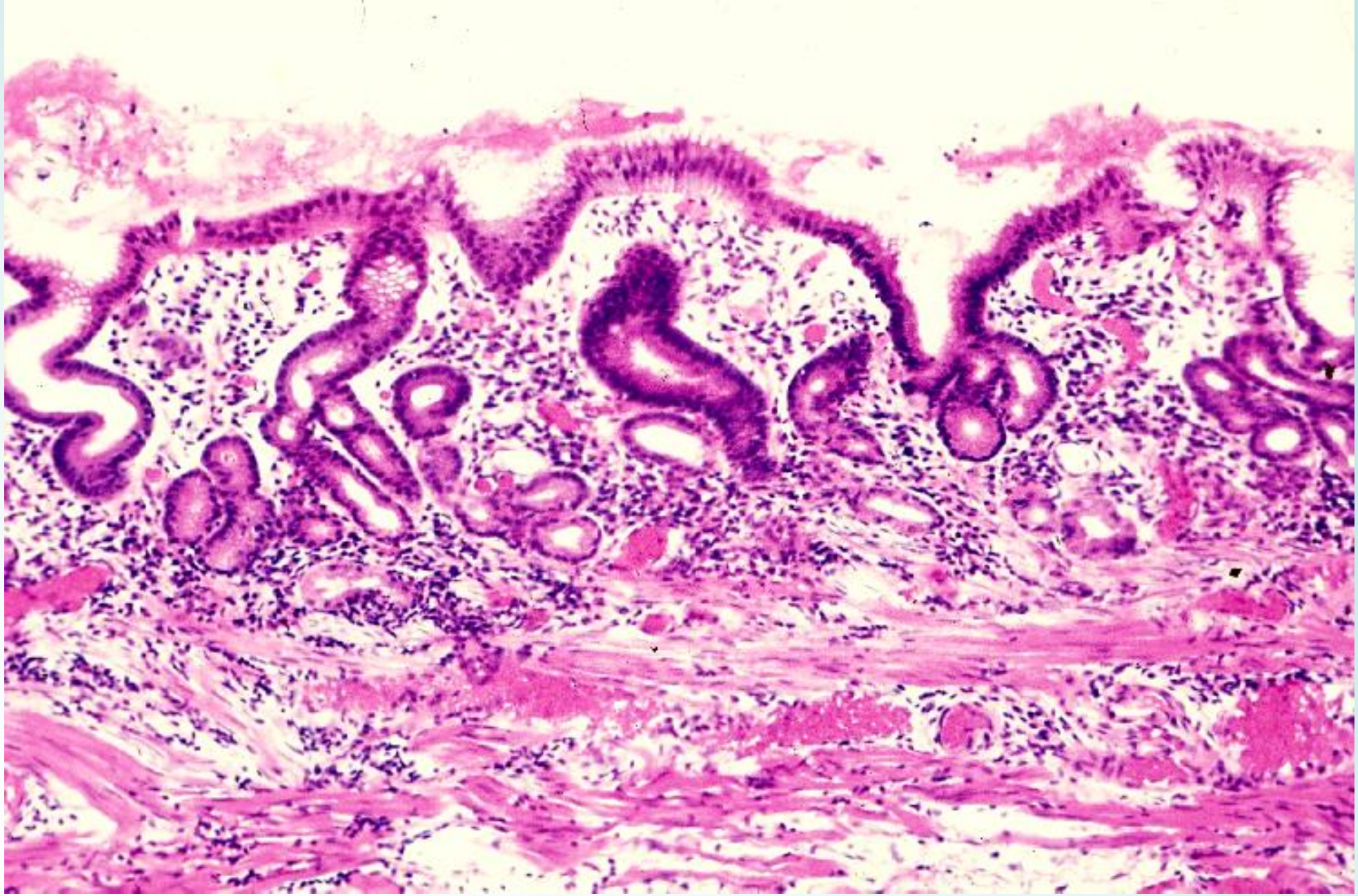

10-28 Mucous membrane of pars pylorica 1. Human, H-E stain, x 30.

10-29 Mucous membrane of pars pylorica 2. Monkey, H-E stain, x 25.

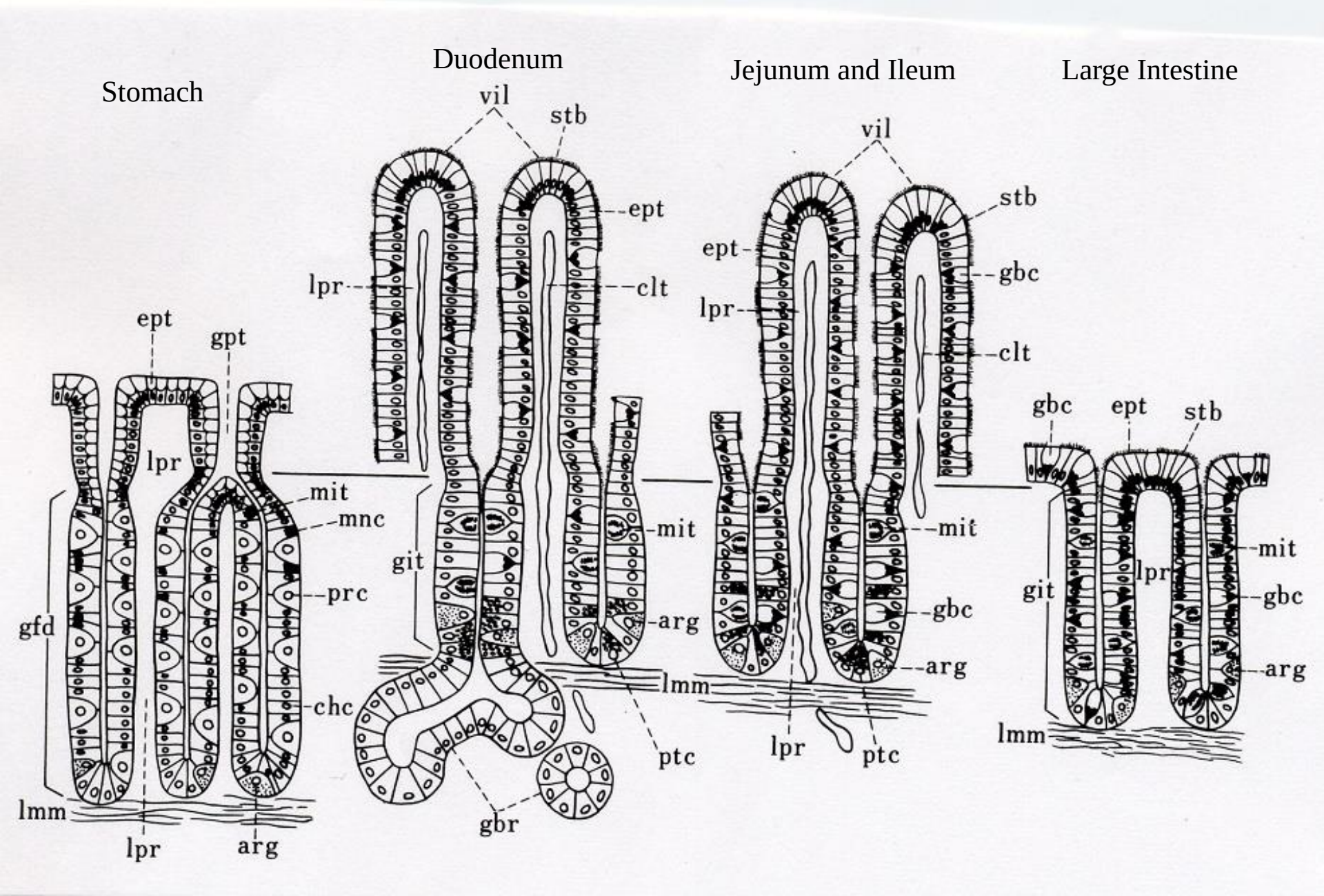

10-30 Mucous membrane and glands of stomach and intestine（Scheme）

Menu Explanation Back

10-00 Digestive System 2 Esophagus & Stomach

10-001 Esophagus

10-01 General structure of the digestive system（Scheme）

- The wall of the digestive tube consists of concentrically arranged several layers; they are from inside to outside ① tunica mucosa, ② tela sumucosa, ③ tunica muscularis and ④ tunica serosa.
- The tunica mucosa, mucous membrane, enclosing the lumen of the tube, consists of an epithelium, underlying loose connective tissue, lamina propria, and thin smooth muscle layer, lamina muscularis mucosae. The mucous membrane is enclosed by a layer of the loose connective tissue of coarse collagen fibers, tela submucosa, and then a thick smooth muscle layers, tunica mucosa, consisting of the inner circularly and outer longitudinally oriented smooth muscle layers. The outermost layer is the tunica serosa, i.e. peritoneum, which forms mesenterium at the posterior midline of the tube and connects the tube to the posterior midline of the abdominal cavity.

10-02 Esophagus, transverse section. Human, H-E stain, x 1.9.

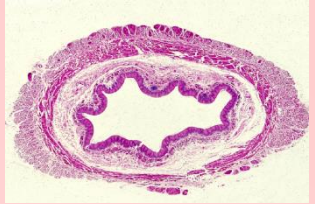

- This figure shows the general view of human esophagus, transversely sectioned.
- Because of the contraction of the circular muscle fibers, outline of the lumen becomes star-shaped.
- The epithelium limiting the lumen is the stratified squamous, not cornified. The lamina propria is thin and without the glands; lamina propria mucosae is thick and conspicuou, consisting of longitudinally oriented smooth muscle fibers.
- The tela mucosa is wide and consists of loose connective tissue of coarse collagen fibers. In this area there are small mixed glands, but numerous in human. In this area small a few groups of nerve cells and fibers are scattered; they are called Meissner's plexus. Tunica muscularis consists of two muscle fiber layers: inner circular and outer longitudinal. they are striated muscle fibers in the oral one third of the esophagus, smooth muscle fibers in the anal one third, and mixture of both types in the middle one third. Between these layers there are small groups of nerve cells and fibers, innervating these musculature, called Auerbach's plexus.
- The outermost layer of the esophagus is wrapped by loose connective tissue, by which the esophagus is connected to the trachea, in front, and vertebral column, backward. This connective tissue is called adventitia

10-03 Esophagus, transverse section. Human, H-E stain, x 10.

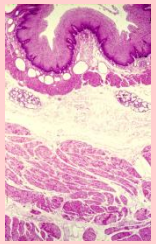

- This specimen was taken from a cadaver which was fixed by infusion of 10% formalin so that capillaries in the lamina propria are all empty.
- The epithelium is thick stratified squamous and lamina muscularis mucasae consisting of longitudinally oriented smooth muscle fibers is very conspicuous. The tela submucosa is wide and two small mixed glands, gll. esophageae, are seen. The musculature , inner circular and outer longitudinal, are thick and consists of both smooth and striated muscle fibers.

10-04 Esophagus, longitudinal section. Human, H-E stain, x 10.

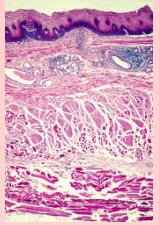

- This is a longitudinal section of human esophagus. The epithelium is thick stratified squamous; at the center beneath the epithelium, crossing the lamina muscularis mucosae, there is a duct of esophageal glands, which locates just beneath the muscularis mucosae. The right gland is densely infiltrated by lymphocytes. The musculature is very thick and the inner circular layer consists of both smooth and striated muscle fibers whereas outer longitudinal layer, of striated muscle fibers.

10-05 Esophagus, longitudinal section. Human, H-E stain, x 25.

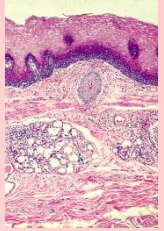

- Higher magnification of 10-04. At center an excretory duct consisting of stratified squamous epithelium is seen. The esophageal glands are of mixed type. The undermost layer of this figure is constituted by longitudinally oriented smooth muscle fibers i.e. inner circular layer of the tunica muscularis.

10-06 Auerbach's plexus, 1. Monkey, H-E stain, x 30.

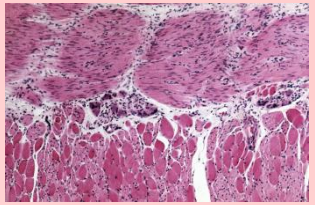

- This is the tunica muscularis of monkey fixed with SUSA fixative. The inner circular layer consists of smooth muscle fibers whereas outer longitudinal layer consists of both smooth and striated muscle fibers. Between the two muscle layers two groups of nerve cells are conspicuous, i.e. Auerbach's plexus.

10-07 Auerbach's plexus, 2. Monkey, H-E stain, x 160.

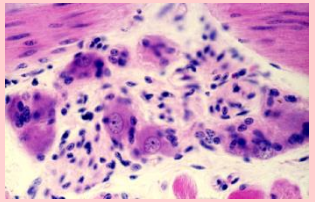

- Higher magnification of 10-06. The Auerbach's plexus consists of several nerve cells and bundles of nerve fibers. In this specimen the cytoplasmic basophilia of the nerve cells is evident.

10-002 Stomach

10-08 Cardia, 1. General view. Monkey, H-E stain, x 3.

- The opening from the esophagus into stomach is called the cardia.
- This figure shows a longitudinal section of the transition from the esophagus to the stomach: the upper portion of this figure is mostly esophagus and only the lower edge of the figure is covered by the gastric mucosa. The arched clefts at the center are the esophageal lumen and at its lowermost right part, indicated by arrow, the esophageal epithelium shifts abruptly to the gastric epithelium.

10-09 Cardia, 2. Esophagogastric junction. Monkey, H-E stain, x 10.

- Higher magnification of 10-08. The left half of the field is the stratified squamous epithelium of the esophagus and the right half is the simple columnar epithelium of the stomach. The abrupt transition of the epithelium is evident.

10-10 Cardia, 3. Abrupt transition of epithelium. Monkey, H-E stain, x 25.

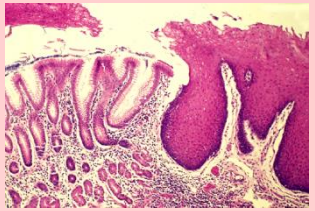

- This figure shows the abrupt transition of the epithelium, from the stratified squamous to the simple columnar, clearly. In the esophagus no glands are seen in the lamina propria whereas in the stomach numerous tubular glands, cardiac glands, are in the lamina propria.

10-11 Cardiac glands. Monkey, H-E stain, x 65.

- The cardiac glands are distributed in the narrow area surrounding the cardia. They are short tubular glands with tortuous course, so that in sections they appear as groups of transversely sectioned round lumens, which are enclosed by the simple cuboidal epithelium. The appearance of this gland is very alike to the mucous gland.

10-12 Wall of the stomach body. Human, H-E stain, x 2.7.

- This is a general view of the wall of the stomach body (fundus) from a man who had committed suicide by drinking formalin. The wall consists of mucous membrane, tela submucosa, tunica muscularis and tunica serosa. The membrane is thick and appears dark reddish violet. Tela sumucosa is a loose connective tissue of coarse collagen fibers and contains numerous blood vessels of large caliber. Tunica mucosa consists of three layers of smooth muscle fibers, oblique, circular and longitudinal, but their identification is difficult on each section. Tunica serosa is the peritoneum itself: simple squamous epithelium and underlying small amount of loose connective tissue.

10-13 Mucous membrane of the stomach body, 1. Human, H-E stain, x 25.

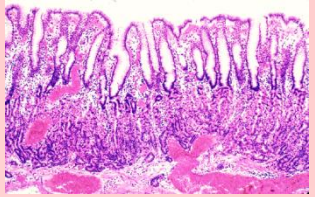

- This is a perpendicular section through the mucous membrane; about the half thickness of it is occupied by a multitude of the gastric (fundus) glands. The surface epithelium is simple tall columnar in shape and sinks deeply into the lamina propria to form innumerable tubular invaginations, gastric pits, into the bottom of which open the fundus glands. Fundus glands are long tubular glands with narrow lumen and consists of three kinds of acinar cells.
- The lower edge of this figure is the lamina muscularis mucosae.

10-14 Mucous membrane of the gastric body, 2. Human, H-E stain, x 30.

- This is a very thin section so that the fine structure of the gastric mucous membrane is well discernible. The surface epithelium, deep gastric pits and long tubular glands opening into the bottom of the gastric pits and very loose connective tissue underlying these structures, lamina propria, are all clearly recognized.
- The lower middle portion of this figure is shown in 10-24 at higher magnification.

10-15 Surface epithelium and gastric pits, 1. Human, H-E stain, x 100.

- The surface epithelium is tall columnar in shape, whose apical portion is filled with mucous substance and nucleus is pressed to the basement membrane. This epithelium sinks deeply into the lamina propria to form gastric pits. Beneath the epithelium and around the pits is filled with the loose connective tissue, lamina propria, containing numerous capillaries and small blood vessels and a number of free cells.

10-16 Surface epithelium and gastric pits, 2. Human, H-E stain, x 130.

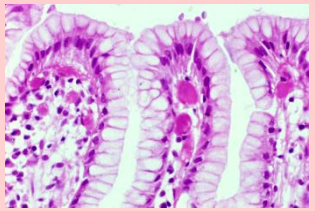

- The apical portion of the epithelial cells is filled with mucous substance and the nuclei locate near the basement membrane, beneath which numerous capillaries are seen. The lamina propria is very loose connective tissue containing free cells.

10-17 Gastric epithelium. Human, mucicarmin and hematoxylin stain, x 100.

- The entire supranuclear portion of the epithelial cells on the free surface is occupied by granules of a peculiar type of mucigen, which are only visualized by mucicarmin or PAS reaction. In this specimen, stained by mucicarmin, red stained fine granules filling the apical portion of the epithelial cells are evident.
- This specimen was made by late Prof. Dr. S. Miki.

10-18 Mucous membrane of stomach body, showing the hole length of the fundus glands. Human, H-E stain, x 25.

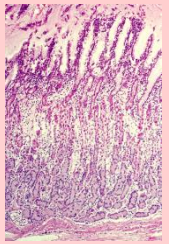

- This specimen was taken from a cadaver three hours post mortem. The surface epithelium and that of the gastric pits are almost degenerated but the fundus glands are relatively well preserved.
- The fundus glands are simple, branched tubular glands with very narrow lumen and consist of three kinds of glandular cells. These glands are closely packed together and oriented perpendicular to the surface of the mucosa. They open, from one to several, through a slight constriction or neck into the bottom of each gastric pit. They extend through its entire thickness of 0.3 to 1.5 mm and their diameter is 30 to 50 μm. The blind ends are slightly thickened and coiled and sometimes divide into two or three branches and reach almost to the lamina muscularis mucosae. Each of them is separated by a few loose connective tissue of the lamina propria.
- In this figure, the upper one third is the degenerated residue of the surface epithelium and that of the gastric pits, the lower two thirds are the densely packed fundus glands and the bottom edge is the lamina muscularis mucosae.
- Figures 10-19 to 10-22 are higher magnifications of this specimen.

10-19 Fundus glands, neck 1. Human, H-E stain, x 64.

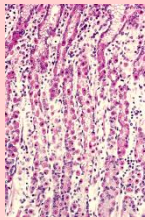

- This is the higher magnification of 10-18, showing the neck of the glands. At top there are several bottoms of the gastric pits, into which open the fundus glands. Beneath these follow the upper half of the glands consisting of mucous neck cells and parietal cells that are stained deep red. Each gland is separated by a few loose connective tissue, lamina propria. At lower most region of this figure appear the chief cells with violet cytoplasm.

10-20 Fundus glands, bottom 1. Human, H-E stain, x 64.

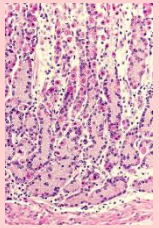

- This figure is lower continuation of 10-19. In the upper one fourth of this figure there are still mucous neck cells whereas in the lower two thirds the glands consist of mainly chief cells and a few parietal cells. The bottom edge is the lamina muscularis mucosae.

10-21 Fundus glands, neck 1. Human, H-E stain, x160.

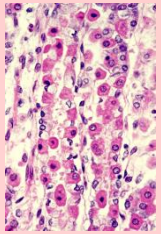

- This is the higher magnification of 10-19. In this region the glands consist of mucous neck cells and parietal cells.
- The mucous neck cells, secreting mucus, are relatively few in number and lodged between the parietal cells. They appear to be deformed by neighboring cells and tend to be irregular in shape, some having a wide base and narrow apex, others a broad apex and narrow base. The cytoplasm appears colorless and transparent. The nuclei, dark blue stained, are at the base of cells and are often somewhat flattened.
- The parietal cells, secreting hydrochloric acid, whose cytoplasm stains deeply red with eosin, are large spherical or pyramidal in shape and occupy a peripheral position with their tapering apical ends. Sometimes they bulge on the outer surface of the glands. Each of them contains a single large round nucleus, dark blue stained, but sometimes two or even more nuclei are present in one cell.
- In this figure the lumen of the glands is relatively wide and both side of that form a line the mucous neck cells and the parietal cells. In the lamina propria, separating each gland, there are smooth muscle fibers (arrows), oriented perpendicular.

10-22 Fundus glands, bottom 2. Human, H-E stain, x 160.

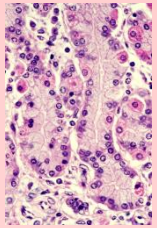

- Higher magnification of 10-20. In this figure the narrow lumen appears evidently and the gland itself consists mainly of the chief cells, among which a few parietal cells are scattered. The chief cells are columnar in shape and their nuclei are round and locate near the basement membrane. The cytoplasm stains violet but in usual sections no secretion granules are recognized. In the lamina propria numerous free cells are seen.

10-23 Fundus glands, neck 3. H-E stain, x 160.

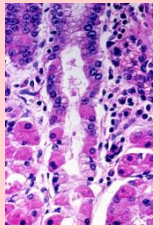

- This is another specimen than 10-19. In this case mucous neck cells between parietal cells are conspicuous.

10-24 Fundus glands, bottom 3. H-E stain x 400.

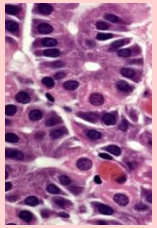

- Higher magnification of 10-14. Because of the good fixation and the thinness of the section fine structures of the fundus glands are well observed. The cytoplasm of the chief cells shows basophilic stainability very well and in the parietal cells the intracellular secretory canaliculi are clearly recognized (arrows).

10-25 Fundus glands, bottom 4. Monkey, H-E stain, x 160.

- This specimen was treated with a fixative containing the potassium dichromate so that the enterochromaffin cells are visualized. In this figure three enterochromaffin cells are seen (arrows).

10-26 Fundus gland, bottom 5. Monkey, H-E stain, x 400.

- This specimen was also treated with a fixative containing the potassium dichromate. The cytoplasm of the chief cells shows evident basophilia and filled with granules. A deep red stained large cell locating at bottom right is parietal cell, which shows the intracellular secretory canaliculi in the supranuclear region. An enterochromaffin cell is seen at upper left edge of the gland (arrow). A thick band along the left side of the gland is a sooth muscle fiber bundle in the lamina propria.

10-27 Wall of the pyloric region, general view. Human, H-E stain, x 2.0.

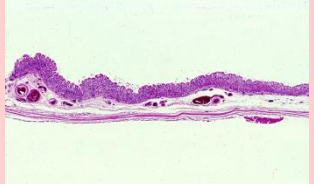

- This is a longitudinal section of human pyloric region. The boundary between the fundus and pars pylorica is sometimes not clear but in this specimen it is easily identified. In this figure the right three fifth contain the fundus glands whereas left two fifth the pyloric glands. The boundary is indicated with an arrow.

10-28 Mucous membrane of pars pylorica 1. Human, H-E stain, x 30.

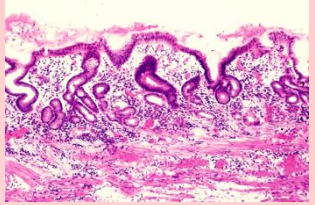

- This is the mucous membrane of the pars pylorica. Into the bottom of the gastric pits open the pyloric glands which are short tortuous tubular glands, very alike to the cardiac glands. The lower one third of this figure is occupied by smooth muscle fiber bundles of lamina muscularis mucosae.

10-29 Mucous membrane of pars pylorica 2. Monkey, H-E stain, x 25.

- In this specimen, deep gastric pits and into their bottom opening pyloric glands are seen. The pyloric glands are short tortuous tubular glands with relatively wide lumen. In the lamina propria numerous free cells are seen. The lowermost region of this field traverse the smooth muscle bundles of the lamina muscularis mucosae.

10-30 Mucous membrane and glands of stomach and intestine（Scheme）

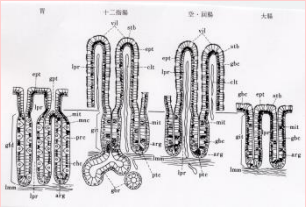

- This is to show the mucous membrane and glands in stomach and three different regions of the intestine.