

# 16-00

# Male Reproductive System

# 16 Male Reproductive System

## Menu 1 / 2

- [16-00.](#) Male Reproductive System
- [16-001.](#) Testis
- [16-01.](#) Scheme of male reproductive system.
- [16-02.](#) Sagittal section of a human testis. General view. H-E stain, x 1.0.
- [16-03.](#) Seminiferous tubules and interstitium. General view. Human, H-E stain, x 25.
- [16-04.](#) Seminiferous tubules and Leydig cells. Human, H-E stain, x 64.
- [16-05.](#) Interstitial cells of Leydig. Human, H-E stain, x 160.
- [16-06.](#) Seminiferous tubules 1. Monkey, H-E stain, x 100.
- [16-07.](#) Scheme showing the spermatogenesis.
- [16-08.](#) Seminiferous tubule 2. Spermatogonia and primary spermatocytes. Monkey, H-E stain, x 100.
- [16-09.](#) Seminiferous tubule 3. Spermatogonia and secondary spermatocytes. Monkey, H-E stain, x 100.
- [16-10.](#) Seminiferous tubule 4. Spermatogonia and spermatids. Monkey, H-E stain, x 100.
- [16-11.](#) Spermatogenesis 1. Spermatogonia and primary spermatocytes. Monkey, H-E stain, x 250.
- [16-12.](#) Spermatogenesis 2. Spermatogonia and secondary spermatocytes. Monkey, H-E stain, x 250.
- [16-13.](#) Spermatogenesis 3. Spermatogonia and spermatids. Monkey, H-E stain, x 250.
- [16-14.](#) Scheme showing the spermiogenesis.
- [16-15.](#) Spermiogenesis 1. Monkey, H-E stain, x 250.
- [16-16.](#) Spermiogenesis 2. Monkey, H-E stain, x 250.
- [16-17.](#) Spermiogenesis 3. Monkey, H-E stain, x 250.
- [16-18.](#) Spermiogenesis 4. Monkey, H-E stain, x 250.
- [16-19.](#) Spermiogenesis 5. Monkey, H-E stain, x 250.
- [16-20.](#) Spermatogenesis in the human testis. H-E stain, x 250.
- [16-21.](#) Tubuli seminiferi contorti et recti. Monkey, H-E stain, x 64.
- [16-22.](#) Transition from contortus to rectus tubule 1. Monkey, H-E stain, x 64.
- [16-23.](#) Transition from contortus to rectus tubule 2. Human, H-E stain, x 100.
- [16-24.](#) Rete testis 1. Human, H-E stain, x 40.
- [16-25.](#) Rete testis 2. Human, H-E stain, x 100.
- [16-26.](#) Transition from rete testis to efferent ductulus 1. Human, H-E stain, x 25.
- [16-27.](#) Transition from rete testis to efferent ductulus 2. Human, H-E stain, x 100.
- [16-28.](#) Ductuli efferentes testis 1. Human, H-E stain, x 64.
- [16-29.](#) Ductulus efferens testis 2. Human, H-E stain, x 160.
- [16-30.](#) Transition from the ductulus efferens to the ductus epididymidis. Monkey, H-E stain, x 64.
- [16-31.](#) Ductus epididymidis 1. Human, H-E stain, x 25.
- [16-32.](#) Ductus epididymidis 2. Monkey, H-E stain, x 64.
- [16-002.](#) Spermatic cord, Seminal vesicle, Prostate and Penis



# 16 Male Reproductive System

## Menu 1 / 2

[16-33.](#) Funiculus spermaticus. Transverse section. Human, H-E stain, x 2.4.

[16-34.](#) Ductus deferens, transverse section. Human, H-E stain, x 10.

[16-35.](#) Epithelium of ductus deferens. Human, H-E stain, x 64.

[16-36.](#) Seminal vesicle 1. Transverse section. Human, H-E stain, x 10.

[16-37.](#) Seminal vesicle 2. Human, H-E stain, x 25.

[16-38.](#) Seminal vesicle 3. Human, H-E stain, x 100.

[16-39.](#) Seminal vesicle 4. Human, H-E stain, x 100.

[16-40.](#) Prostate gland 1, Horizontal section, general view. Monkey, H-E stain, x 2.0.

[16-41.](#) Prostate gland 2, Urethra and colliculus seminalis, Monkey, H-E stain, x 4.0.

[16-42.](#) Prostate gland 3. General view. Human, H-E stain, x 1.8.

[16-43.](#) Prostate gland 4. Acini and interstitium. Human, H-E stain, x 25.

[16-44.](#) Prostate gland 5. Prostatic concretions. Human, H-E stain, x 64.

[16-45.](#) Glandula bulbourethralis 1. Human, H-E stain, x 25.

[16-46.](#) Glandula bulbourethralis 2. Human, H-E stain, x 64.

[16-47.](#) Penis, transverse section. General view. Human, H-E stain, x 0.8.

[16-003.](#) Testis of a 2.9-year-old Boy

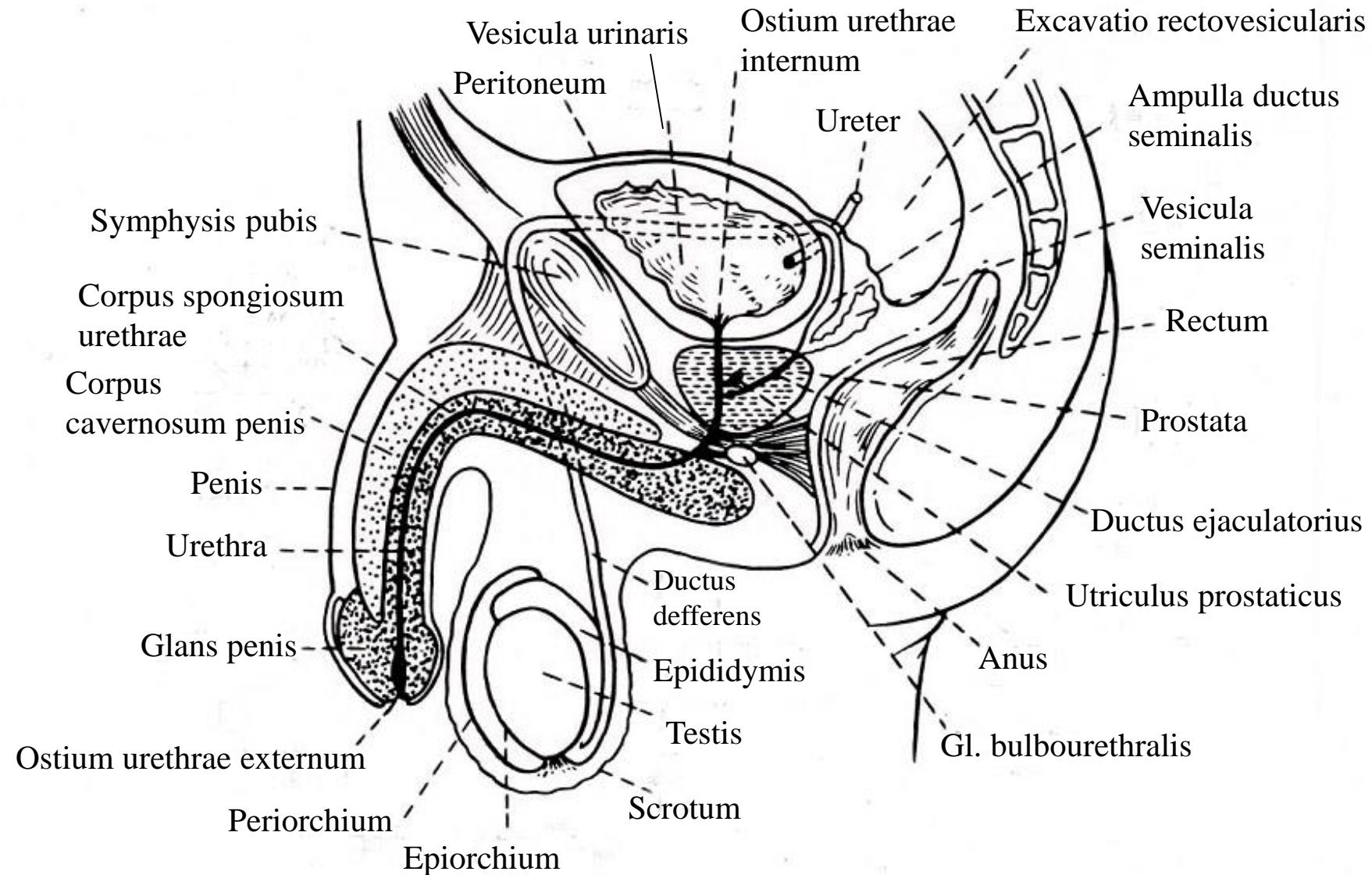
[16-48.](#) Testis of a 2.9-year-old boy, 1. Sagittal section, general view. Human, H-E stain, x10.

[16-49.](#) Testis of a 2.9-year-old boy, 2. Human, H-E stain, x 25.

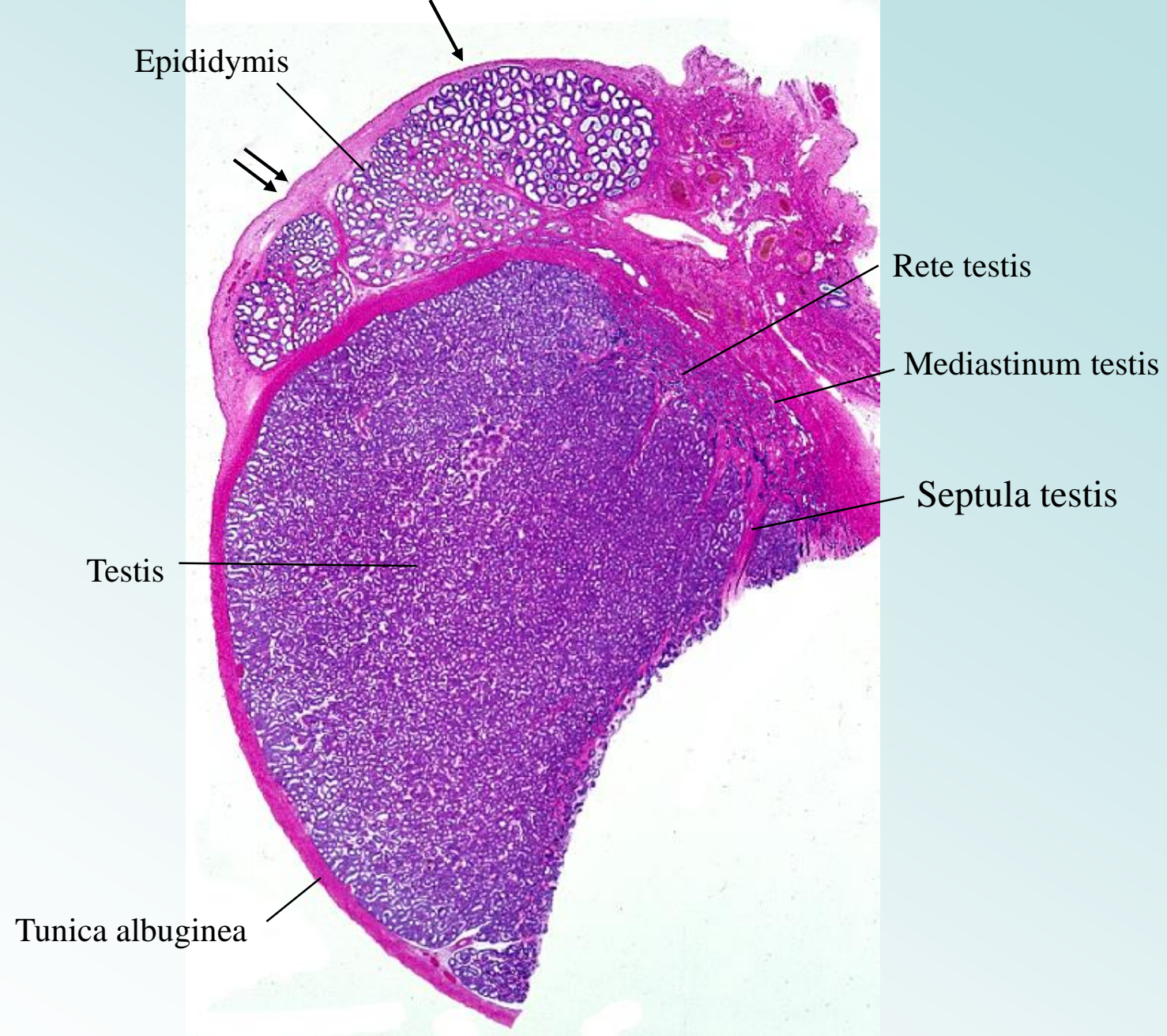
[16-50.](#) Testis of a 2.9-year-old boy, 2. Human, H-E stain, x 160.

# 16-001

# Testis

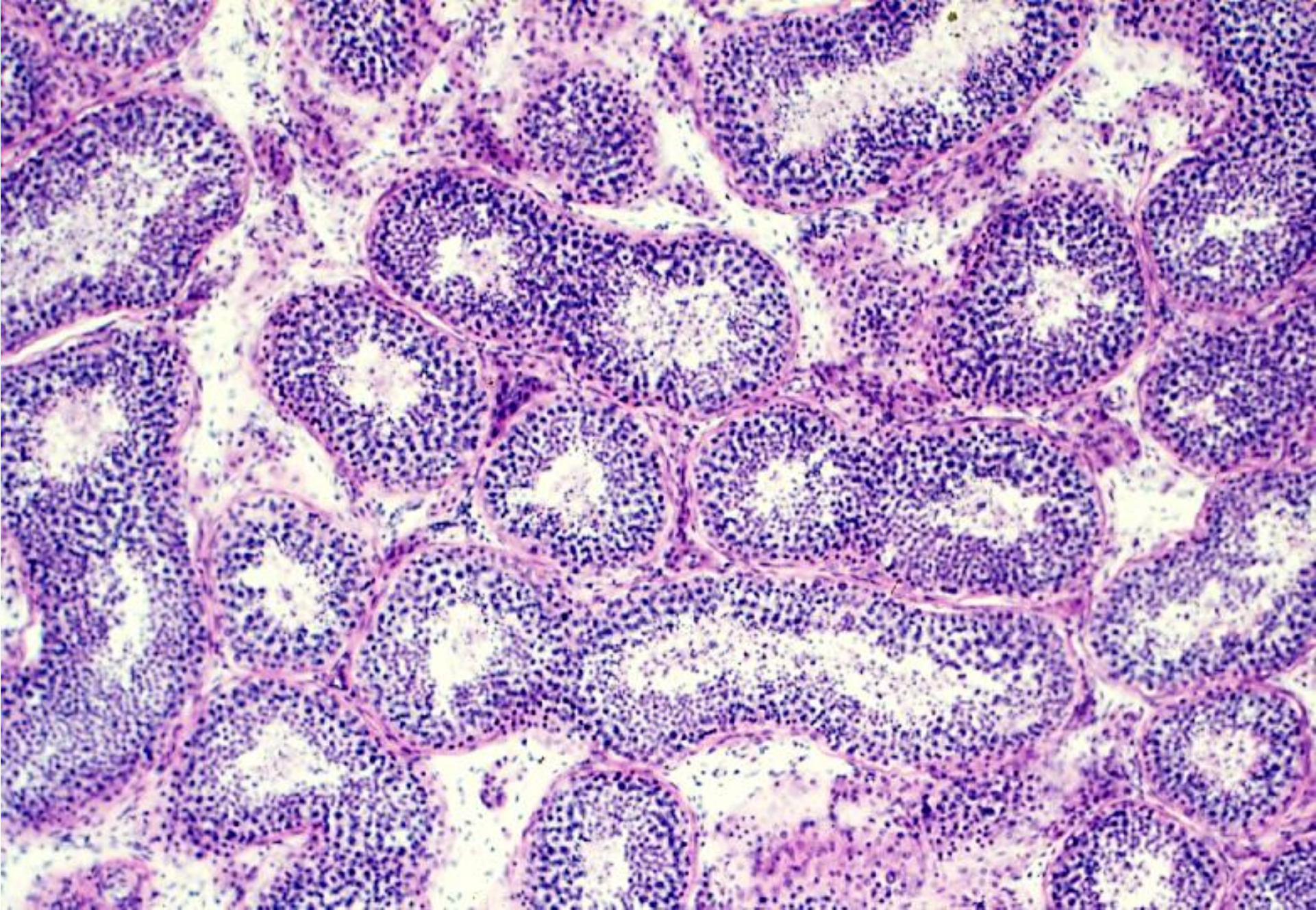






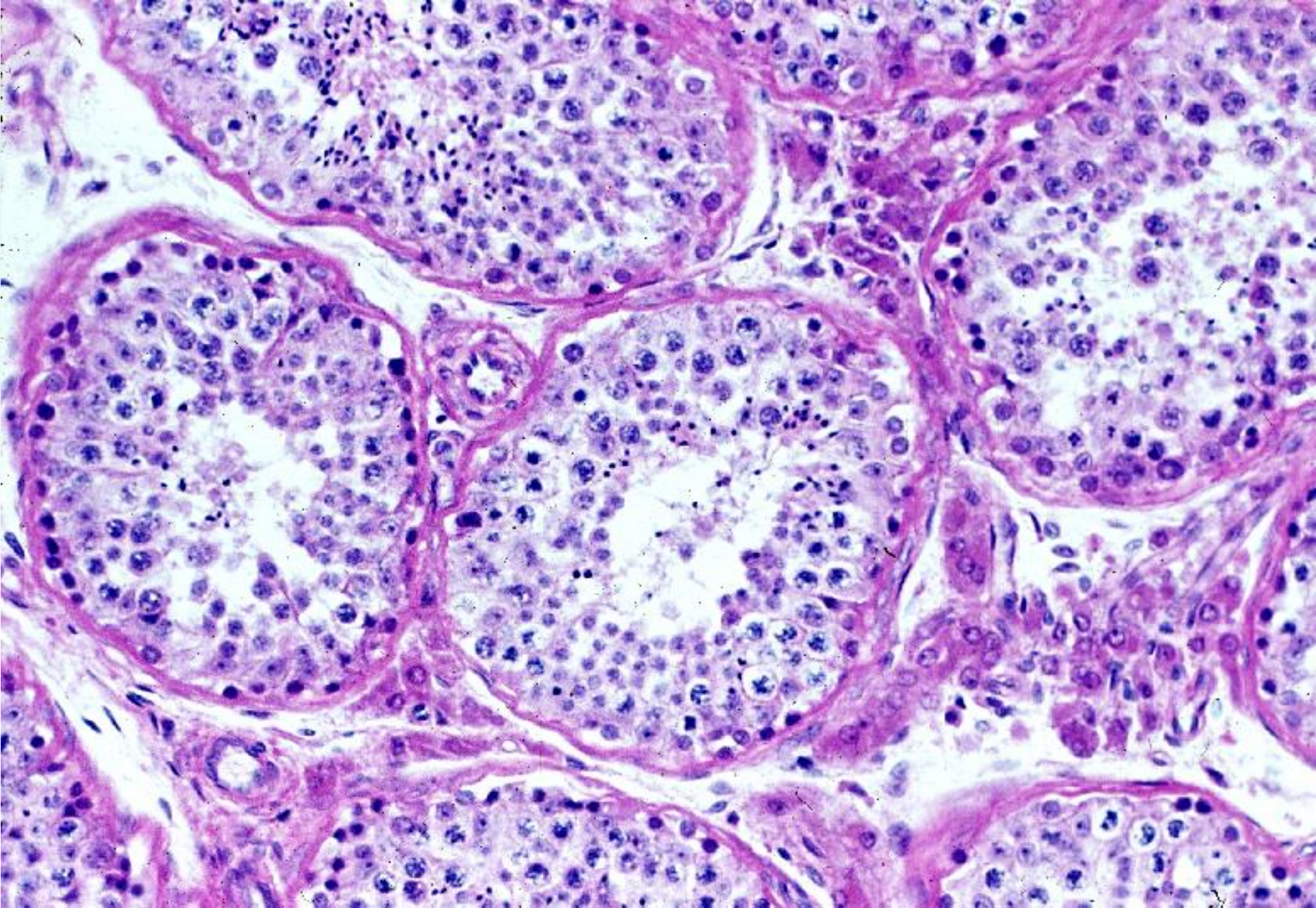
**16-02** Sagittal section of a human testis. General view. H-E stain, x 1.0.





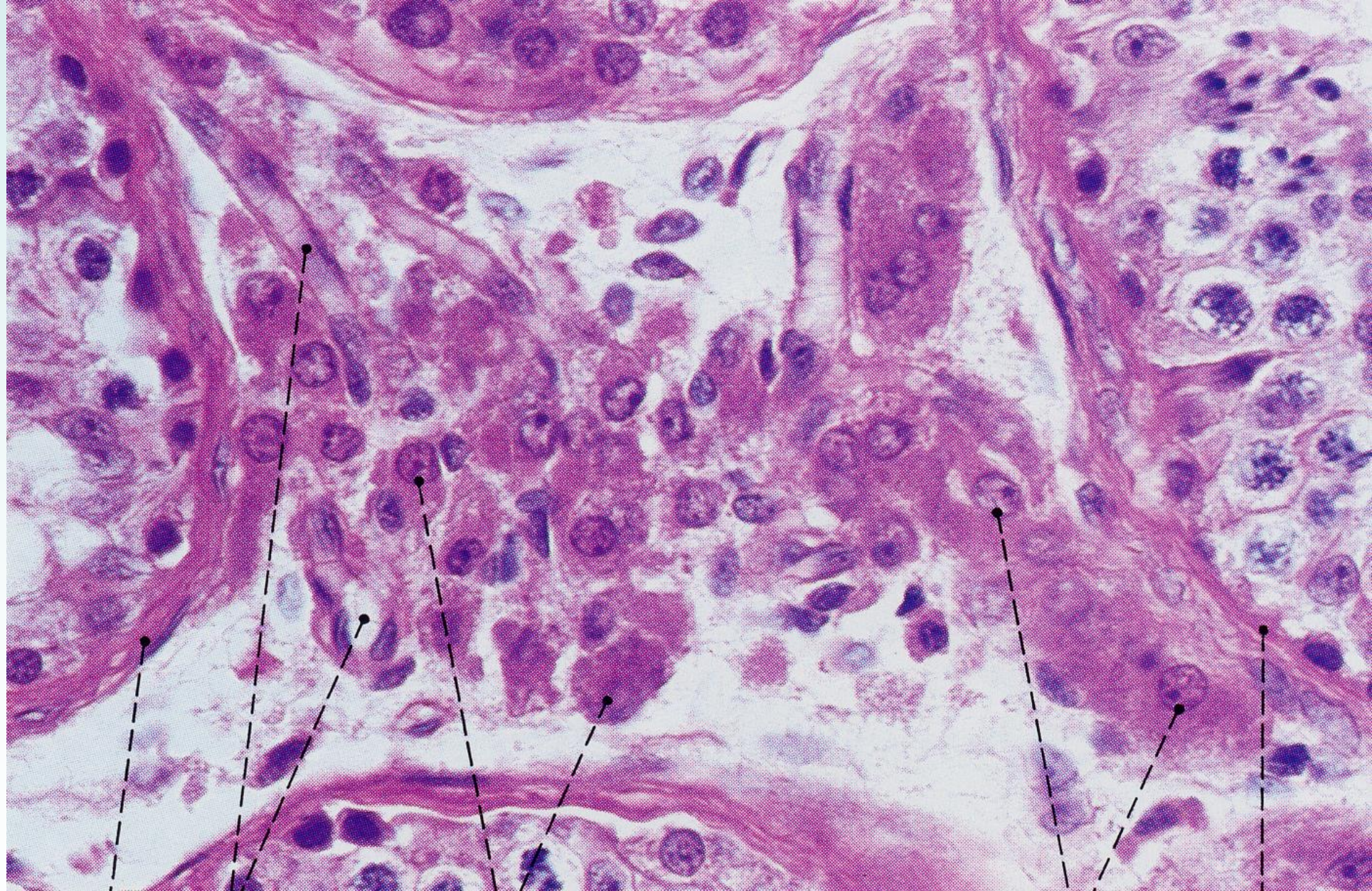
**16-03 Seminiferous tubules and interstitium. General view. Human, H-E stain, x 25.**





16-04 Seminiferous tubules and Leydig cells. Human, H-E stain, x 64.





Basement  
membrane

Blood vessels

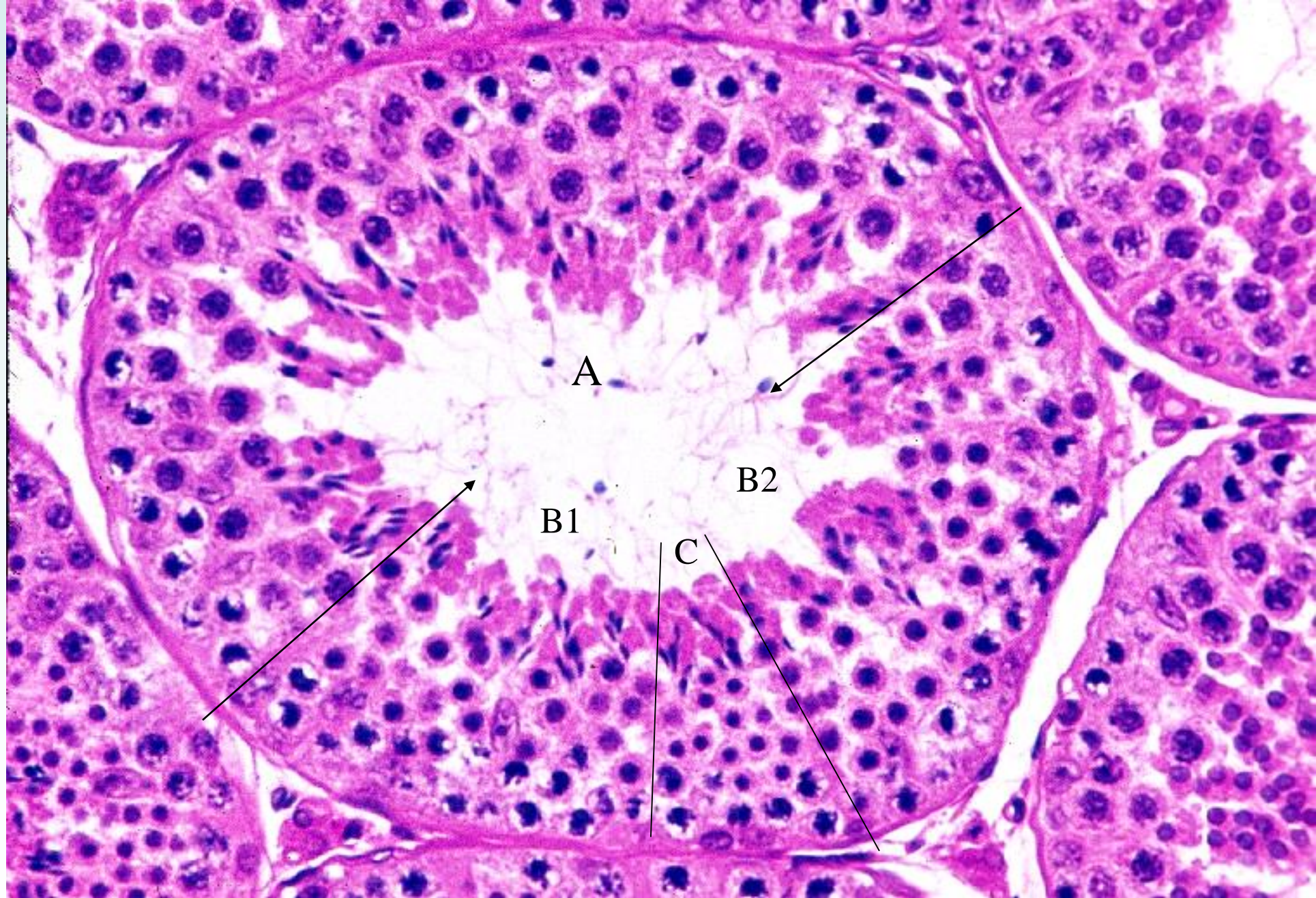
Interstitial cells

Interstitial cells

Basement  
membrane

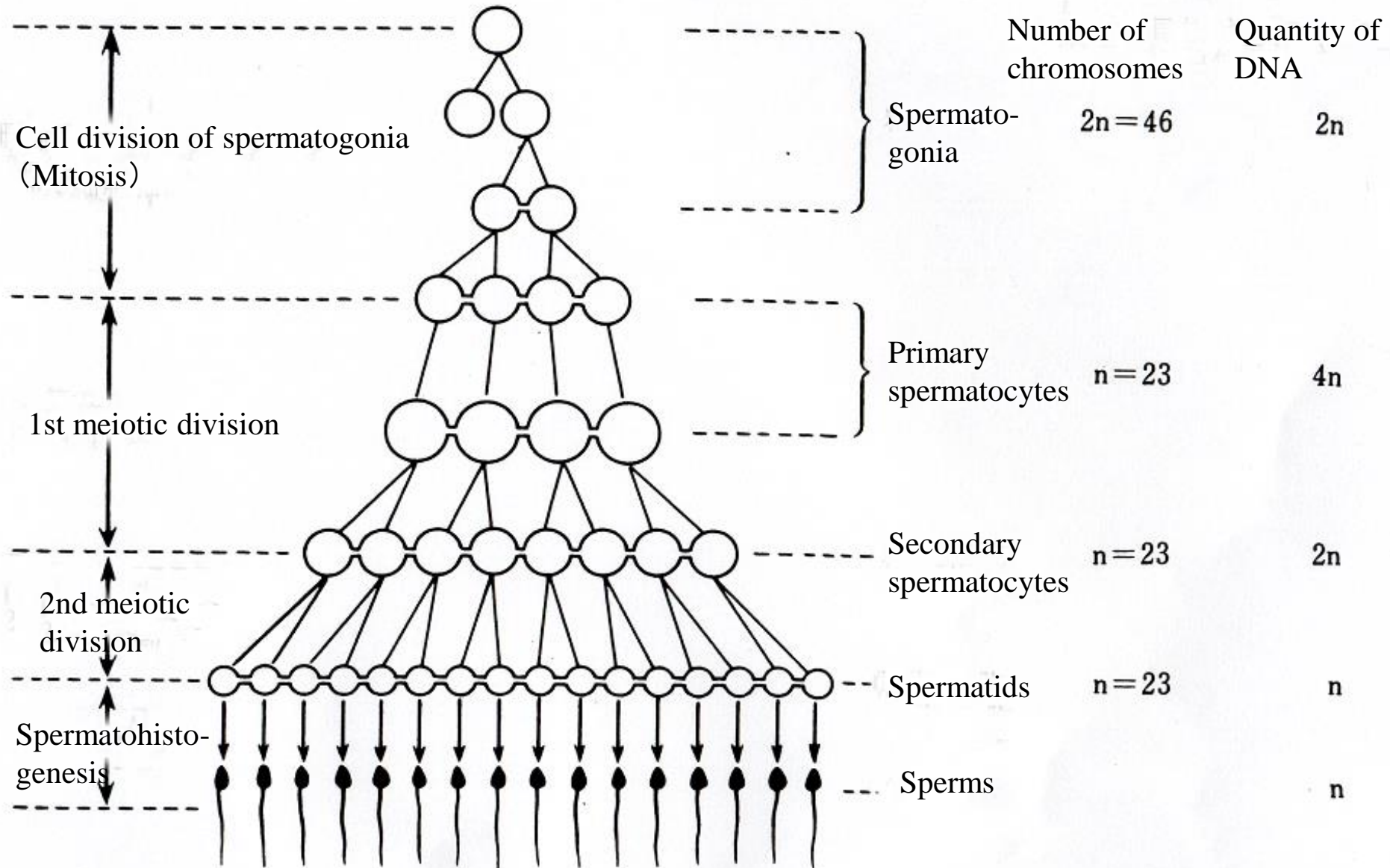
**16-05 Interstitial cells of Leydig. Human, H-E stain, x 160.**

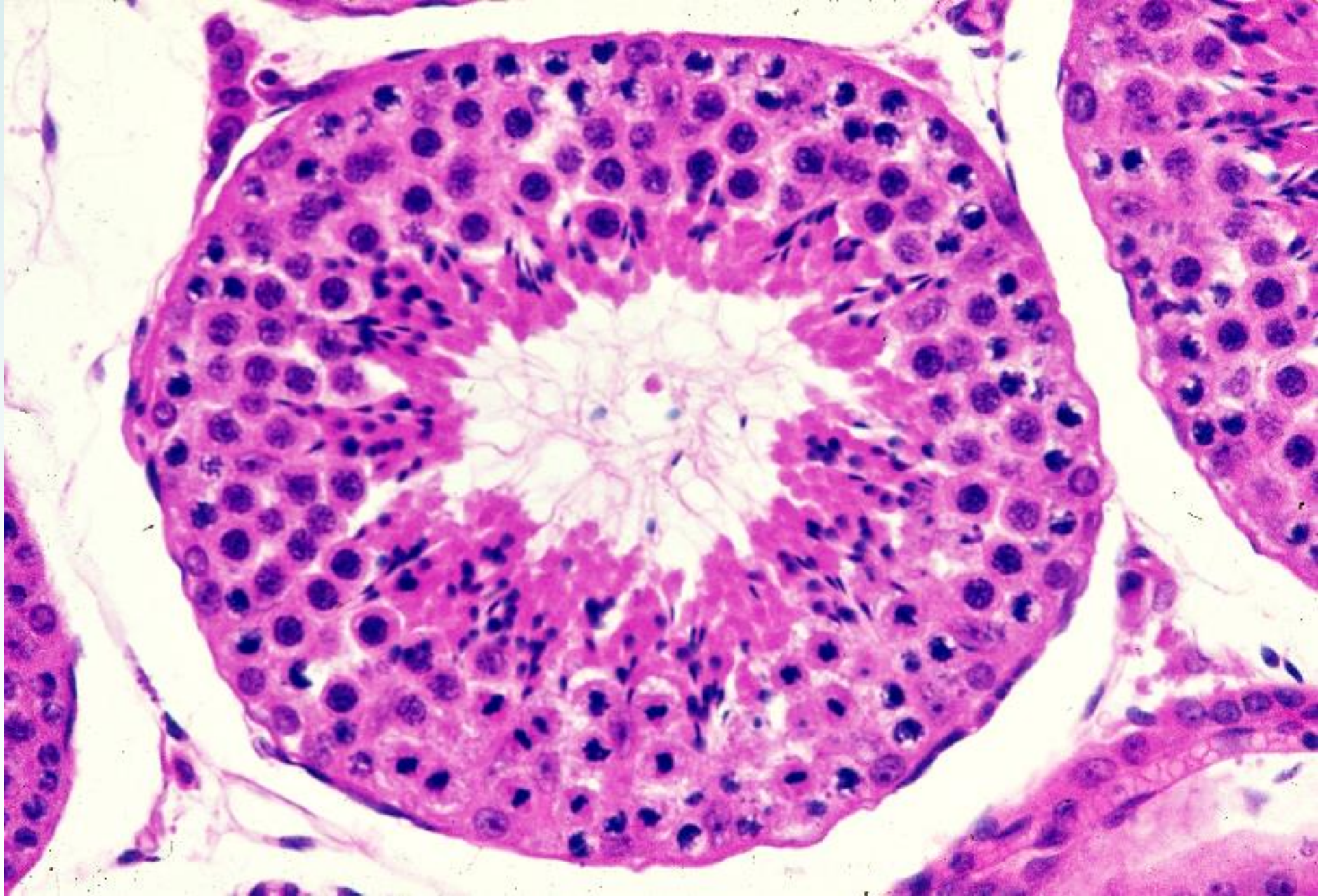




16-06 Seminiferous tubules 1. Monkey, H-E stain, x 100.

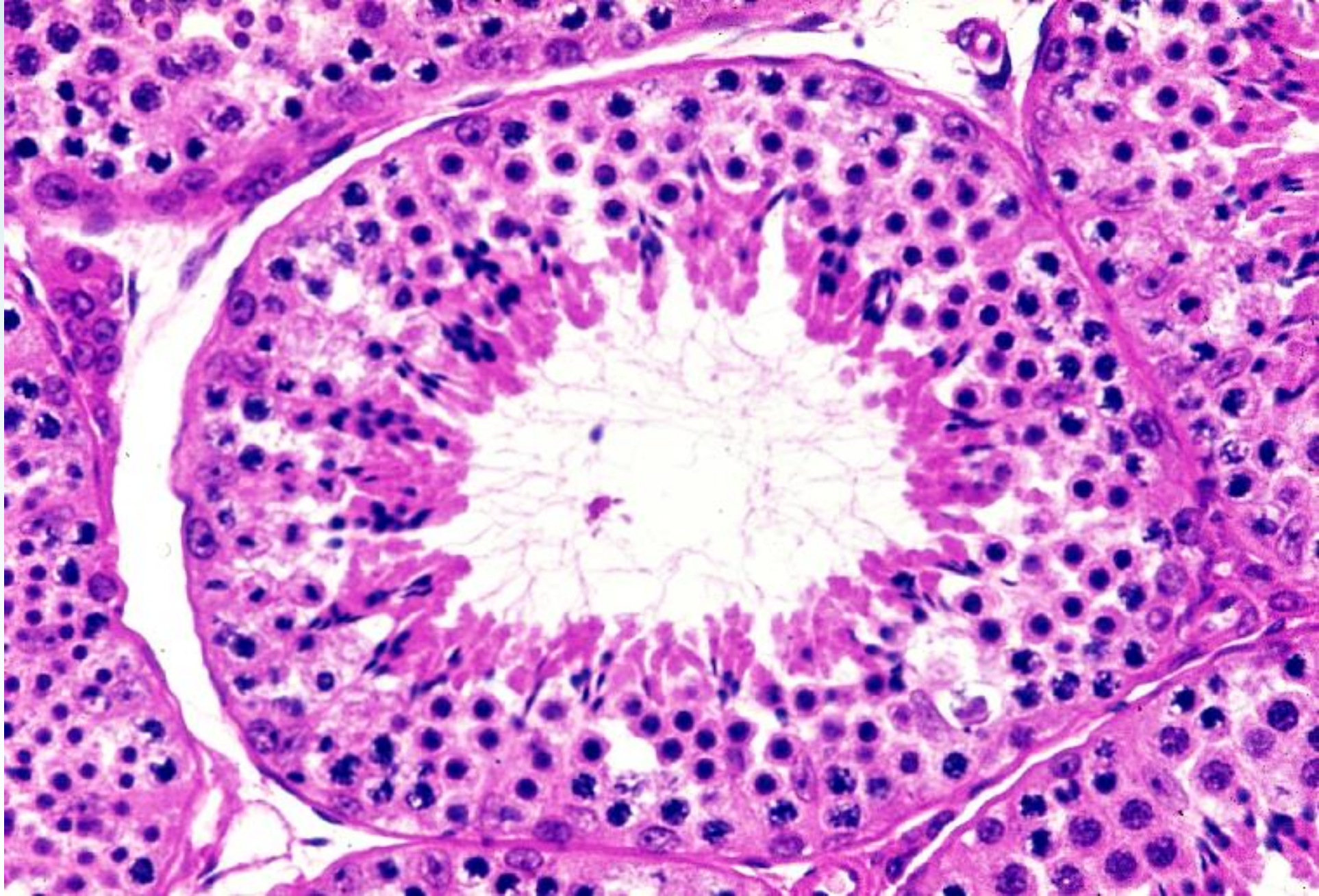






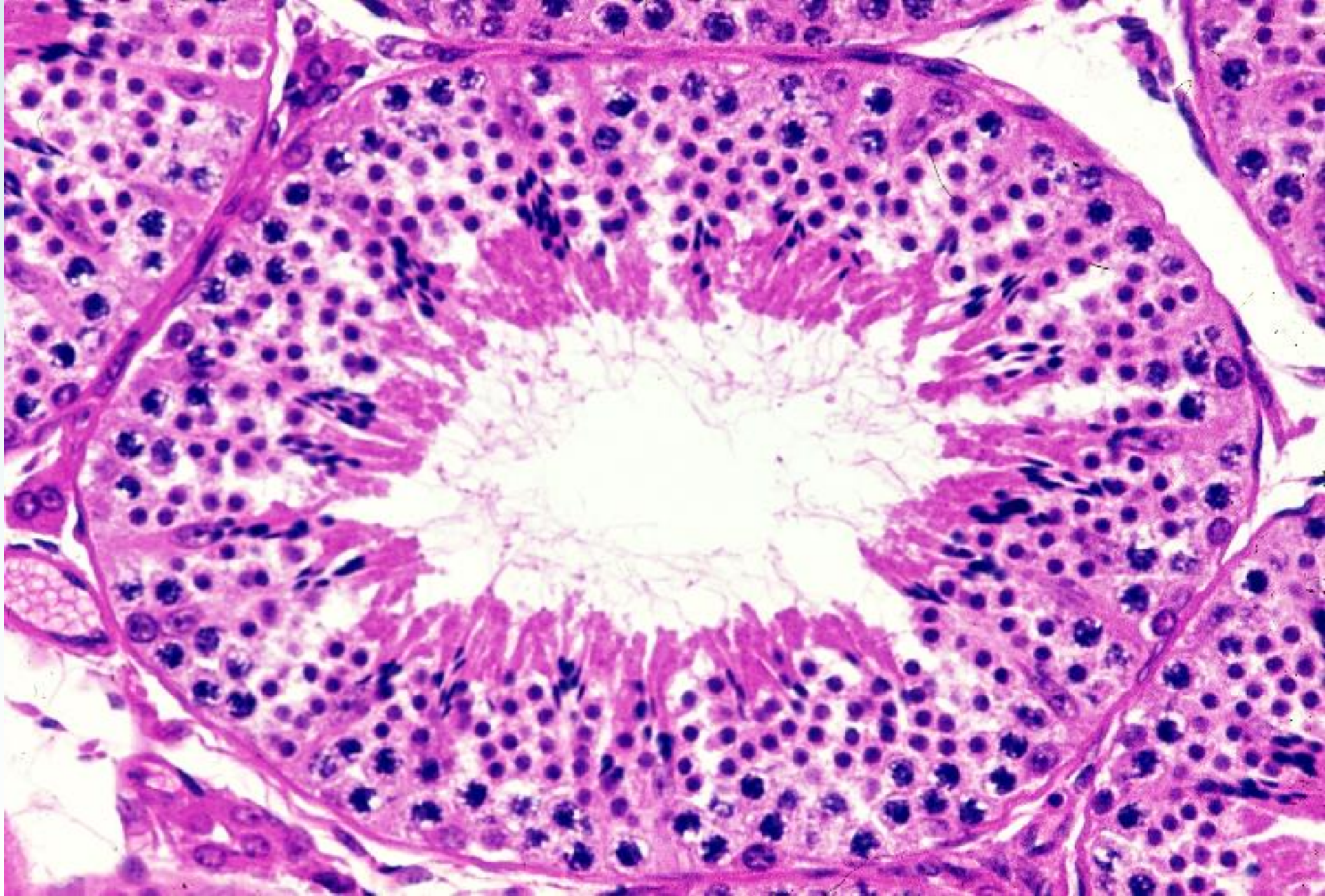
**16-08 Seminiferous tubule 2. Spermatogonia and primary spermatocytes. Monkey, H-E stain, x 100.**





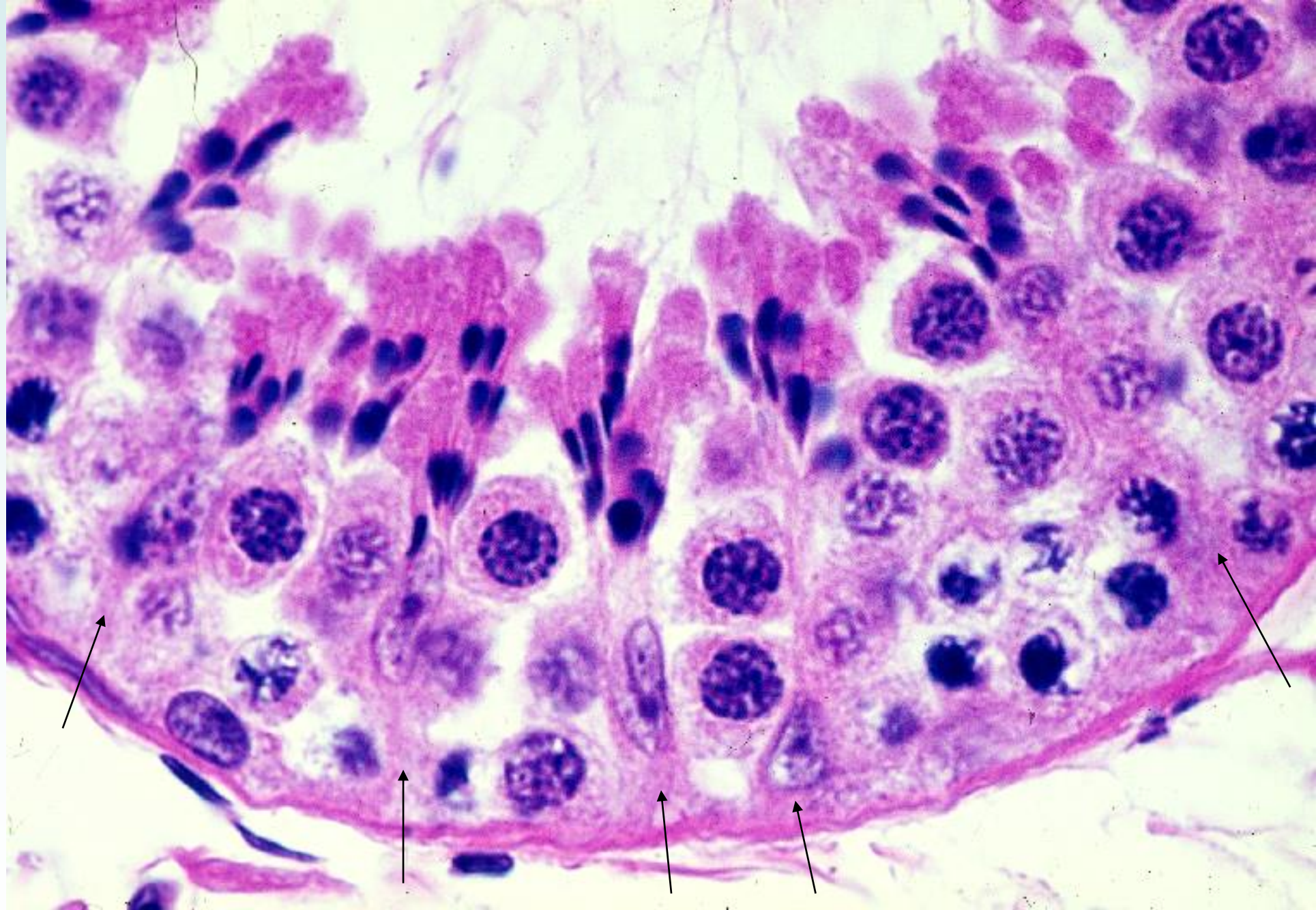
16-09 Seminiferous tubule 3. Spermatogonia and secondary spermatocytes. Monkey, H-E stain, x 100.





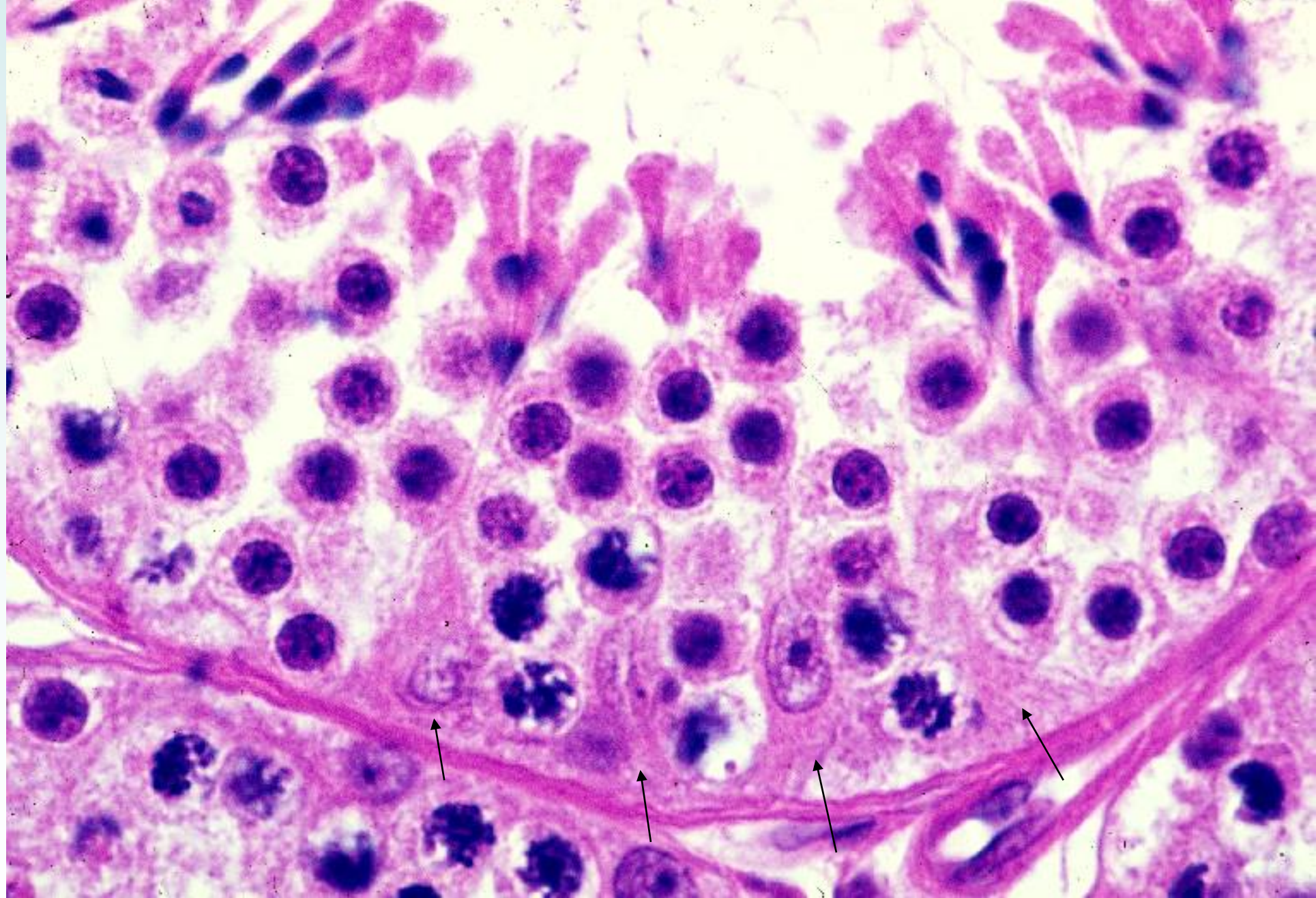
16-10 Seminiferous tubule 4. Spermatogonia and spermatids. Monkey, H-E stain, x 100.





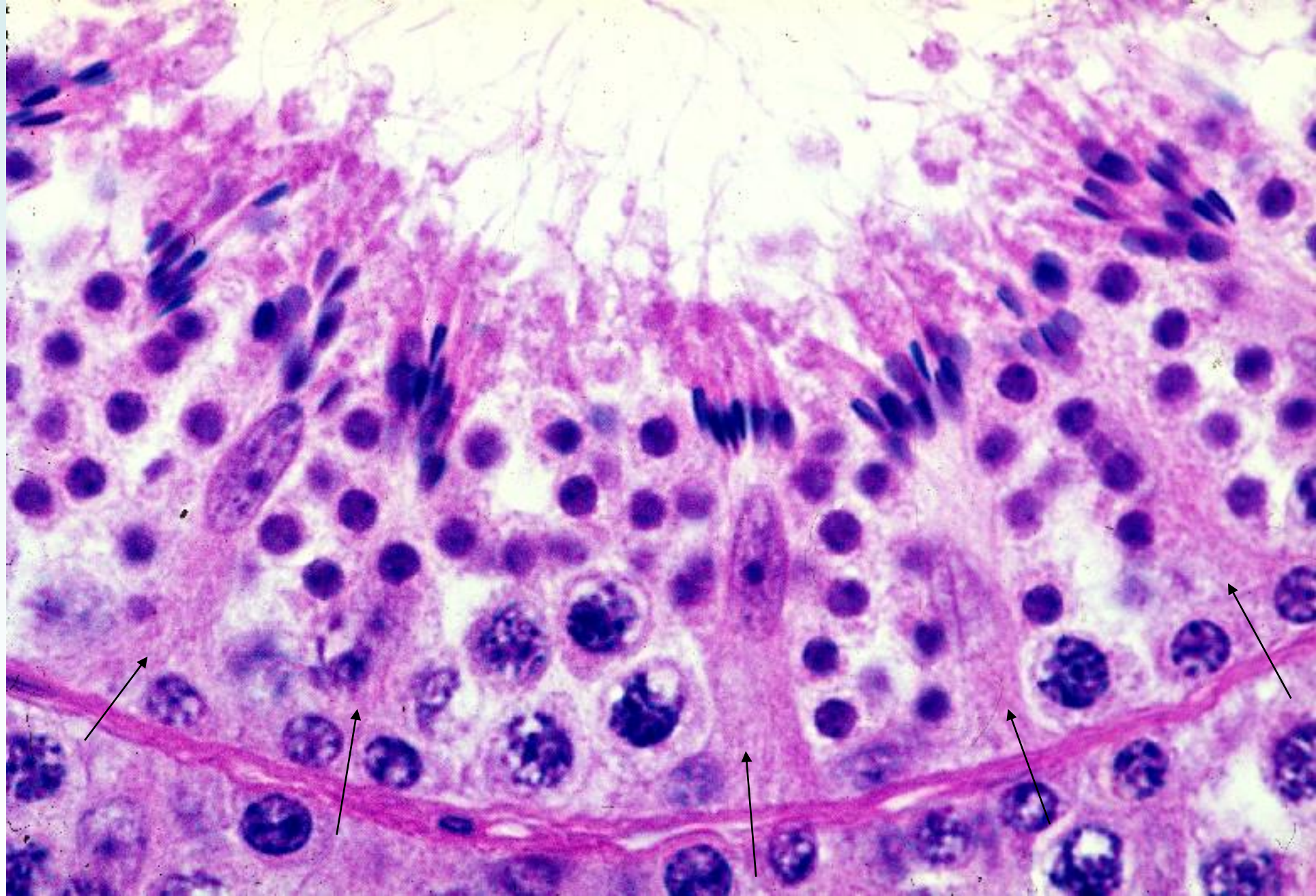
**16-11 Spermatogenesis 1. Spermatogonia and primary spermatocytes. Monkey, H-E stain, x 250.**





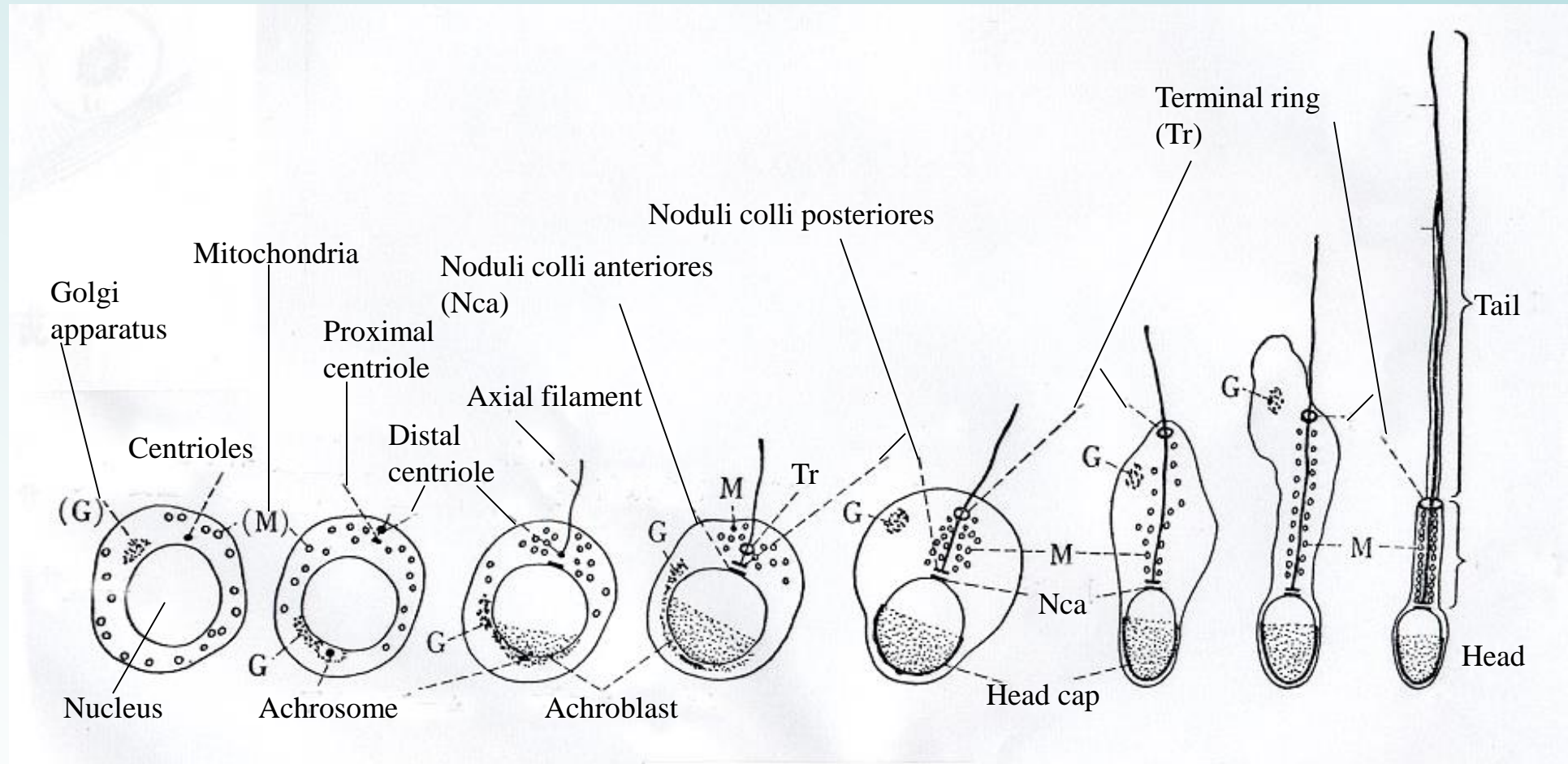
**16-12 Spermatogenesis 2. Spermatogonia and secondary spermatocytes. Monkey, H-E stain, x 250.**



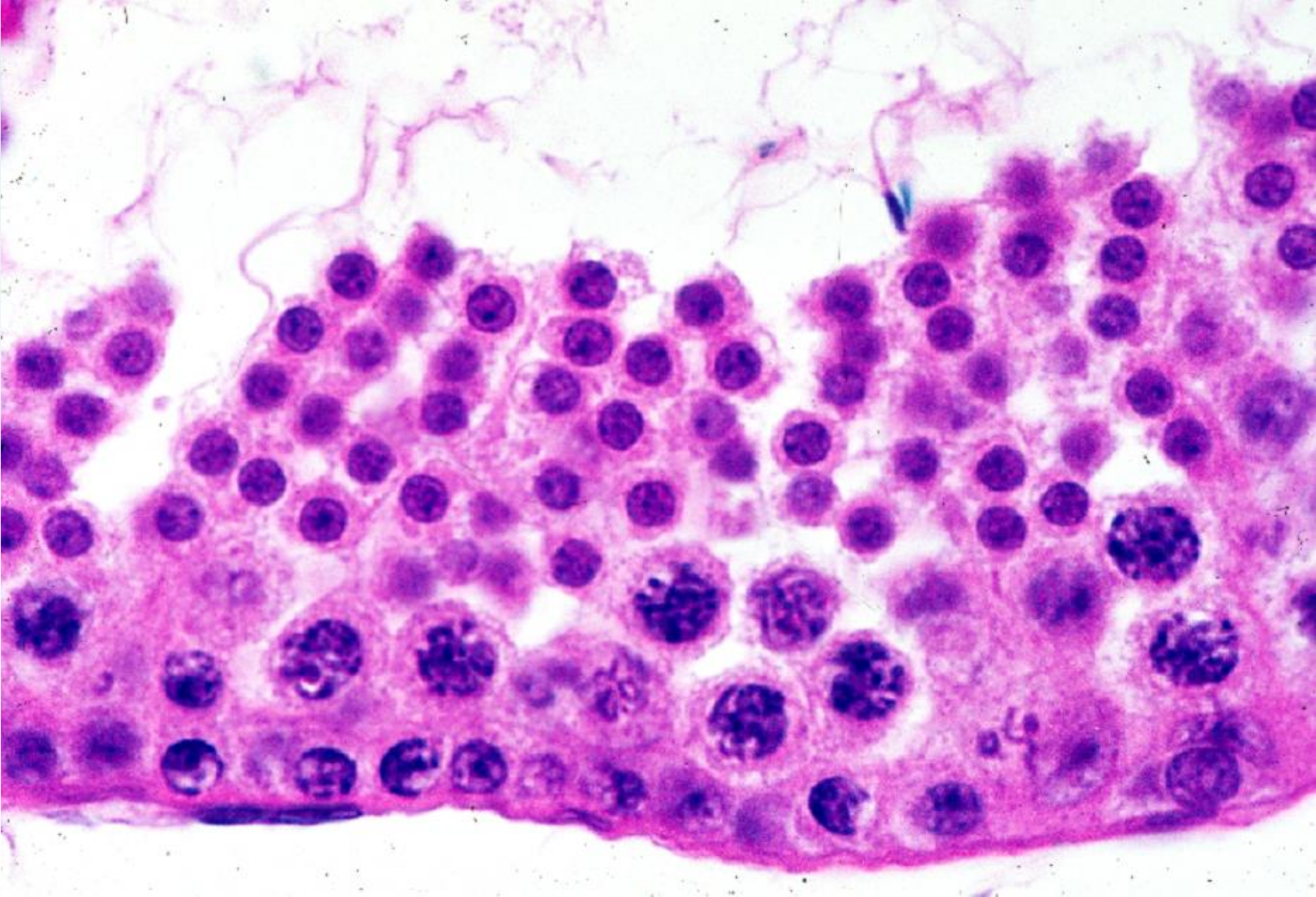


**16-13 Spermatogenesis 3. Spermatogonia and spermatids. Monkey, H-E stain, x 250.**



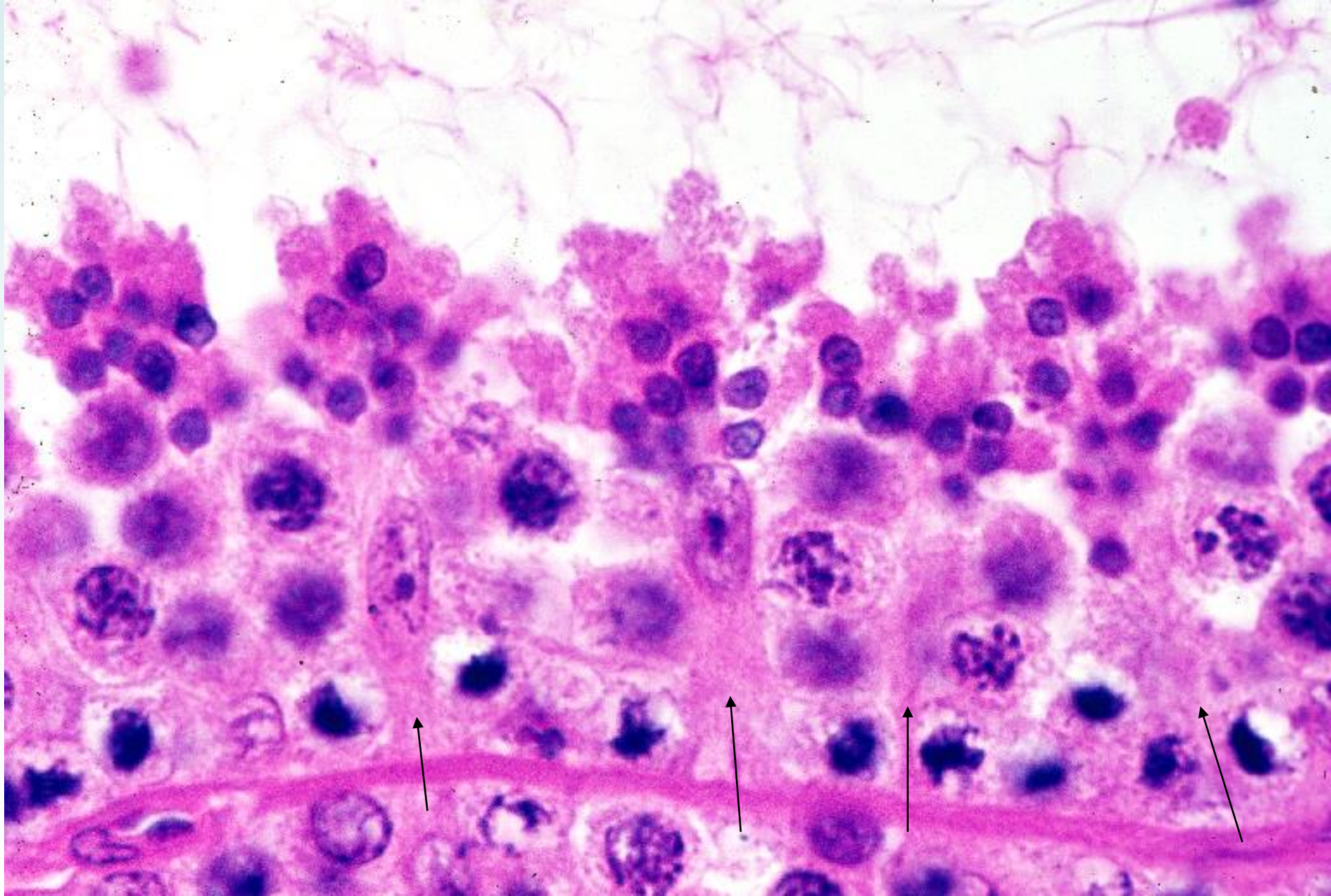


16-14 Scheme showing the spermiogenesis.



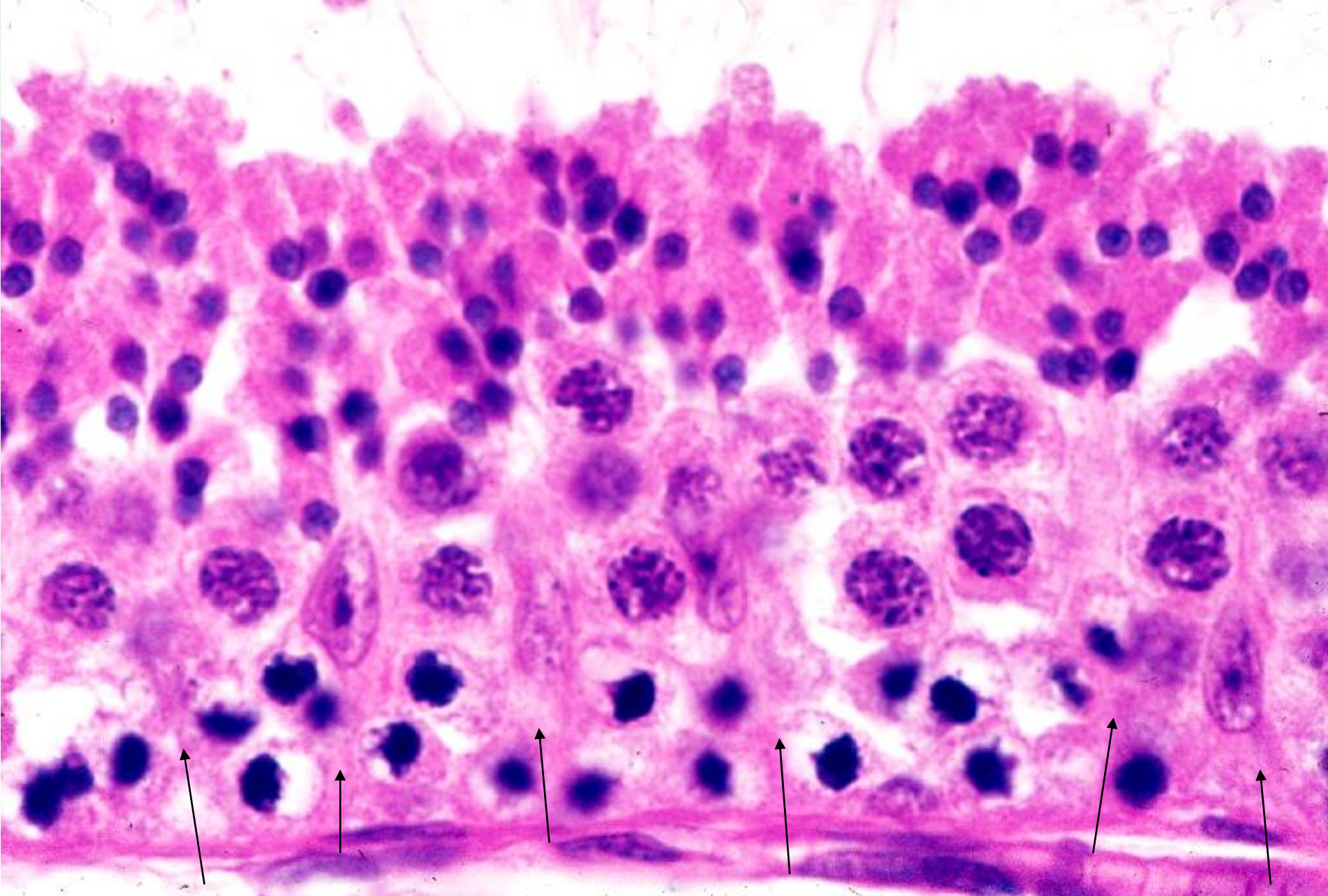
16-15 Spermiogenesis 1. Monkey, H-E stain, x 250.





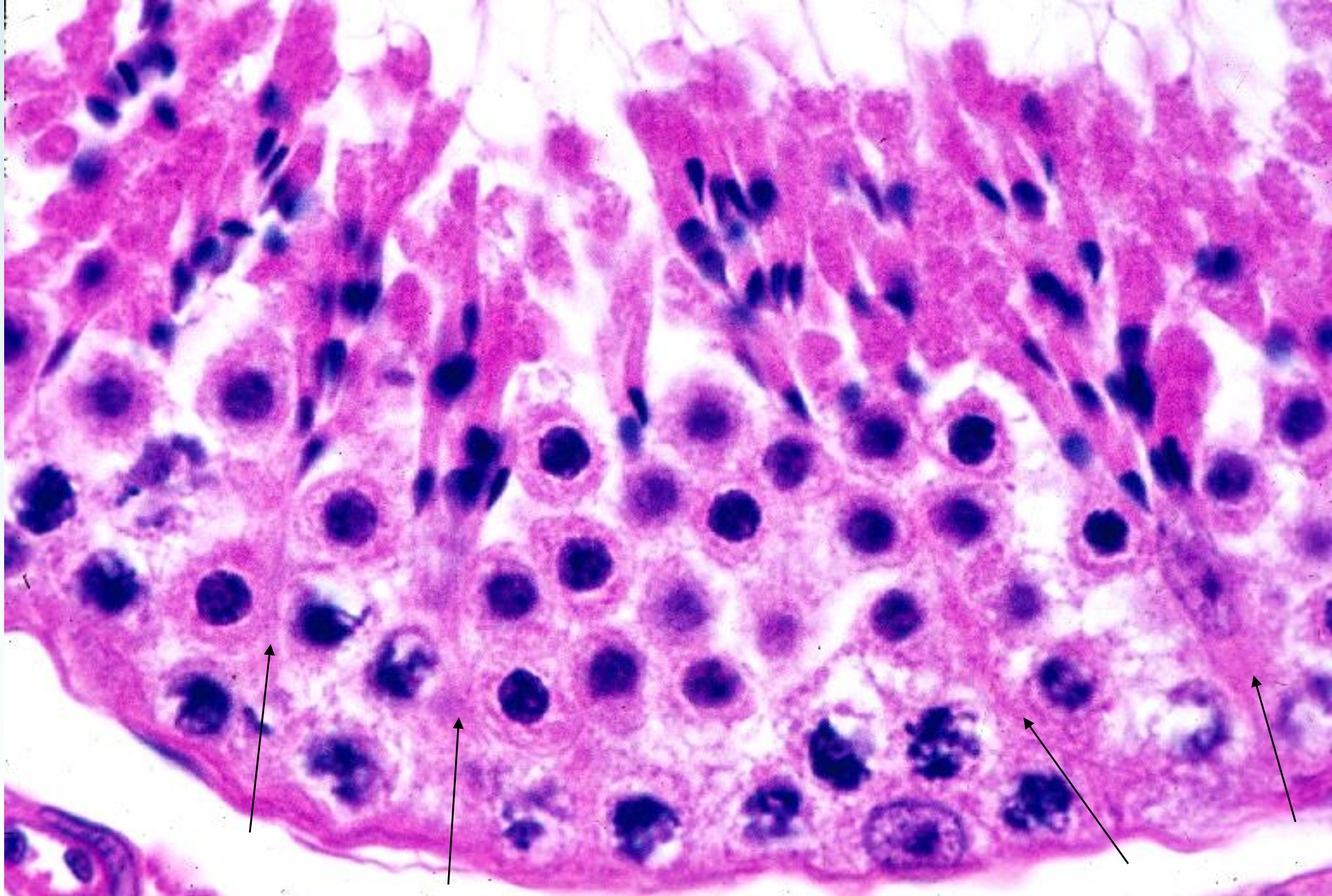
16-16 Spermiogenesis 2. Monkey, H-E stain, x 250.





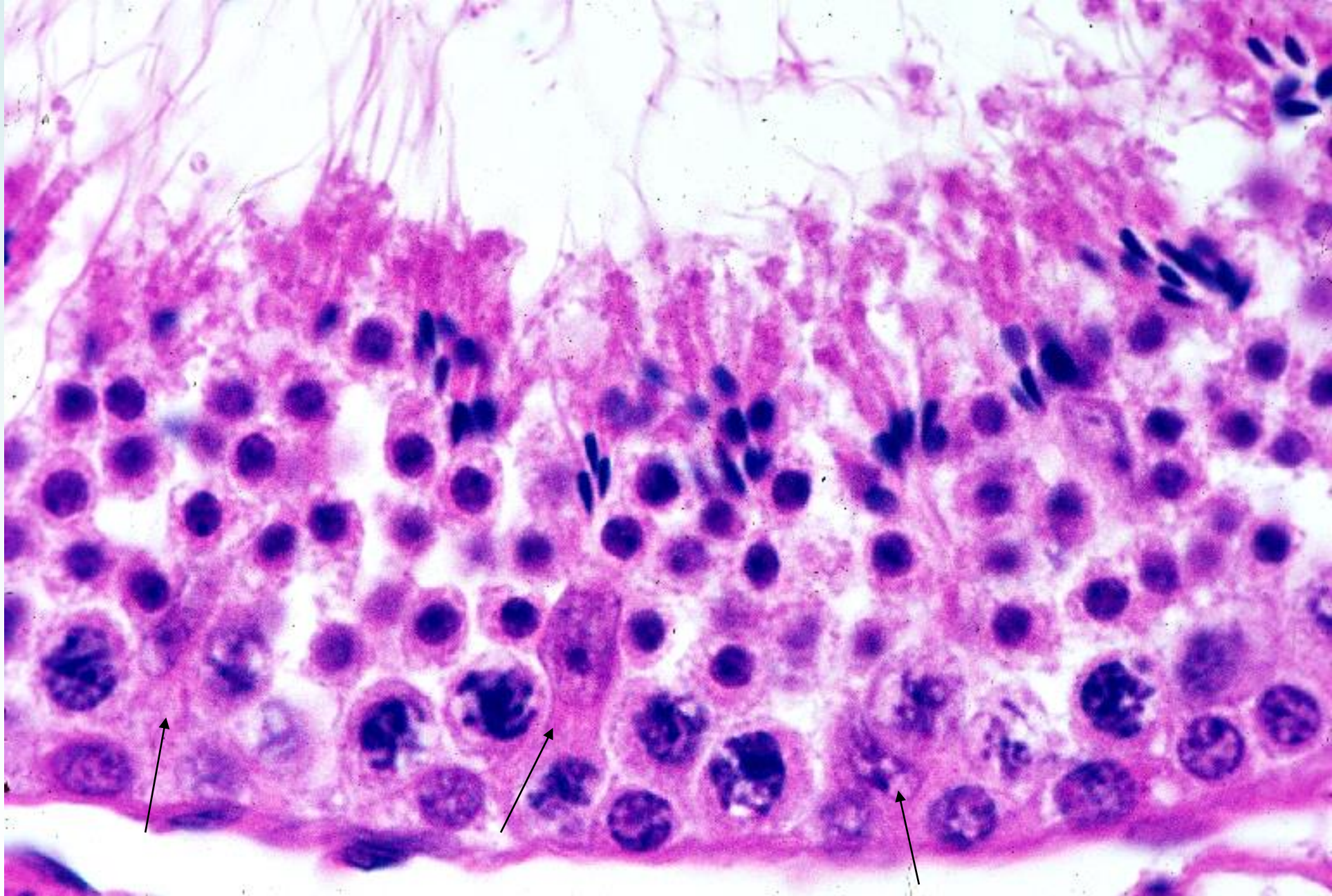
16-17 Spermiogenesis 3. Monkey, H-E stain, x 250.





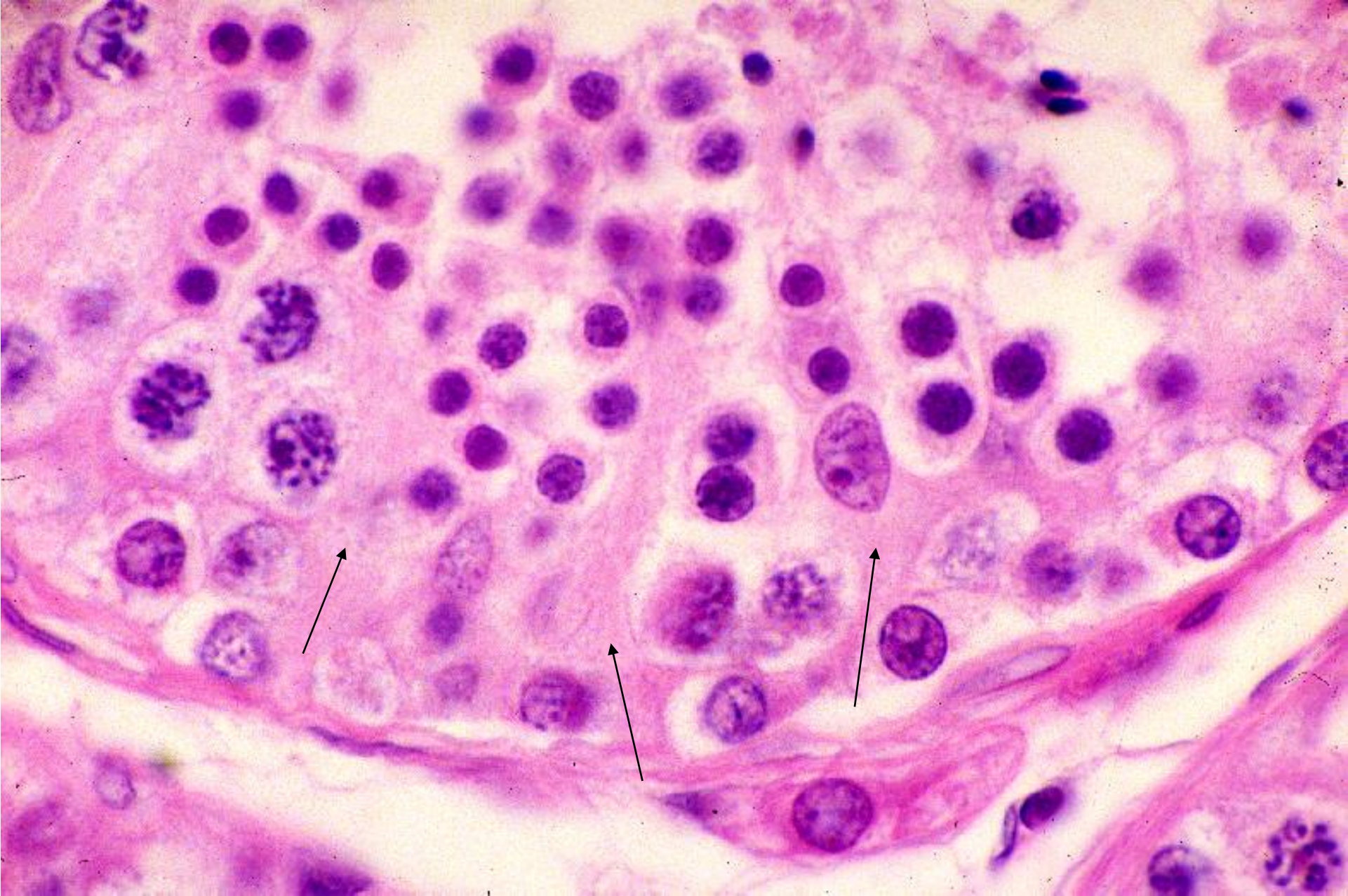
16-18 Spermiogenesis 4. Monkey, H-E stain, x 250.





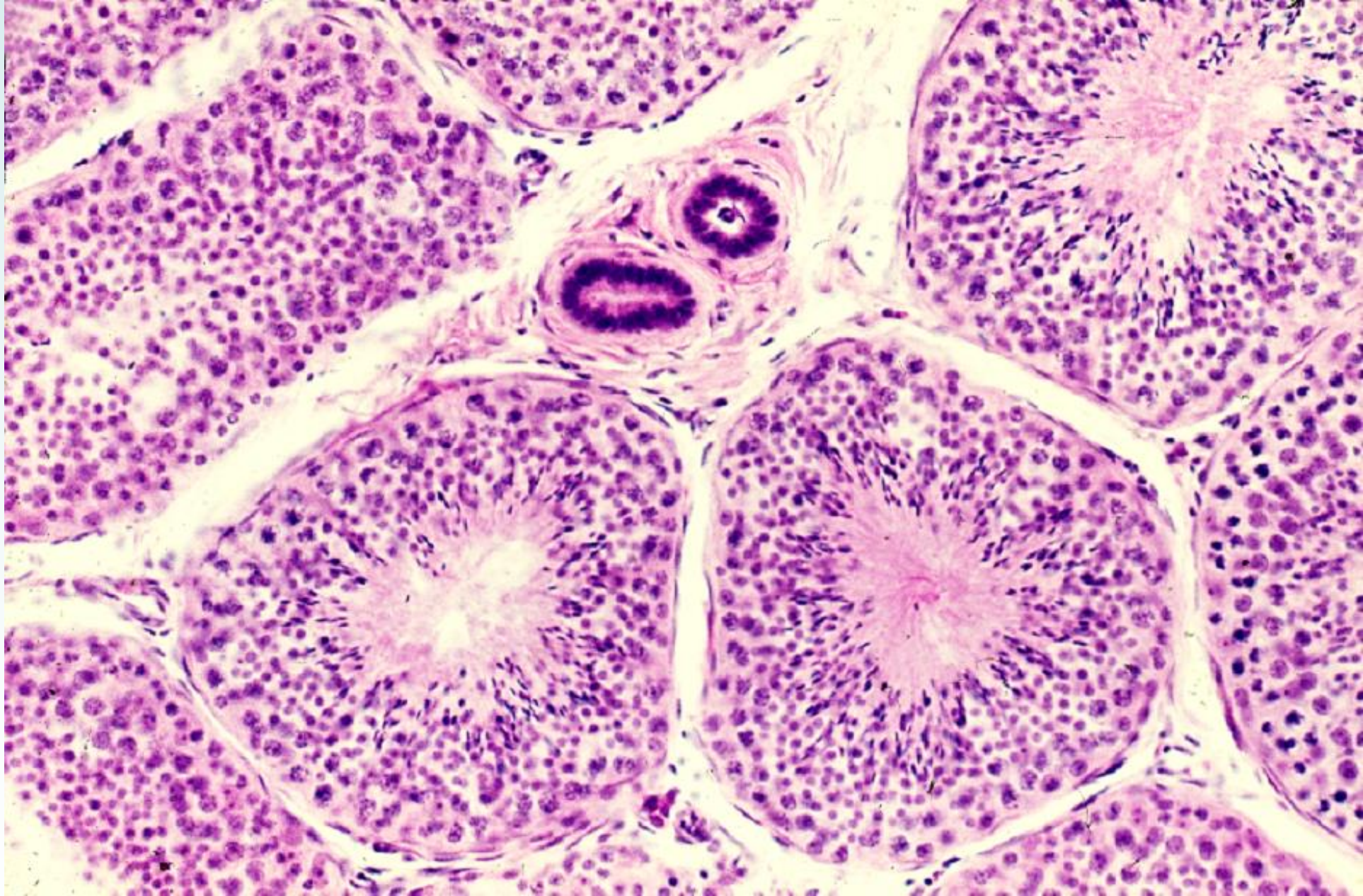
16-19 Spermiogenesis 5. Monkey, H-E stain, x 250.





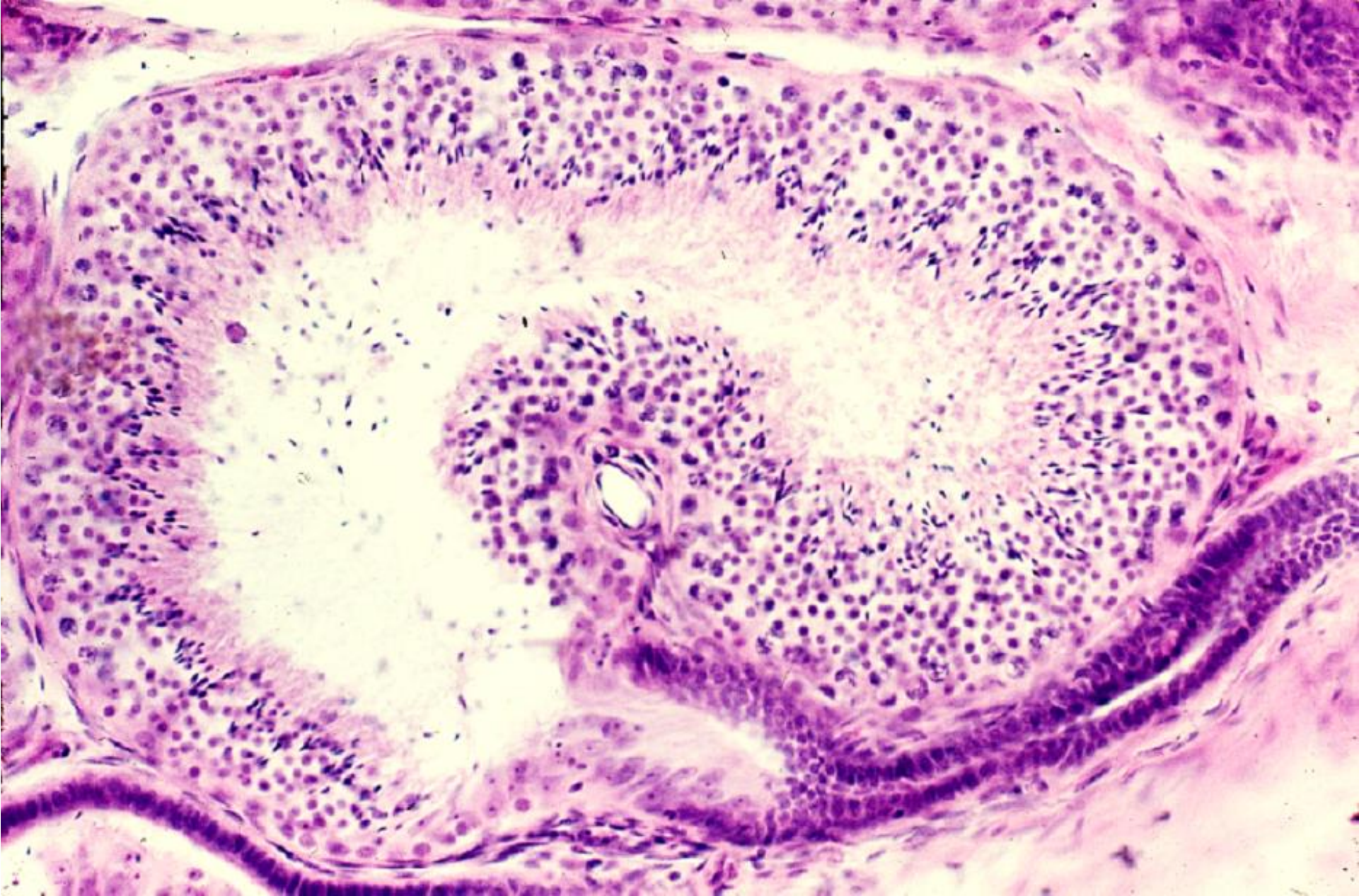
16-20 Spermatogenesis in the human testis. H-E stain, x 250.





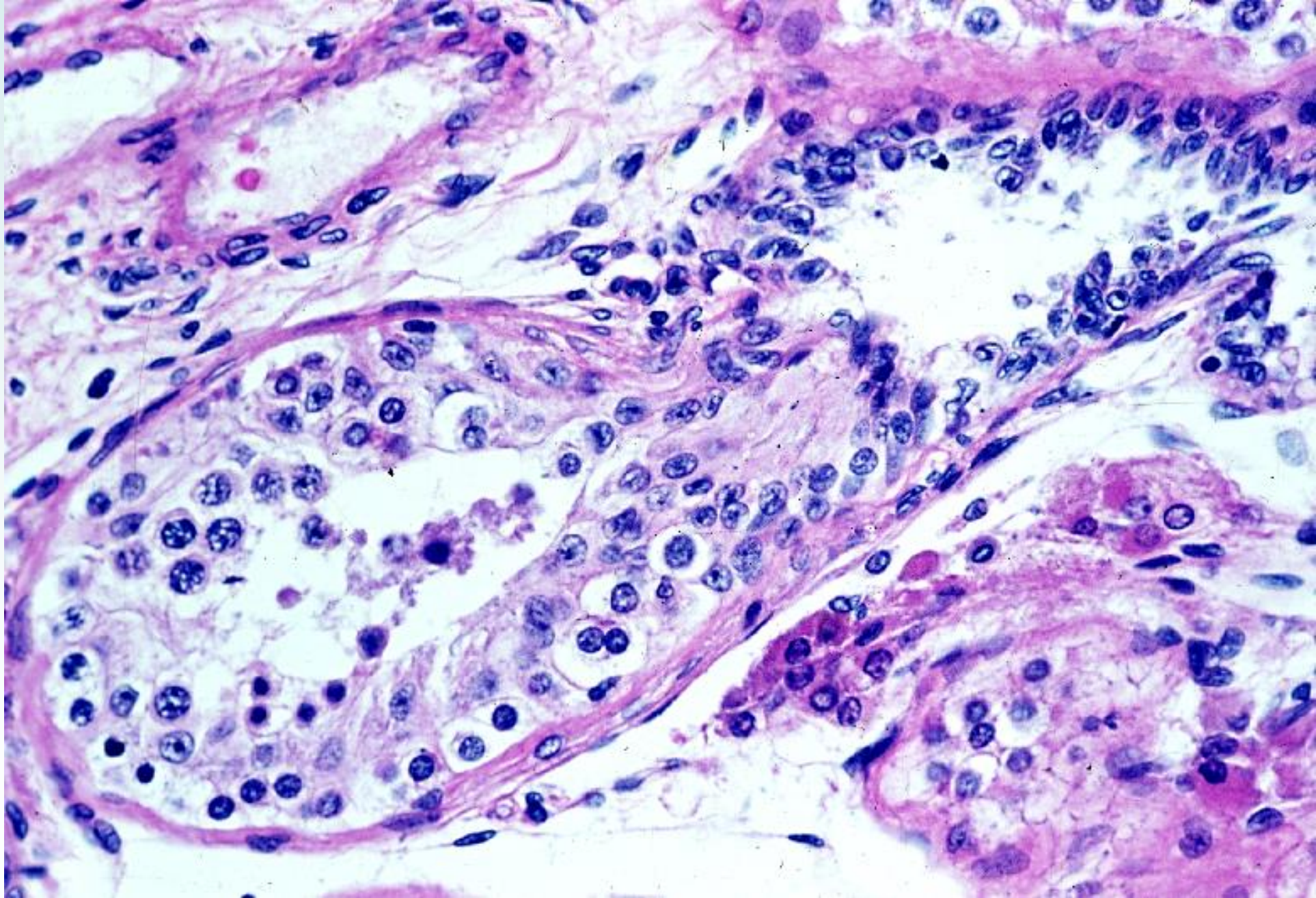
16-21 Tubuli seminiferi contorti et recti. Monkey, H-E stain, x 64.





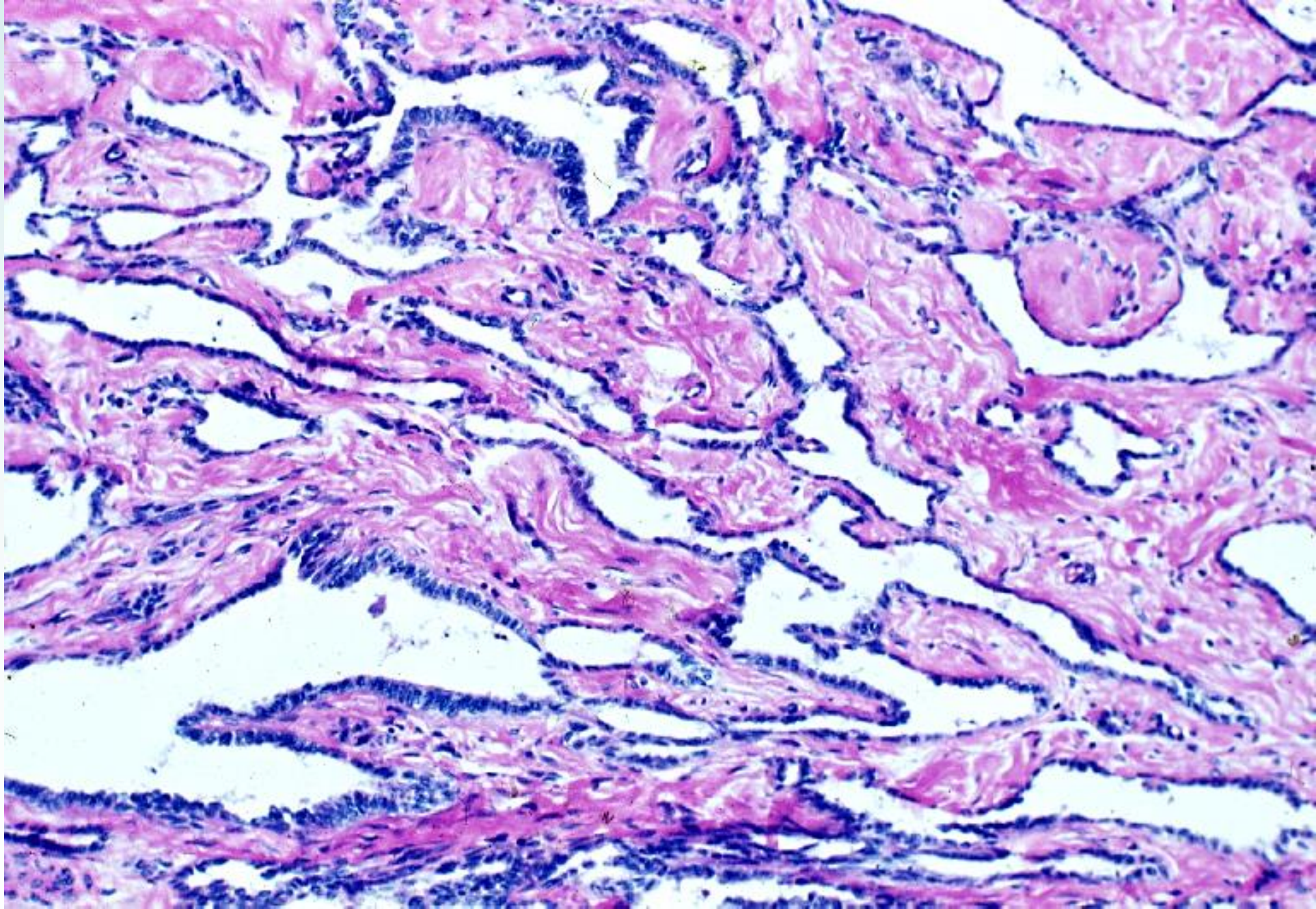
16-22 Transition from contortus to rectus tubule 1. Monkey, H-E stain, x 64.





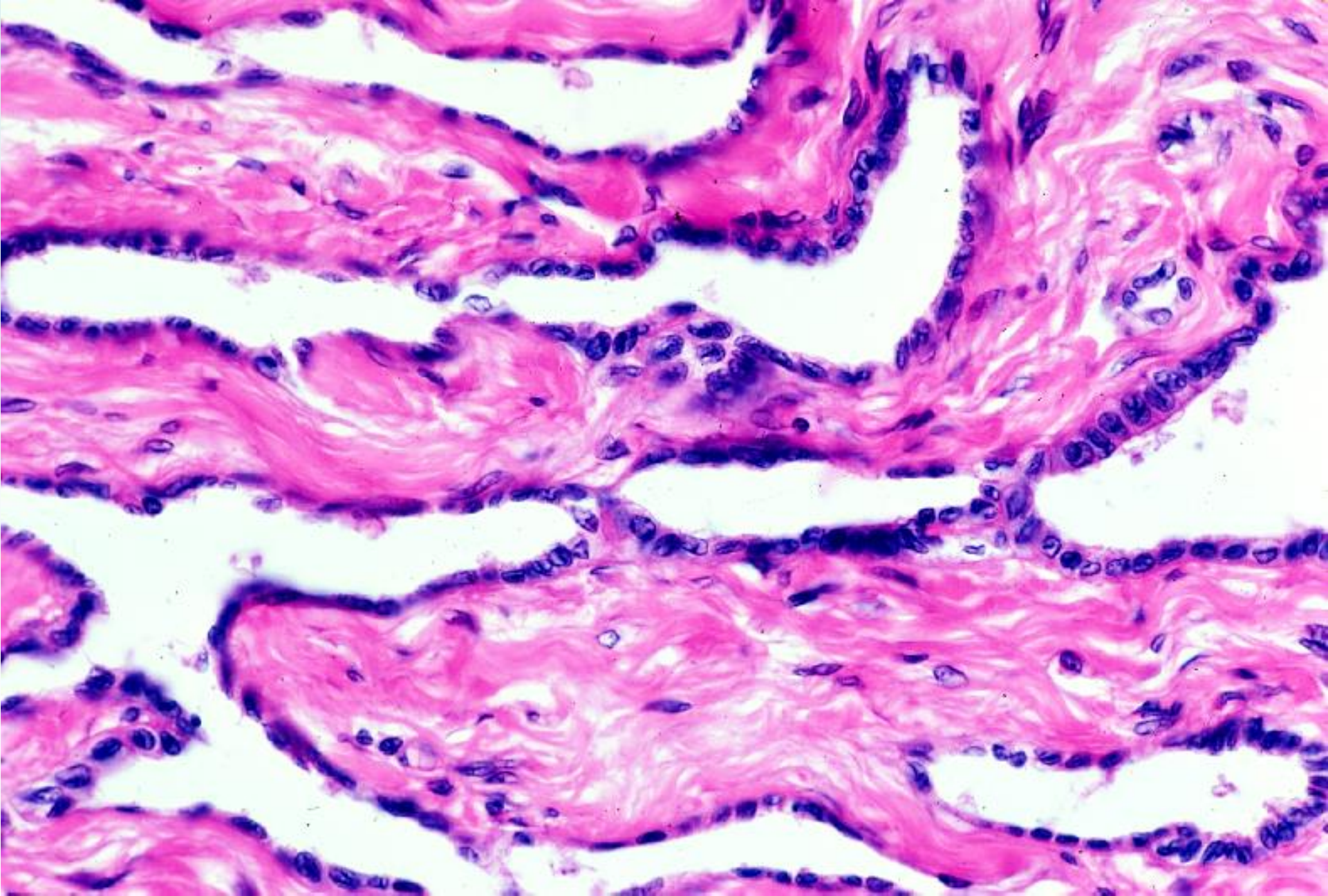
16-23 Transition from contortus to rectus tubule 2. Human, H-E stain, x 100.





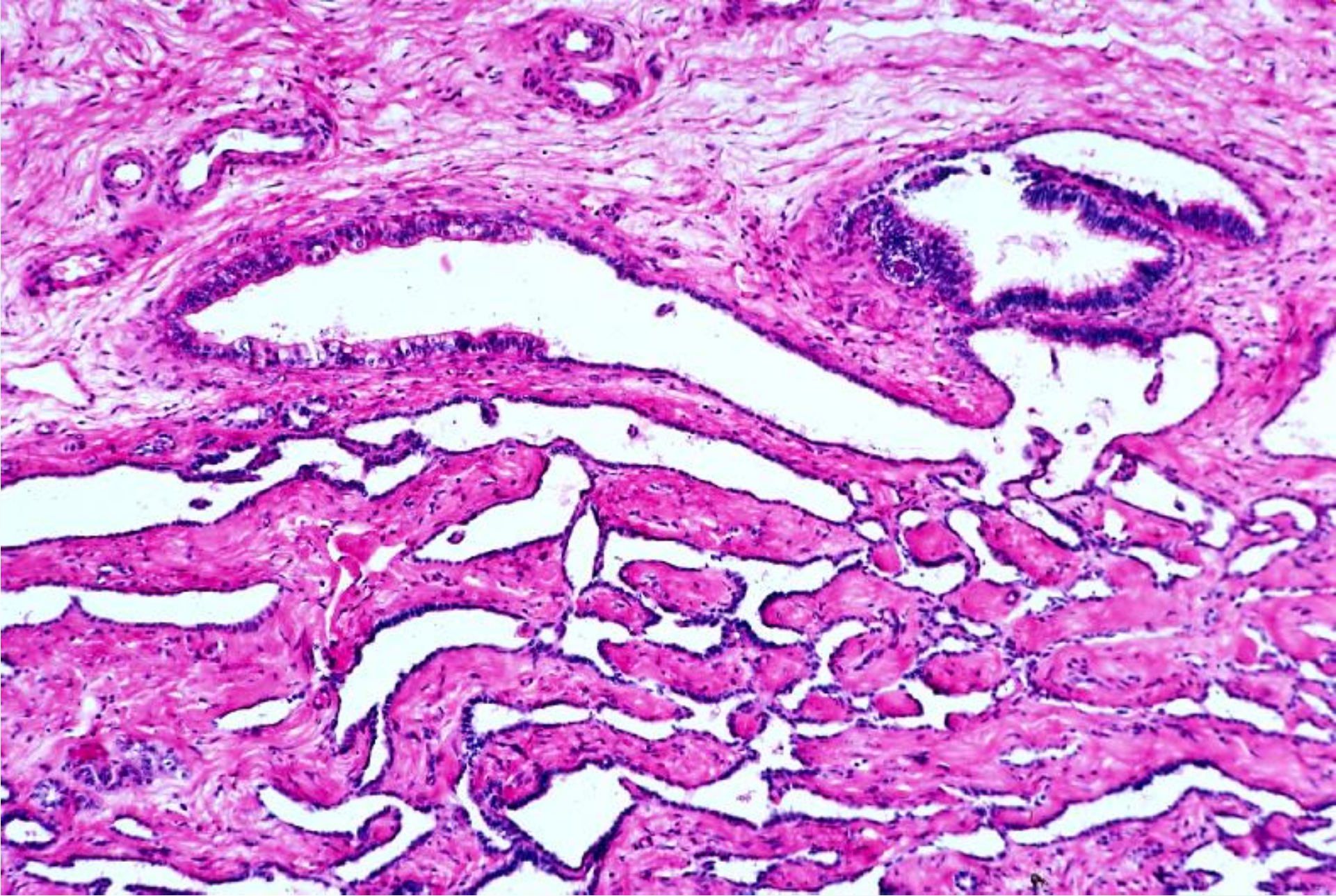
16-24 Rete testis 1. Human, H-E stain, x 40.





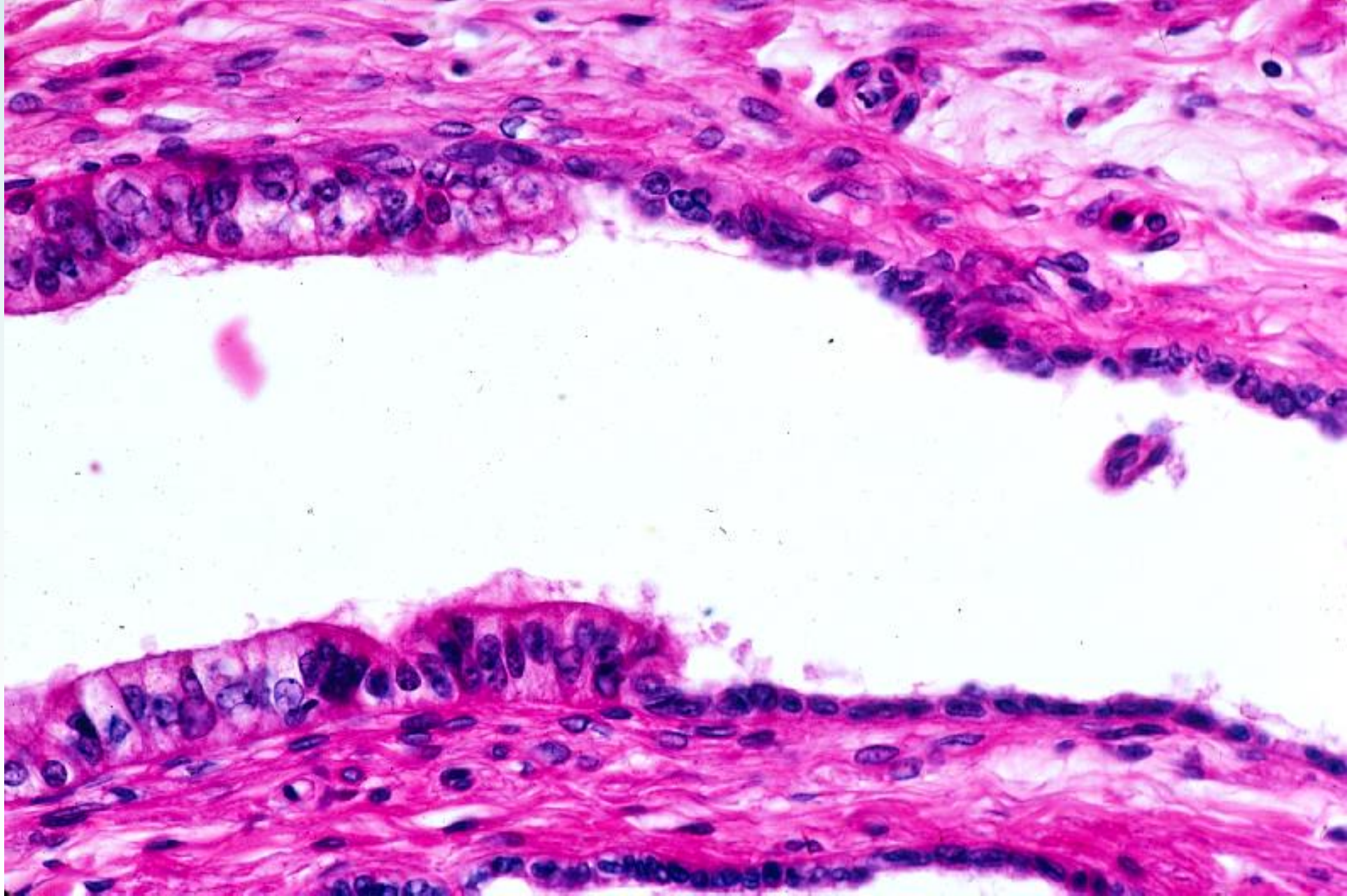
16-25 Rete testis 2. Human, H-E stain, x 100.





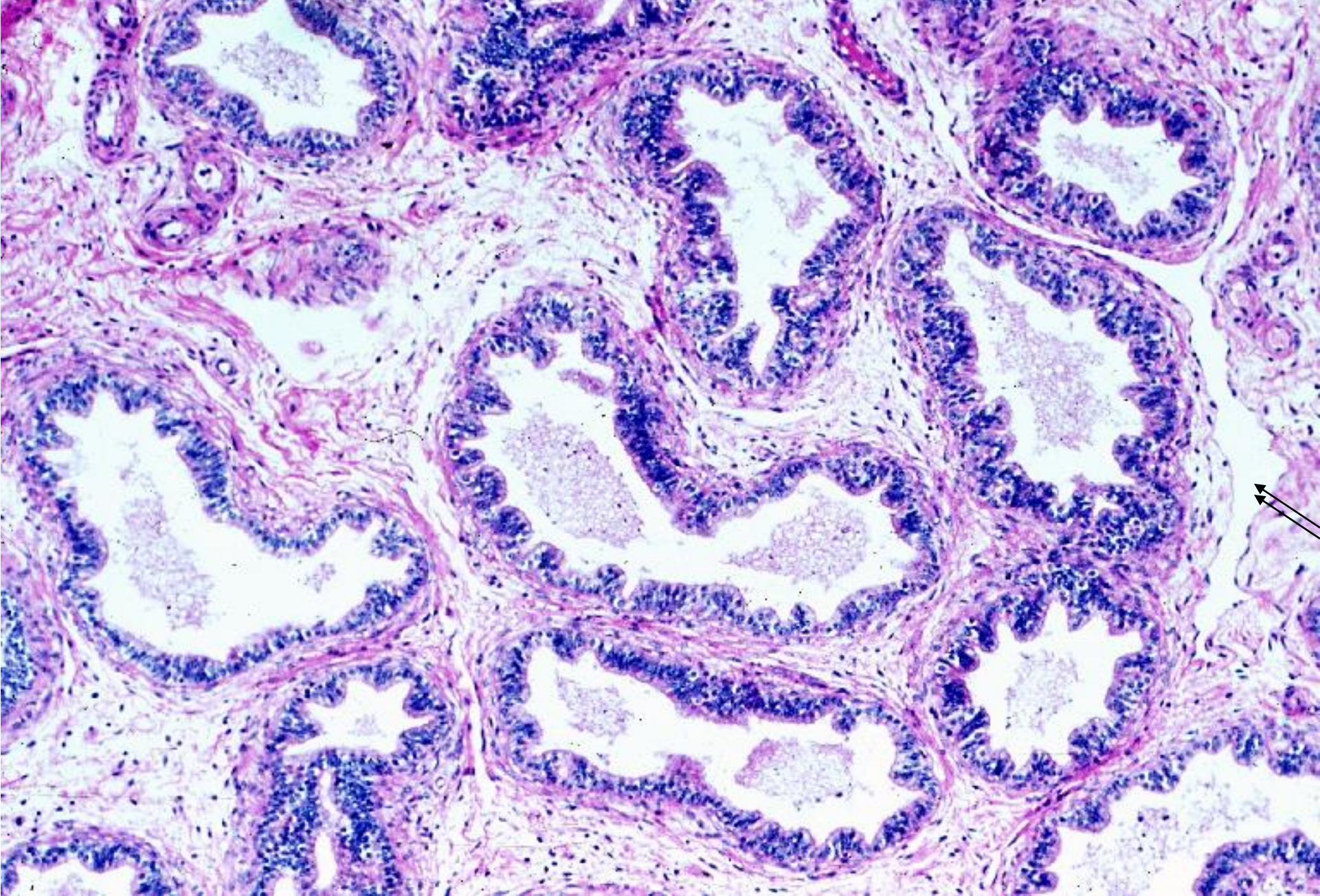
16-26 Transition from rete testis to efferent ductulus 1. Human, H-E stain, x 25.





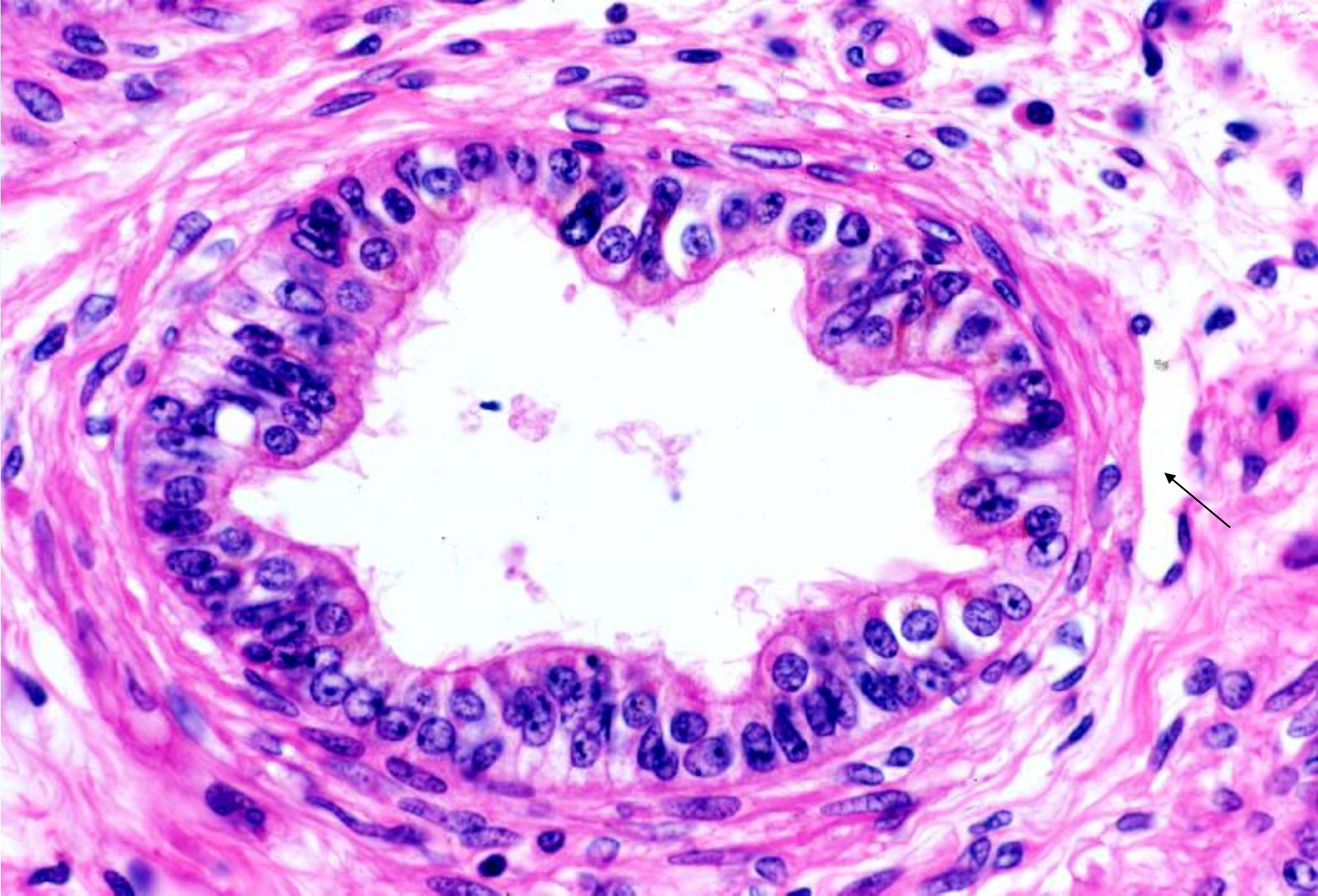
**16-27 Transition from rete testis to efferent ductulus 2. Human, H-E stain, x 100.**





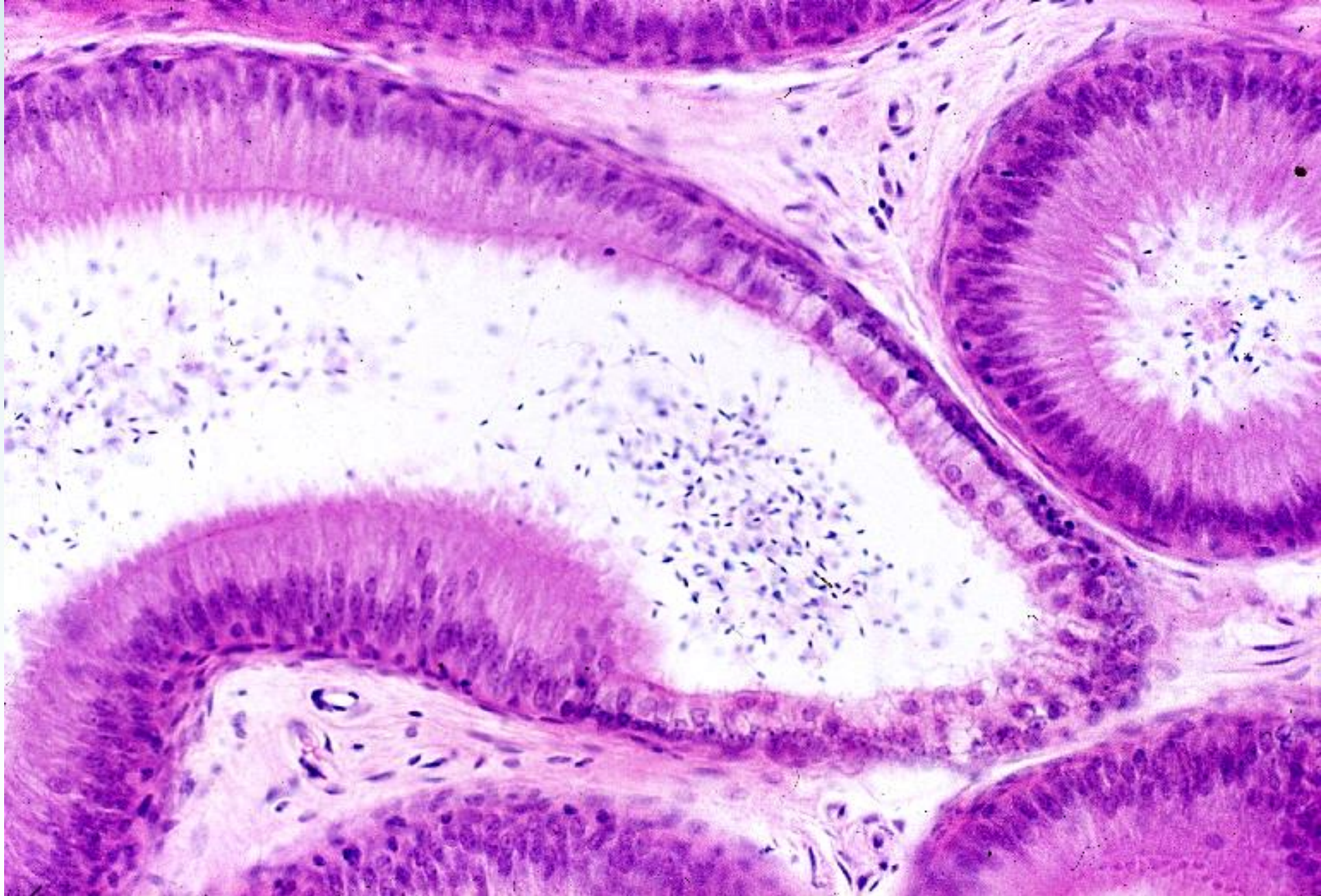
16-28 Ductuli efferentes testis 1. Human, H-E stain, x 64.





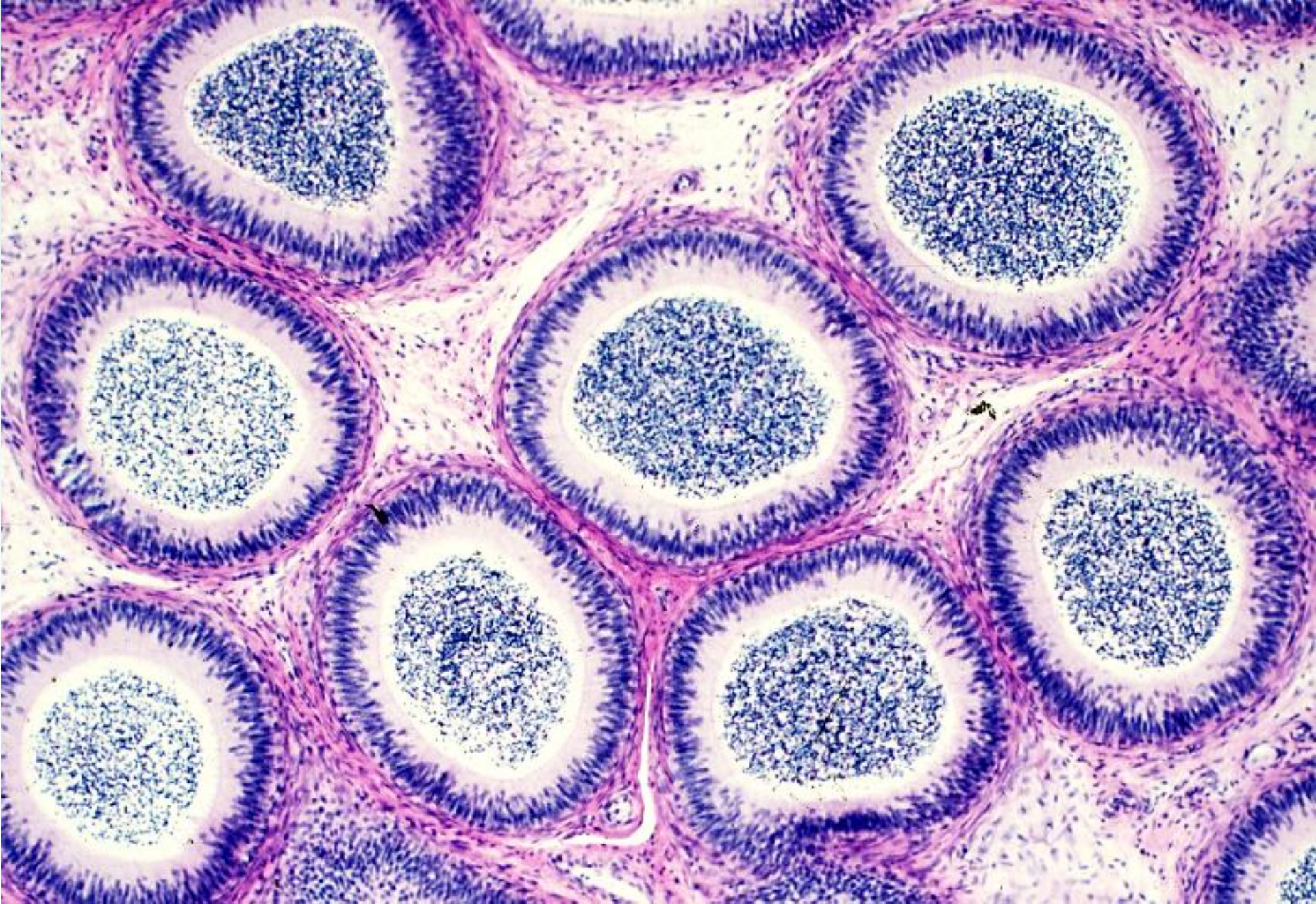16-29 Ductulus efferens testis 2. Human H-E stain, x 160.





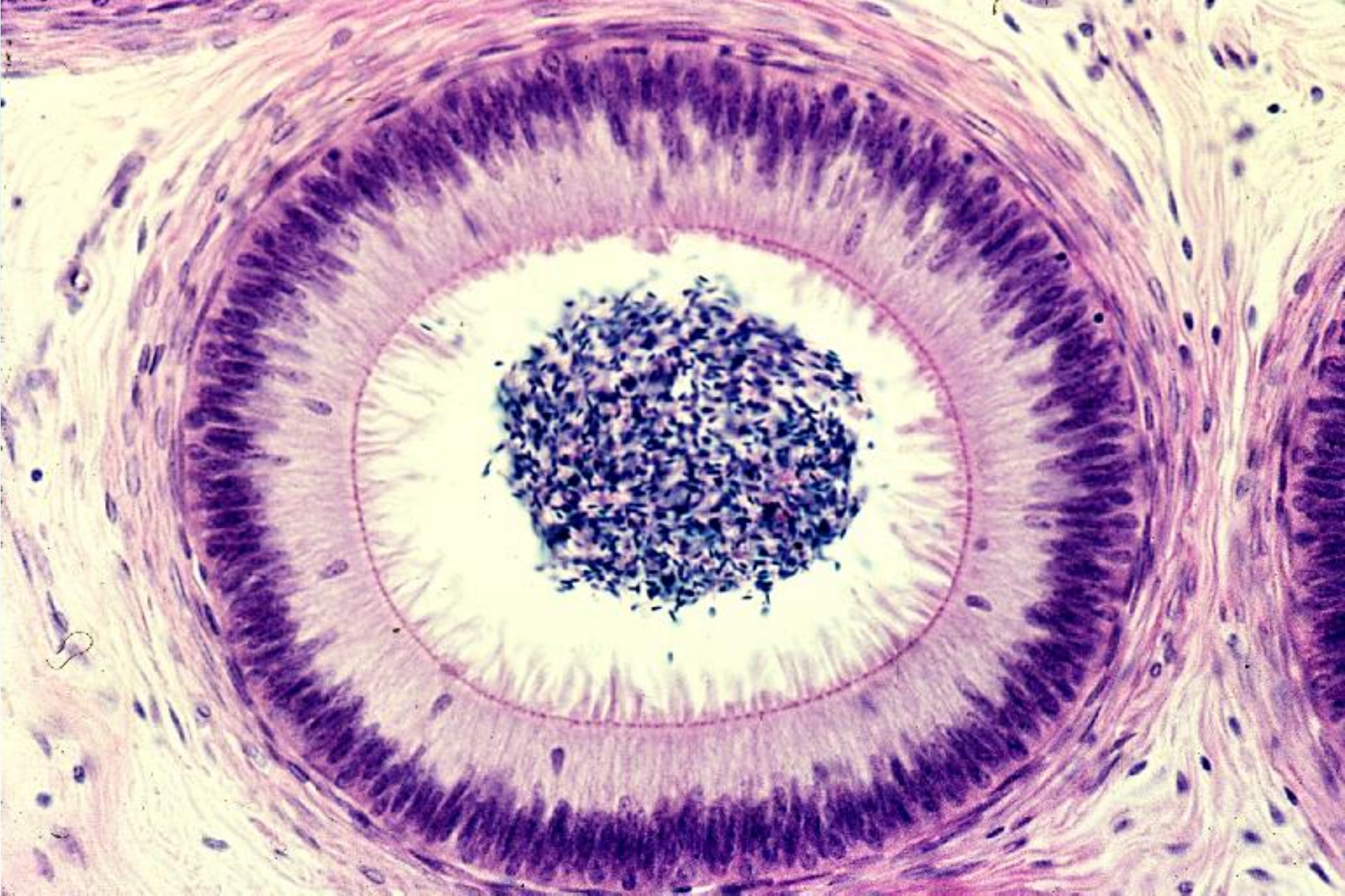
**16-30 Transition from the ductulus efferens to the ductus epididymidis. Monkey, H-E stain, x 64.**





16-31 Ductus epididymidis 1. Human, H-E stain, x 25.





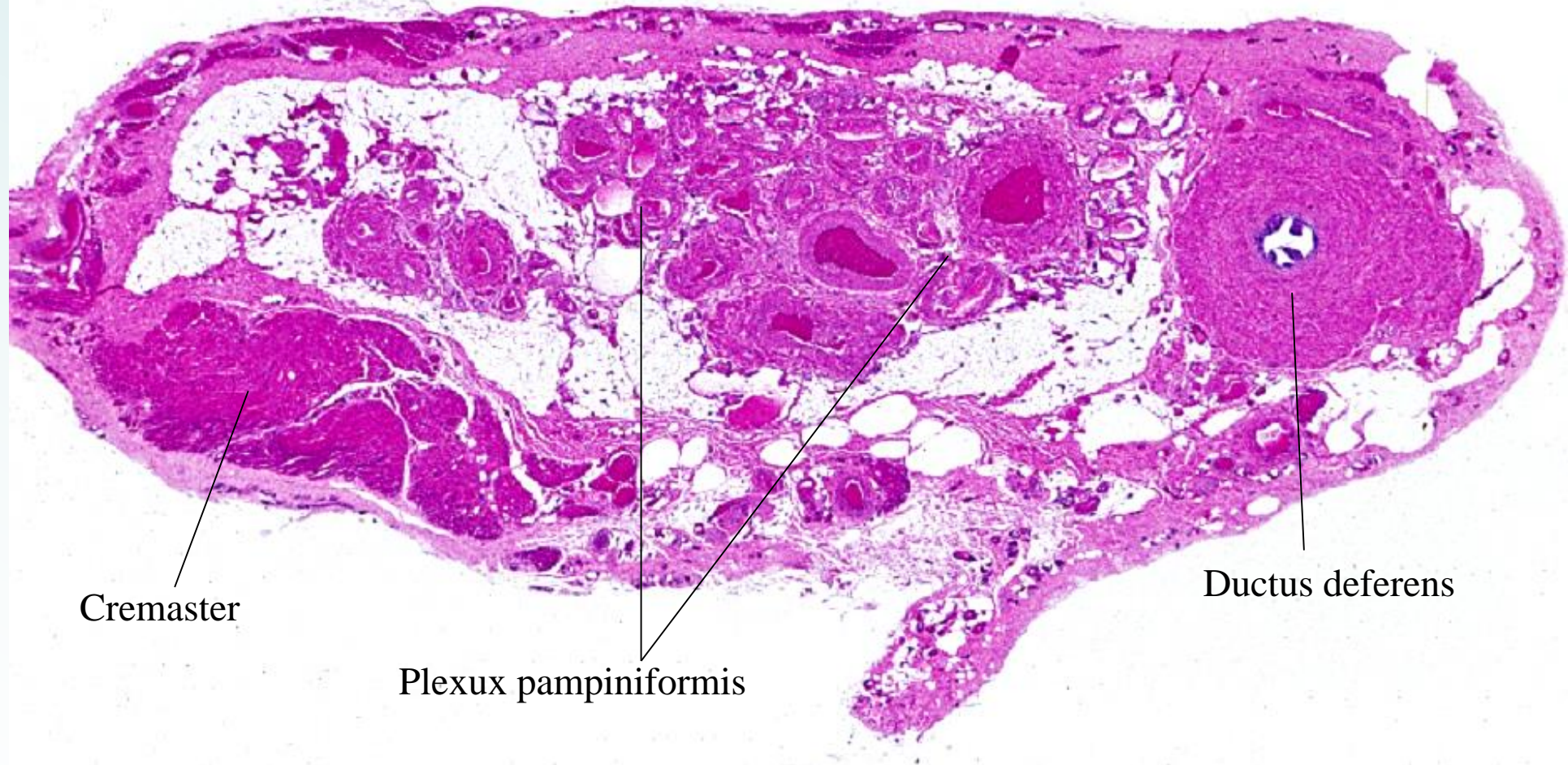
16-32 Ductus epididymidis 2. Monkey, H-E stain, x 64.



# 16-002

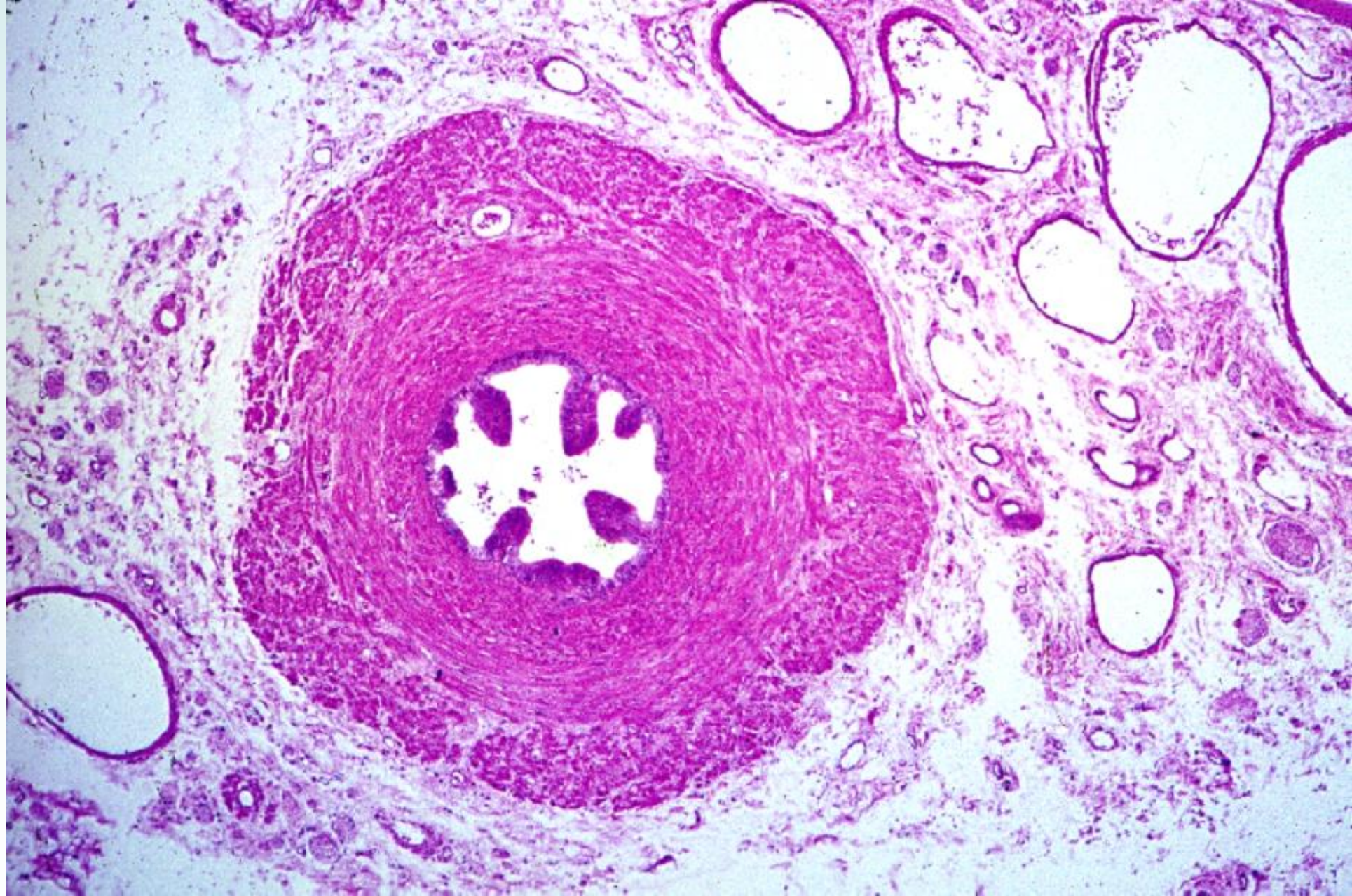## Spermatic cord, Seminal vesicle, Prostata and Penis





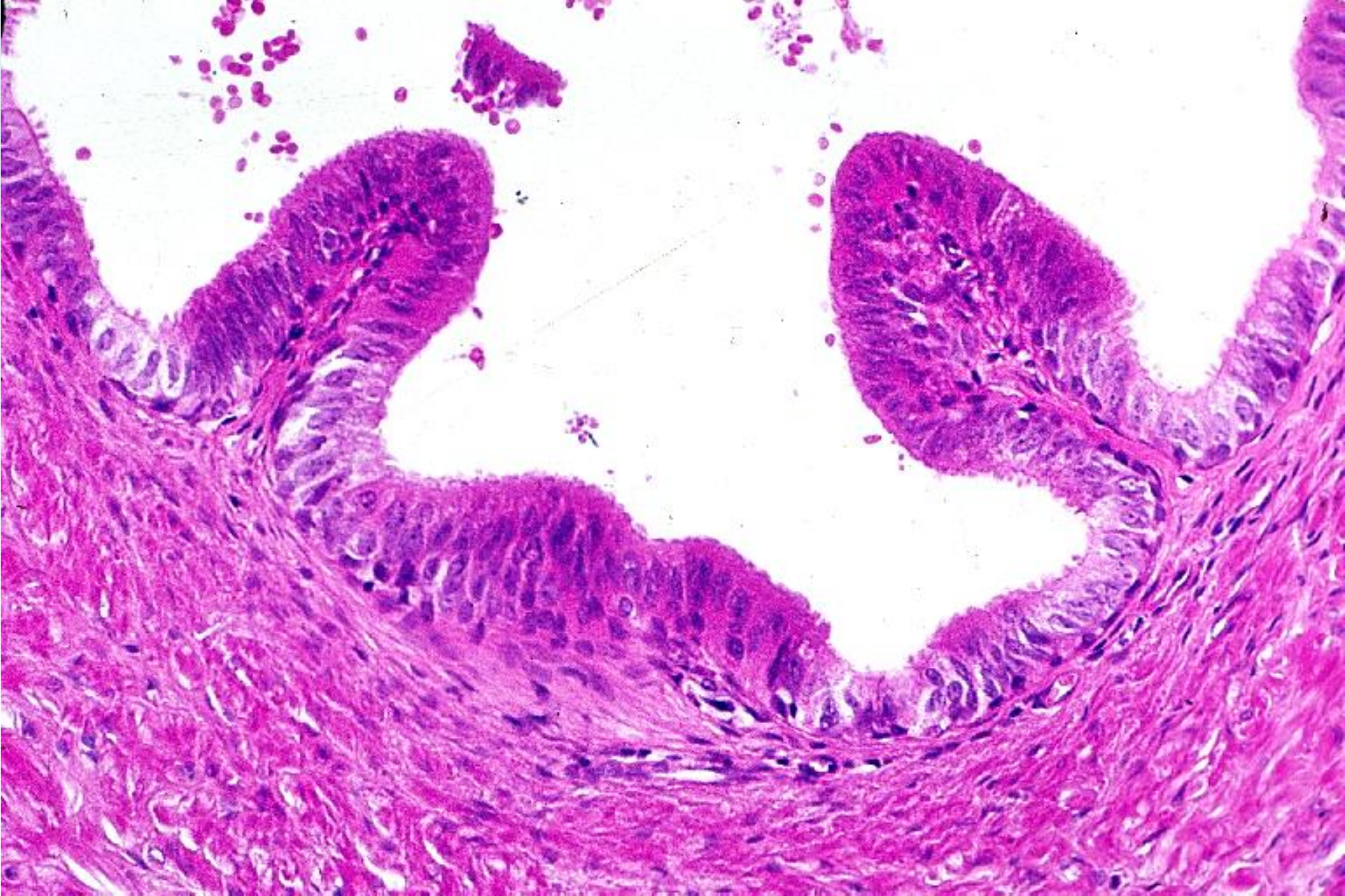
**16-33 Funiculus spermaticus. Transverse section. Human, H-E stain, x 2.4.**





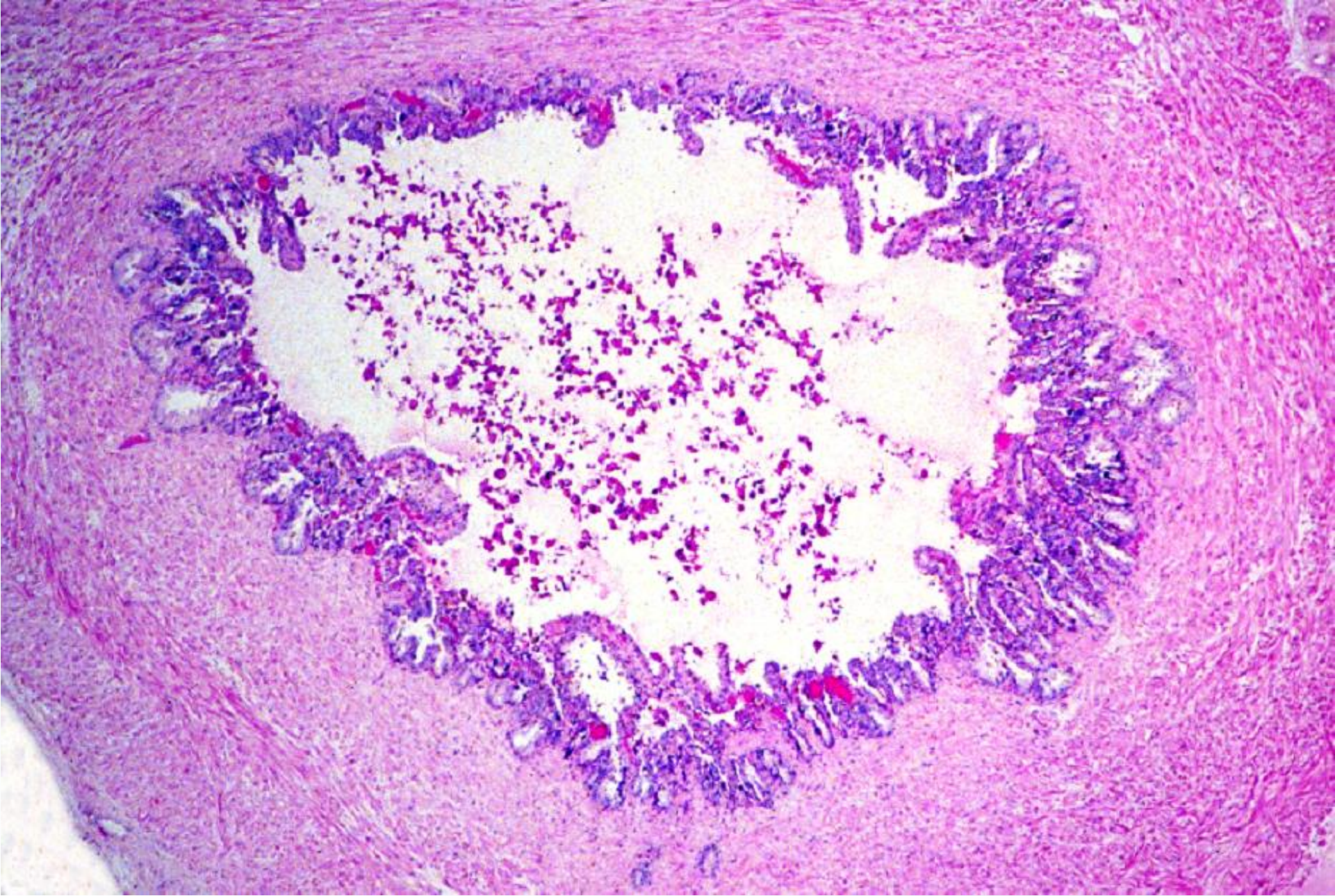
16-34 Ductus deferens, transverse section. Human, H-E stain, x 10.





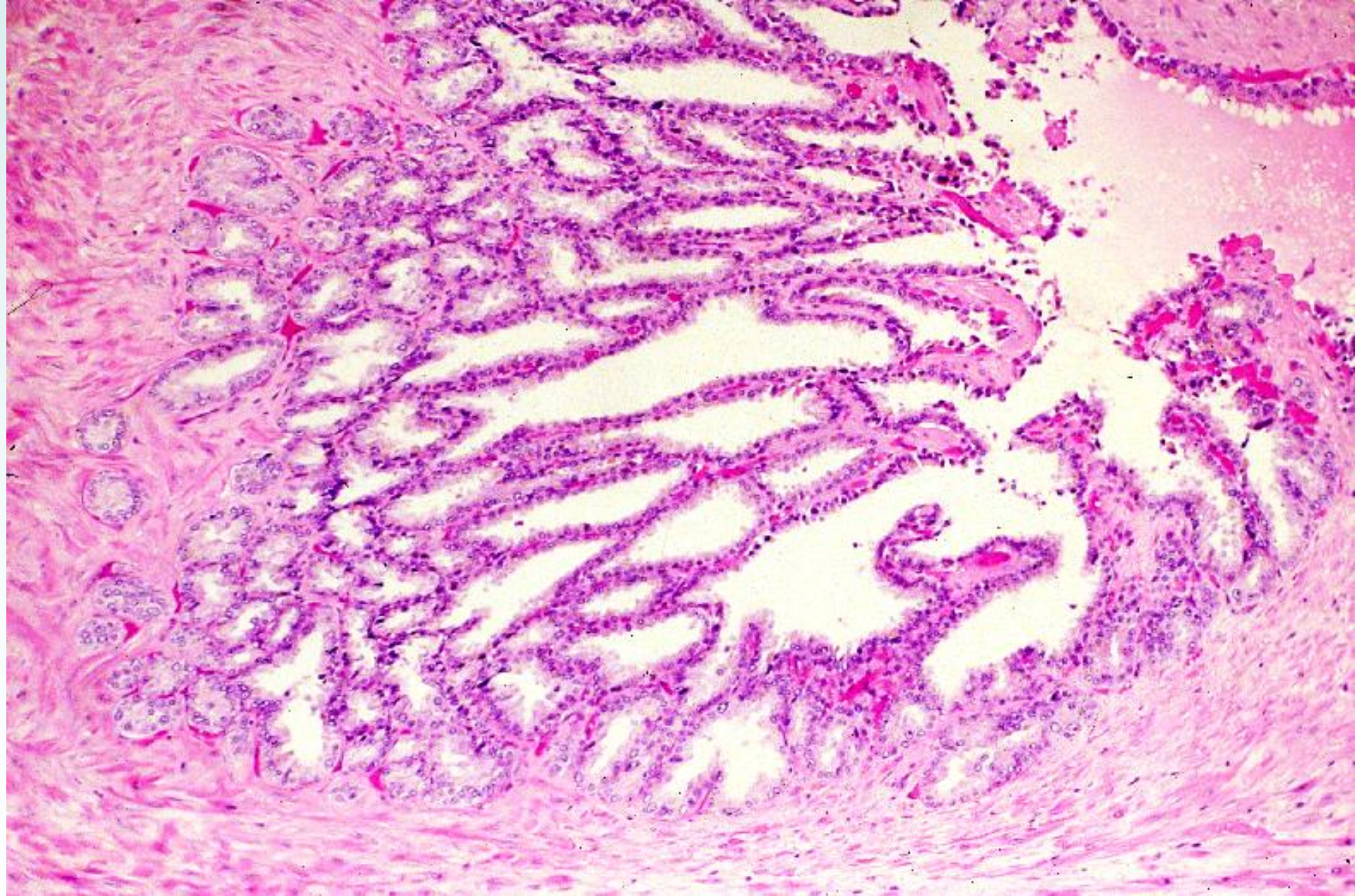
16-35 Epithelium of ductus deferens. Human, H-E stain, x 64.





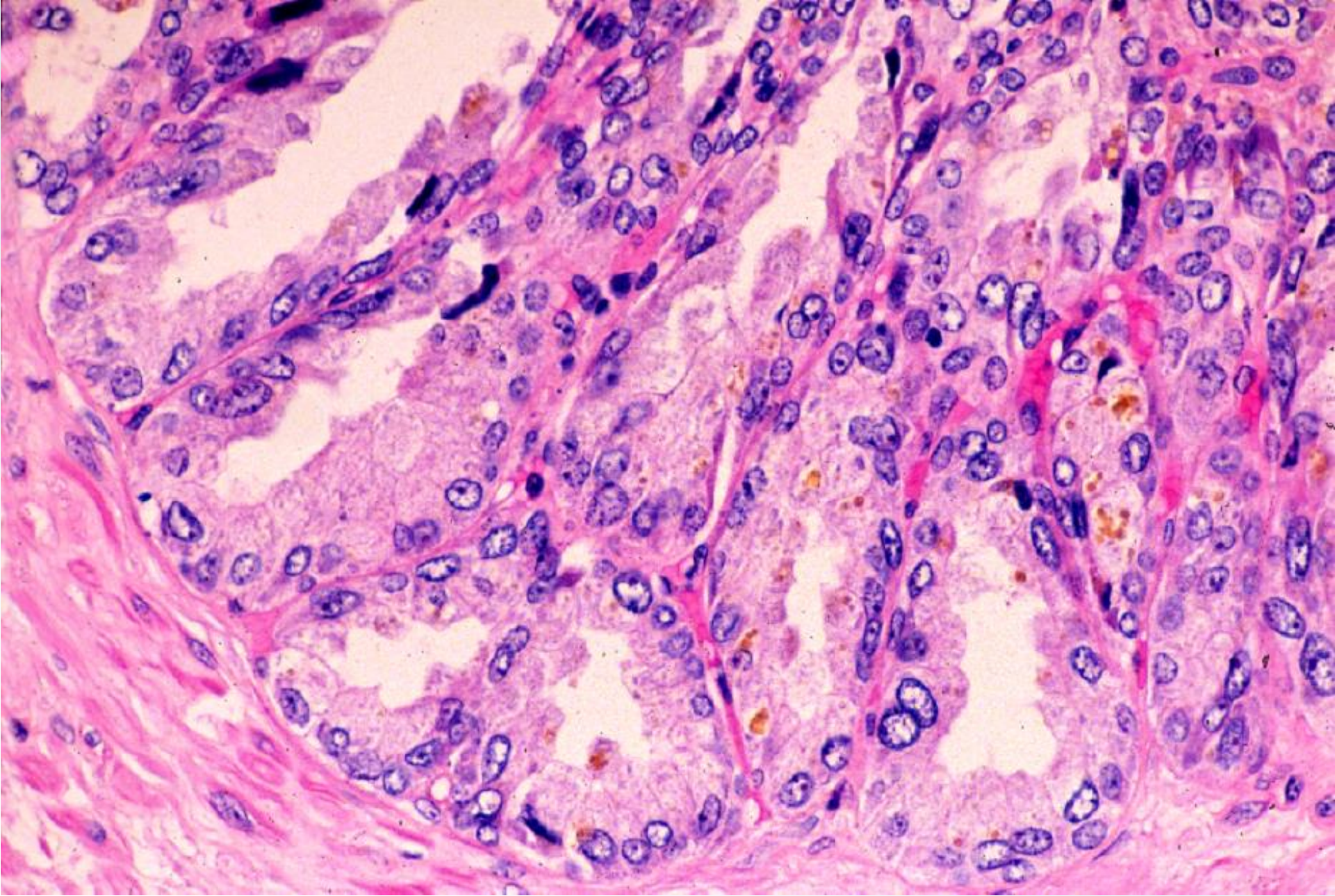
16-36 Seminal vesicle 1. Transverse section. Human, H-E stain, x 10.





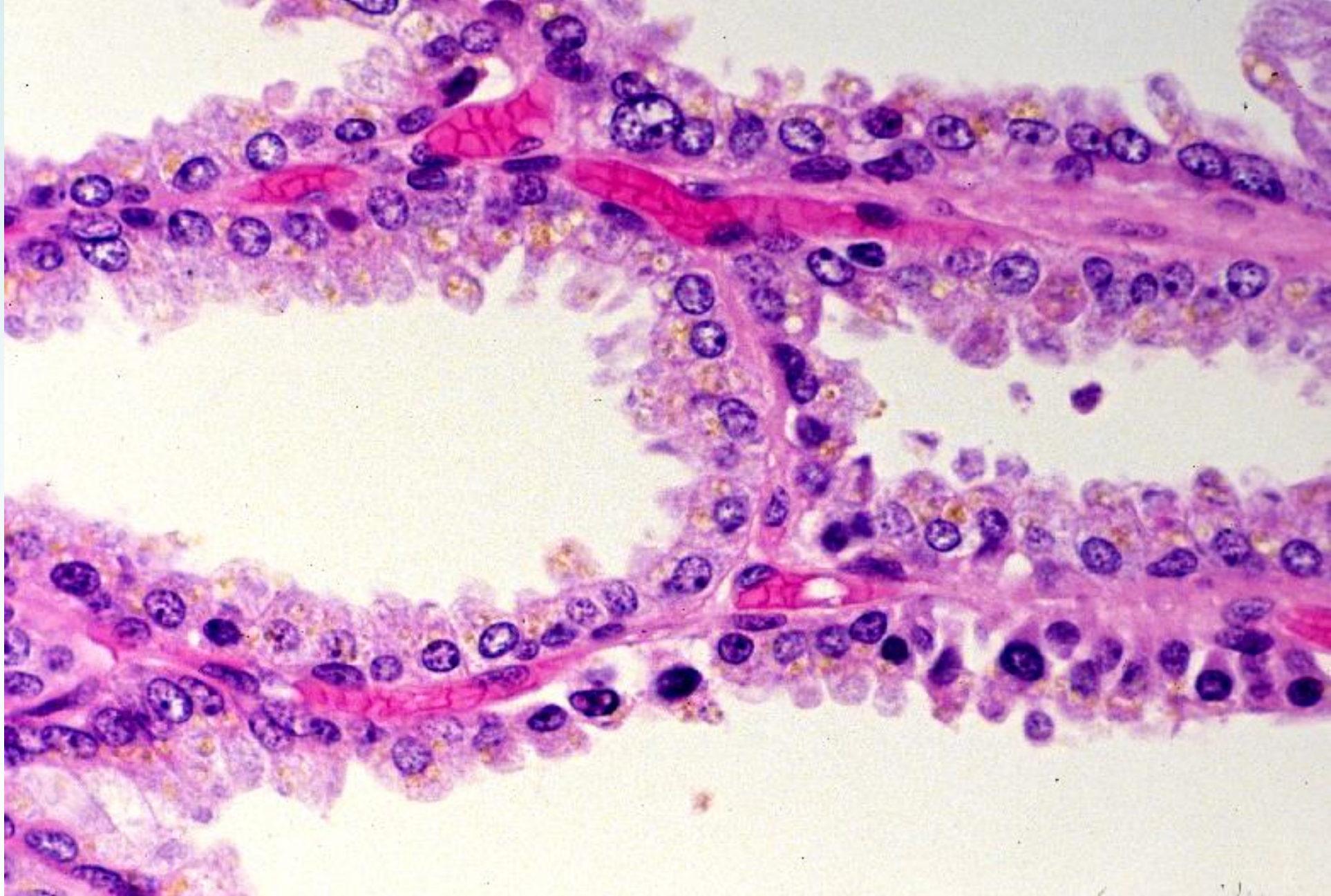
16-37 Seminal vesicle 2. Human, H-E stain, x 25.





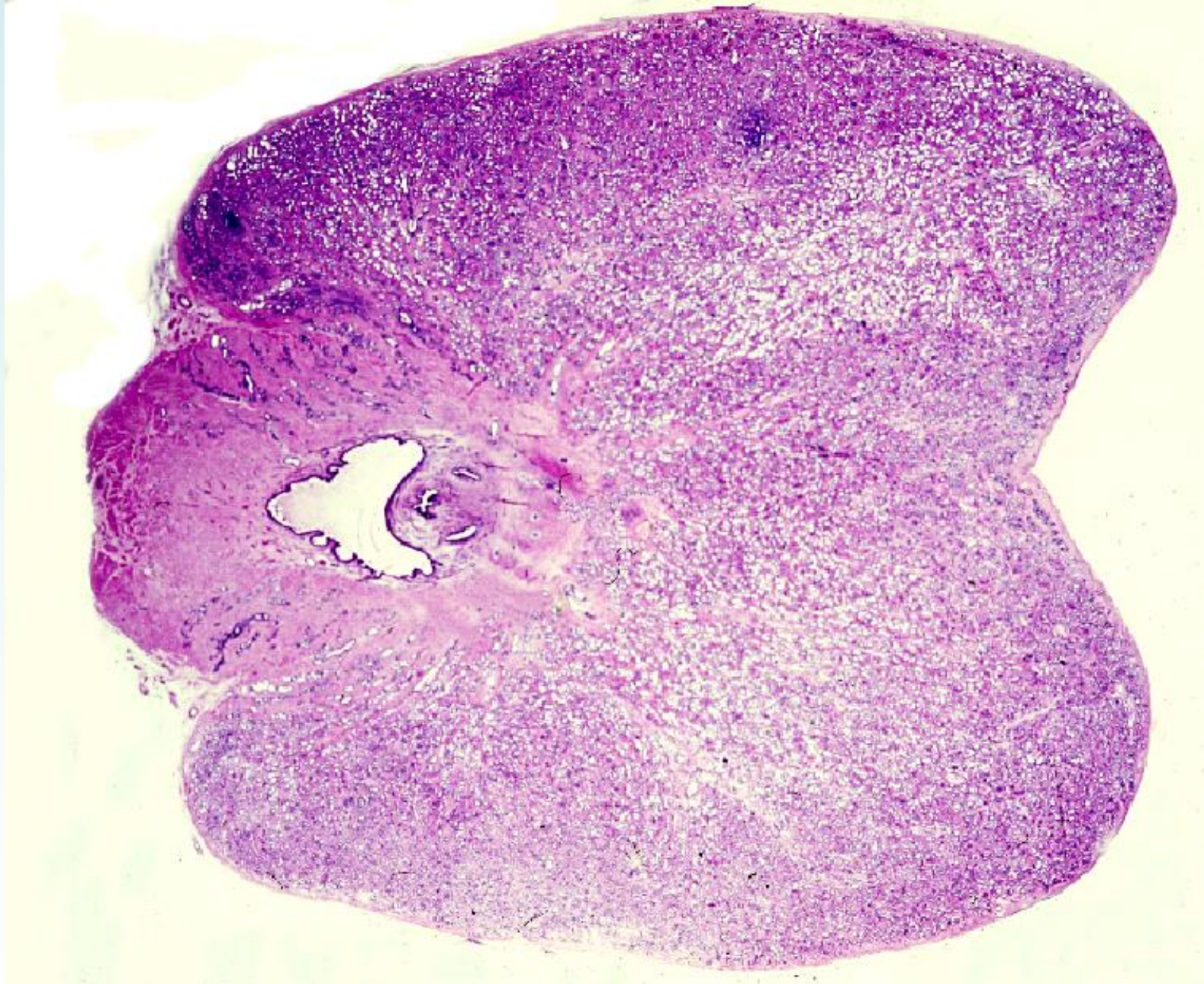
16-38 Seminal vesicle 3. Human, H-E stain, x 100.





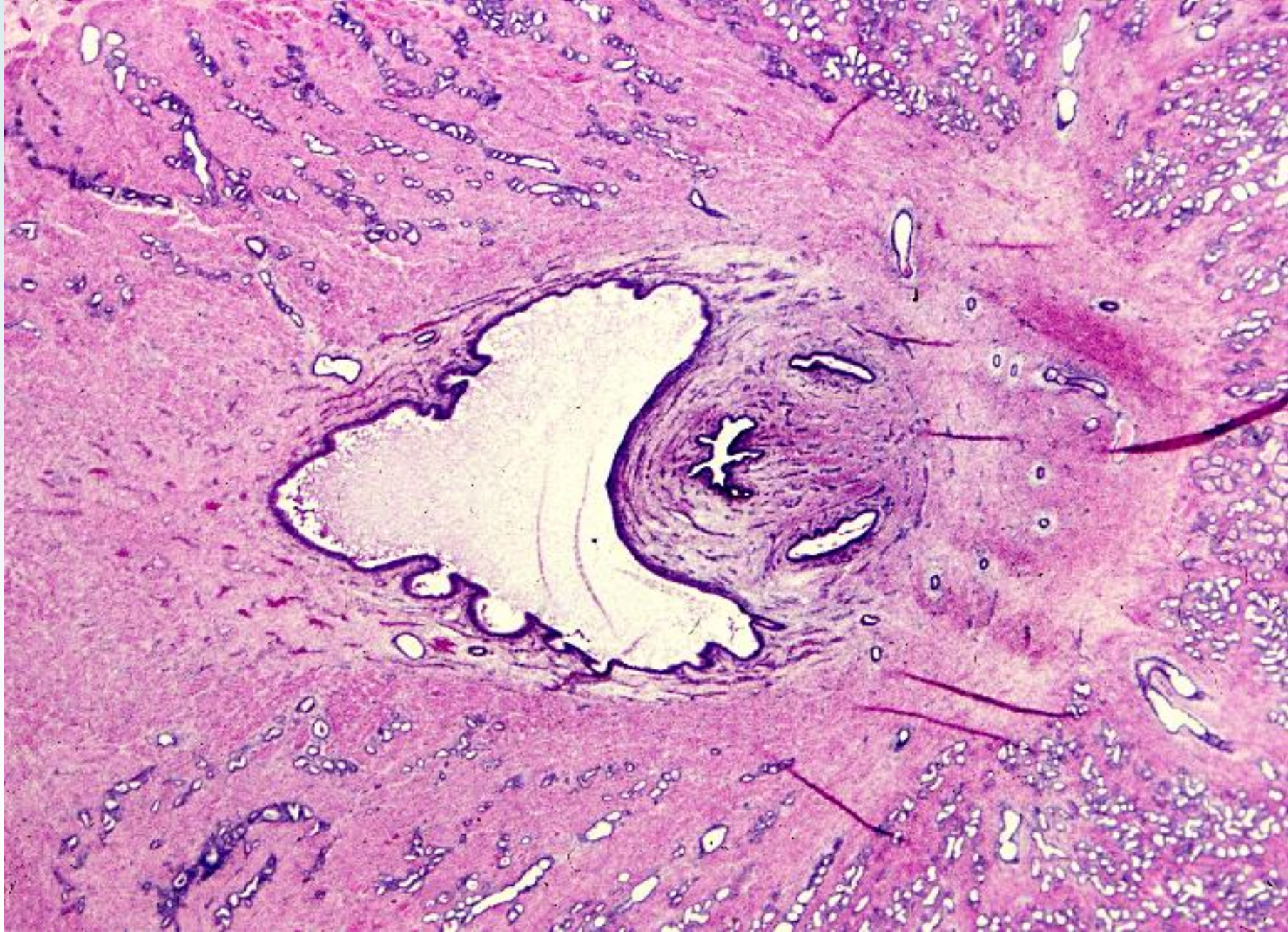
16-39 Seminal vesicle 4. Human, H-E stain, x 100.





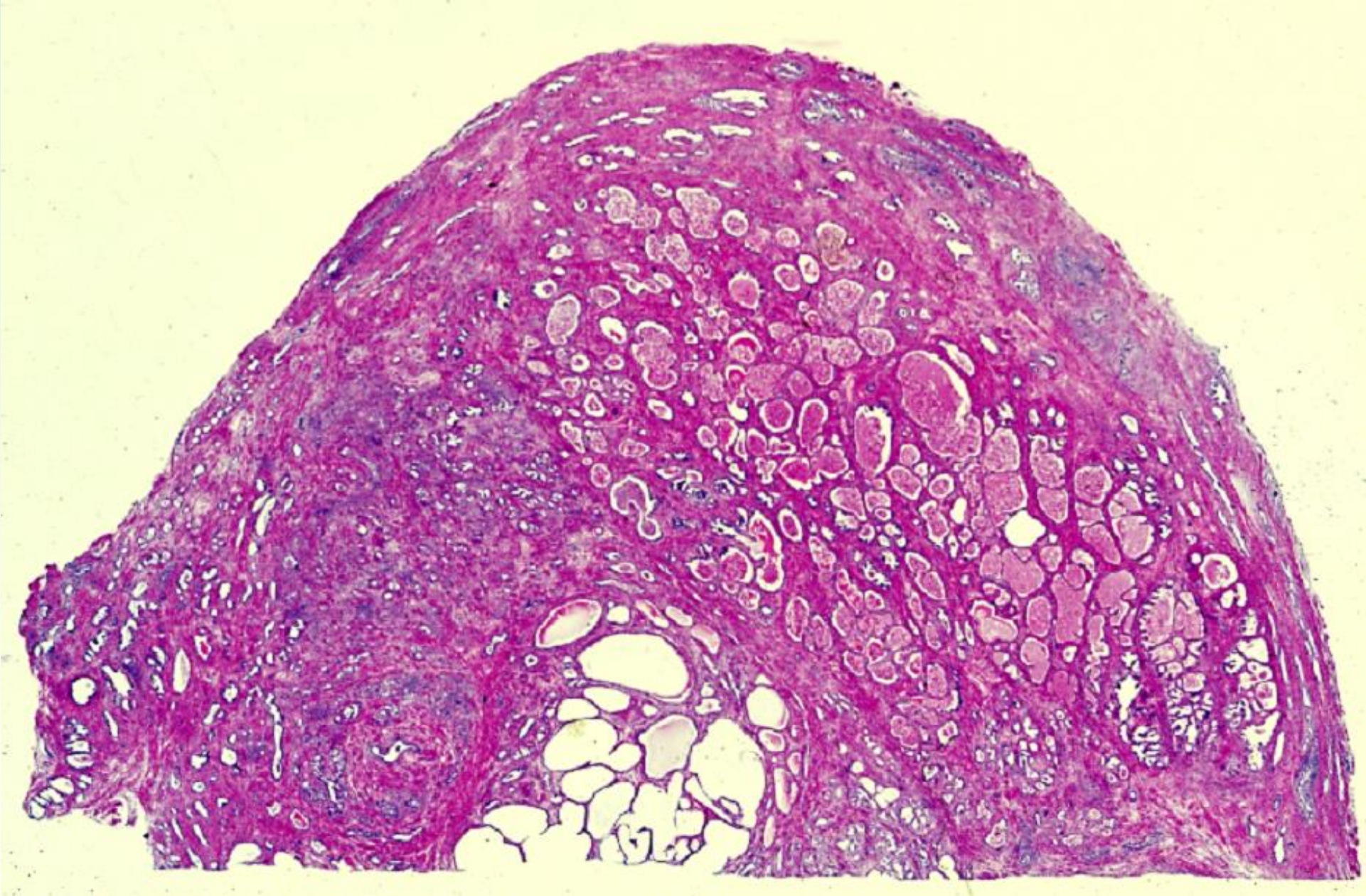
**16-40 Prostate gland 1, Horizontal section, general view. Monkey, H-E stain, x 2.0.**





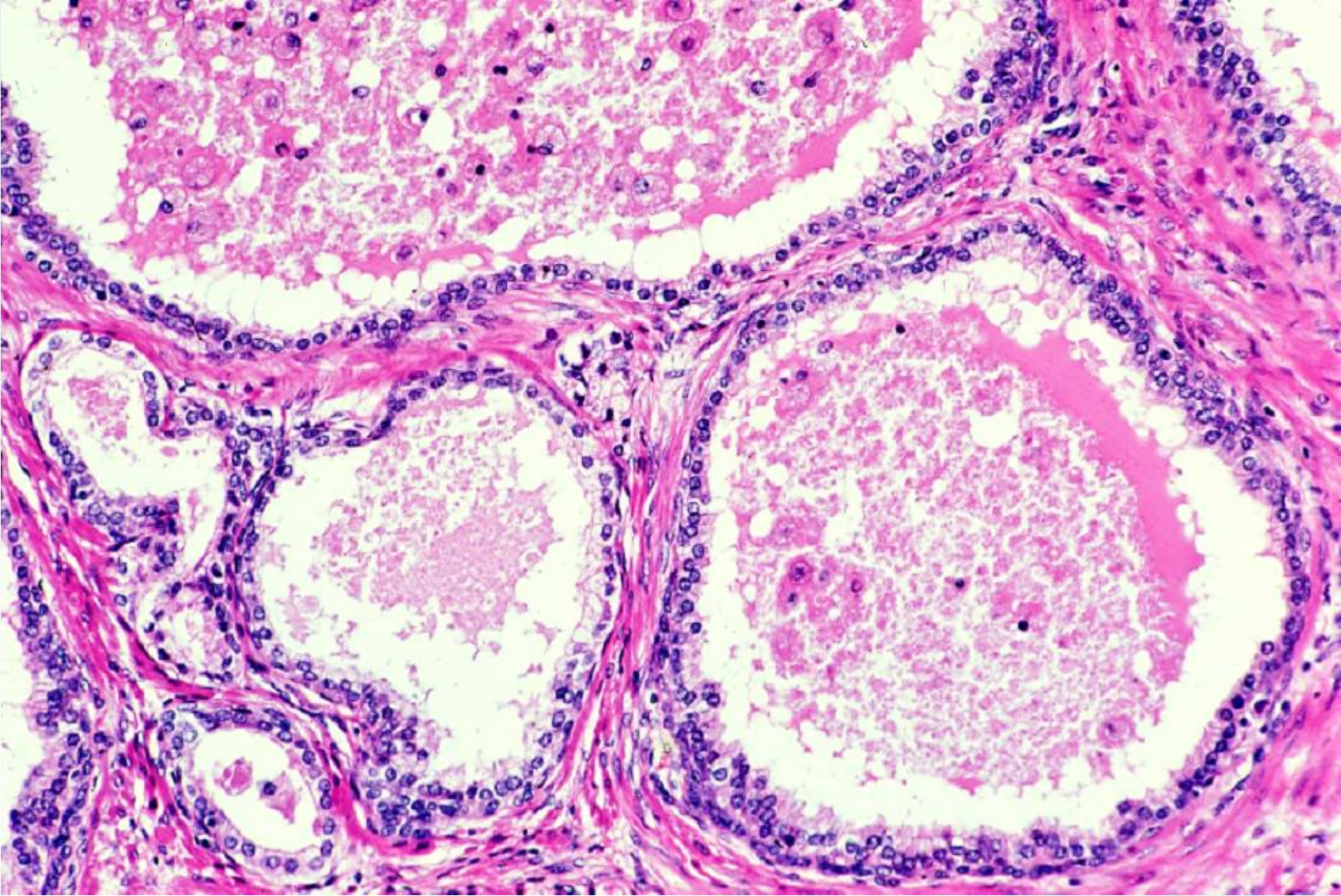
16-41 Prostate gland 2, Urethra and colliculus seminalis, Monkey, H-E stain, x 4.0.





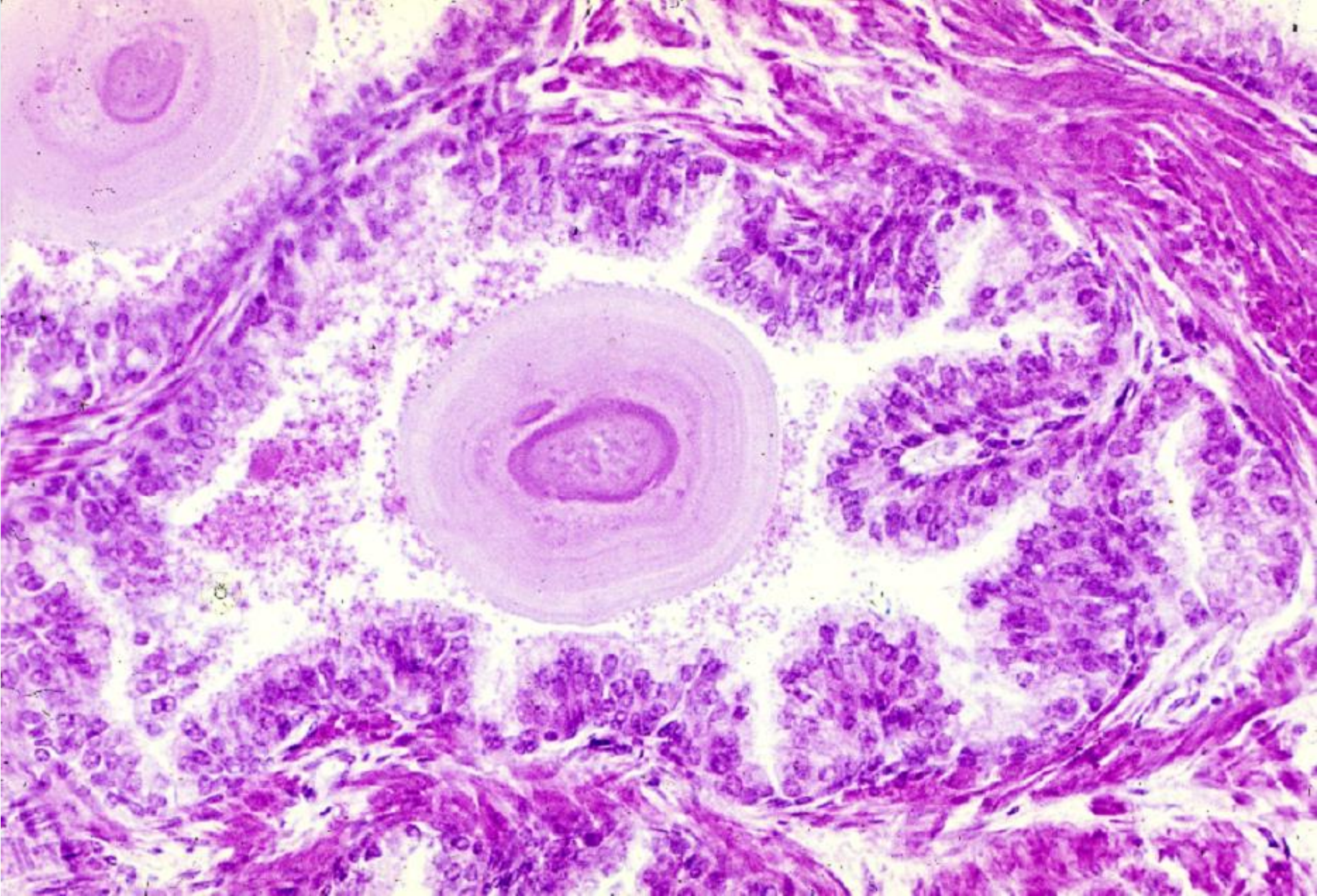
16-42 Prostate gland 3. General view. Human, H-E stain, x 1.8.





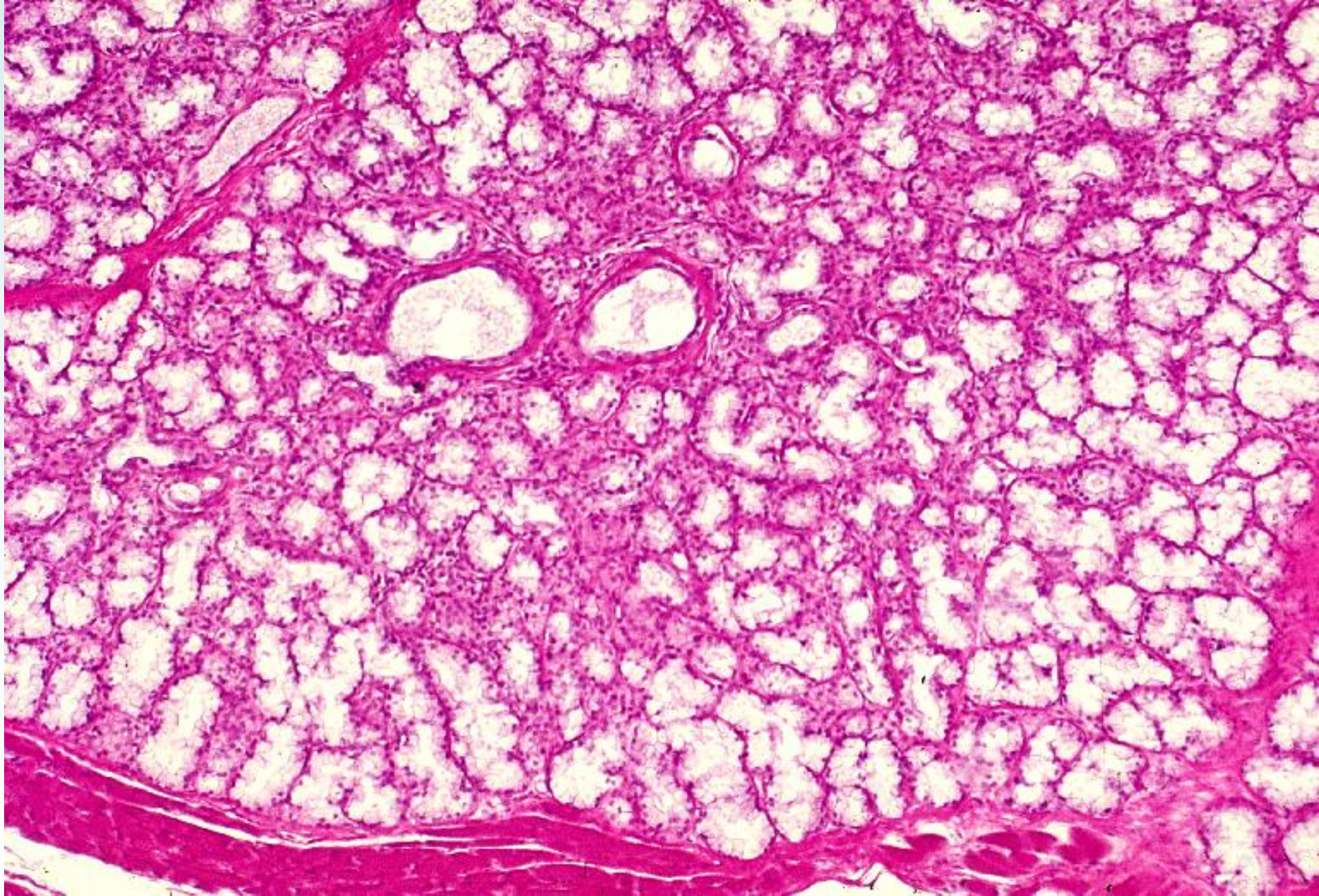
16-43 Prostate gland 4. Acini and interstitium. Human, H-E stain, x 25.





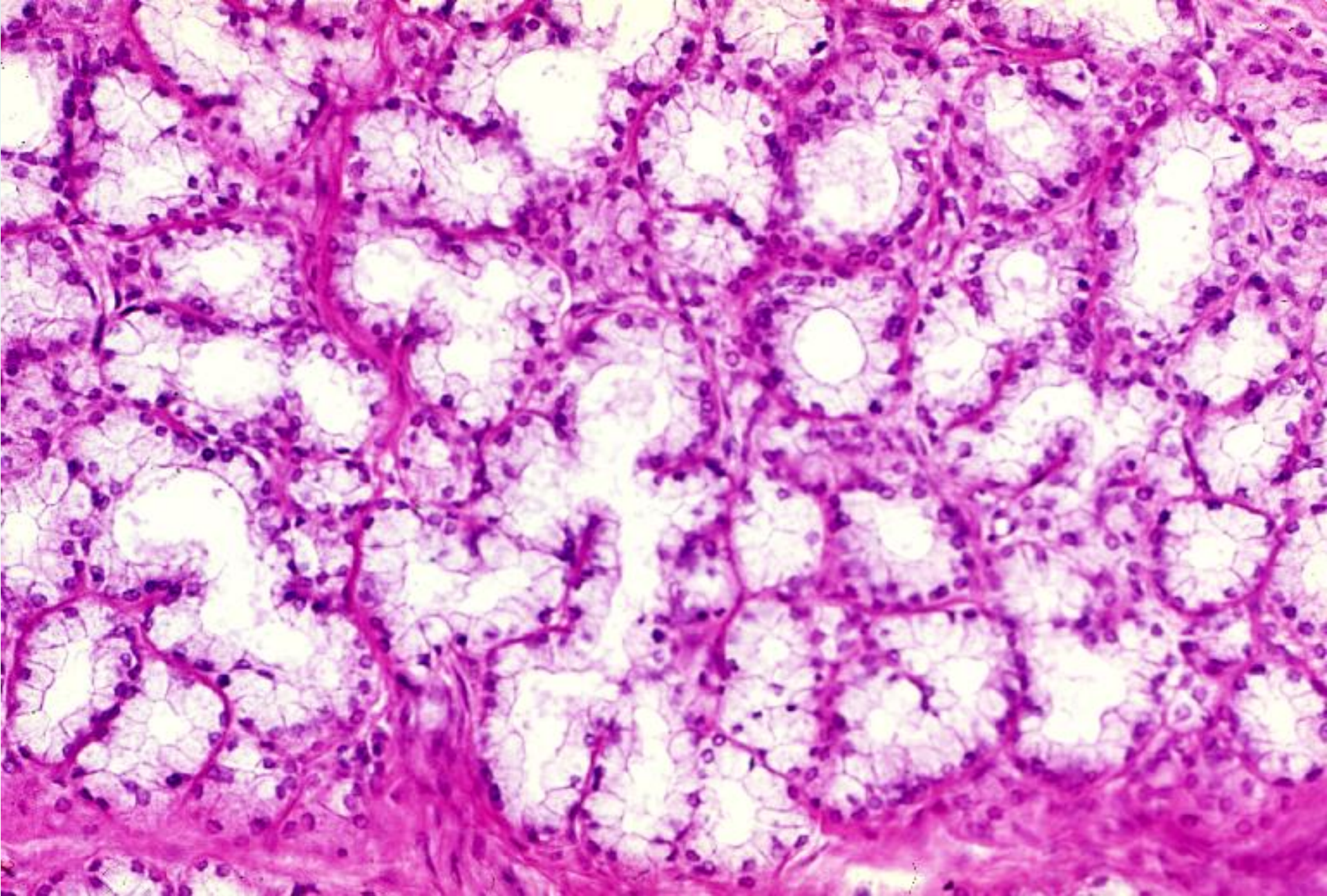
16-44 Prostate gland 5. Prostatic concretions. Human, H-E stain, x 64.





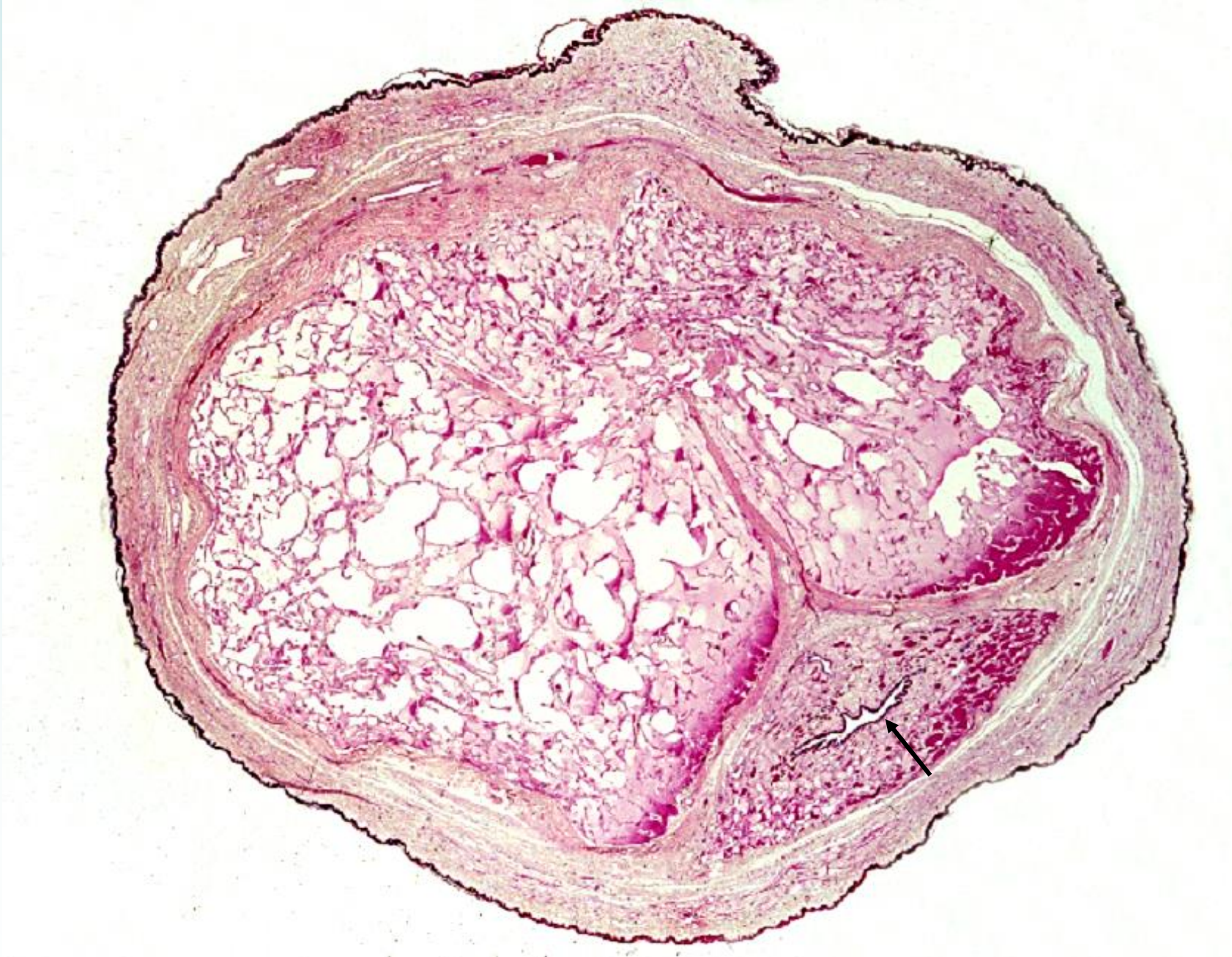16-45 Glandula bulbourethralis 1. Human, H-E stain, x 25.





**16-46 Glandula bulbourethralis 2. Human, H-E stain, x 64.**





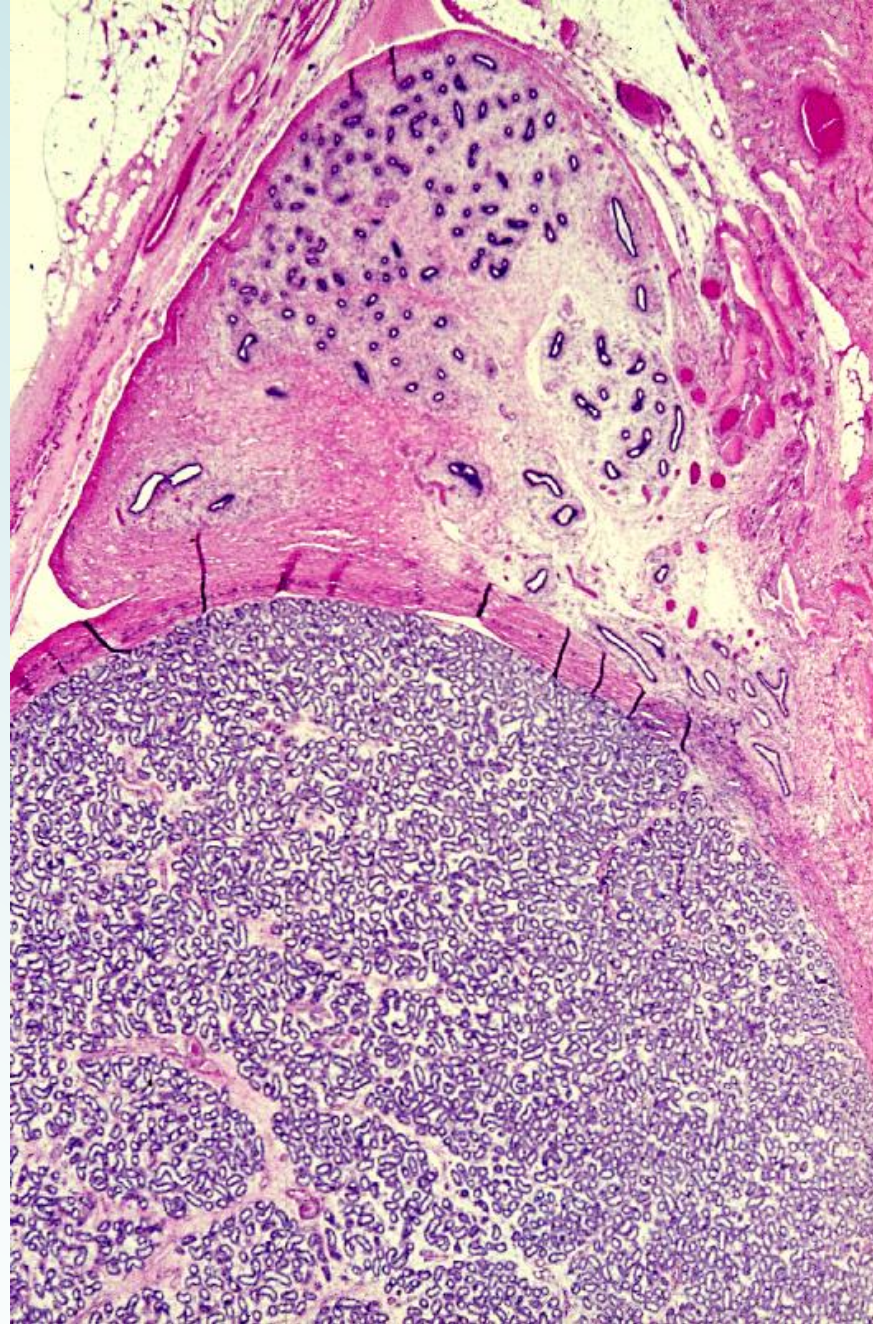
16-47 Penis, transverse section. General view. Human, H-E stain, x 0.8.



# 16-003

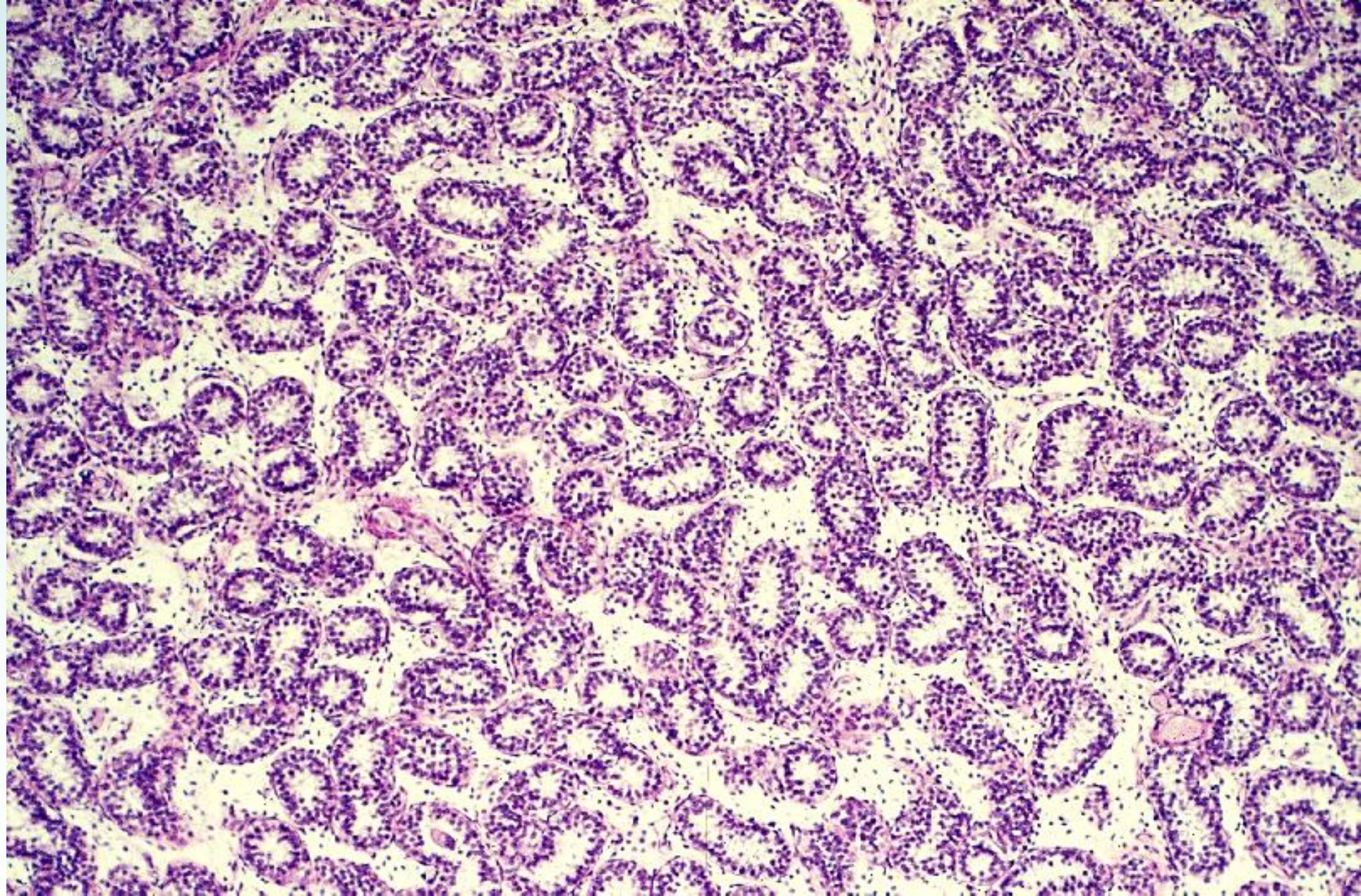
## Testis of a 2.9-year-old Boy





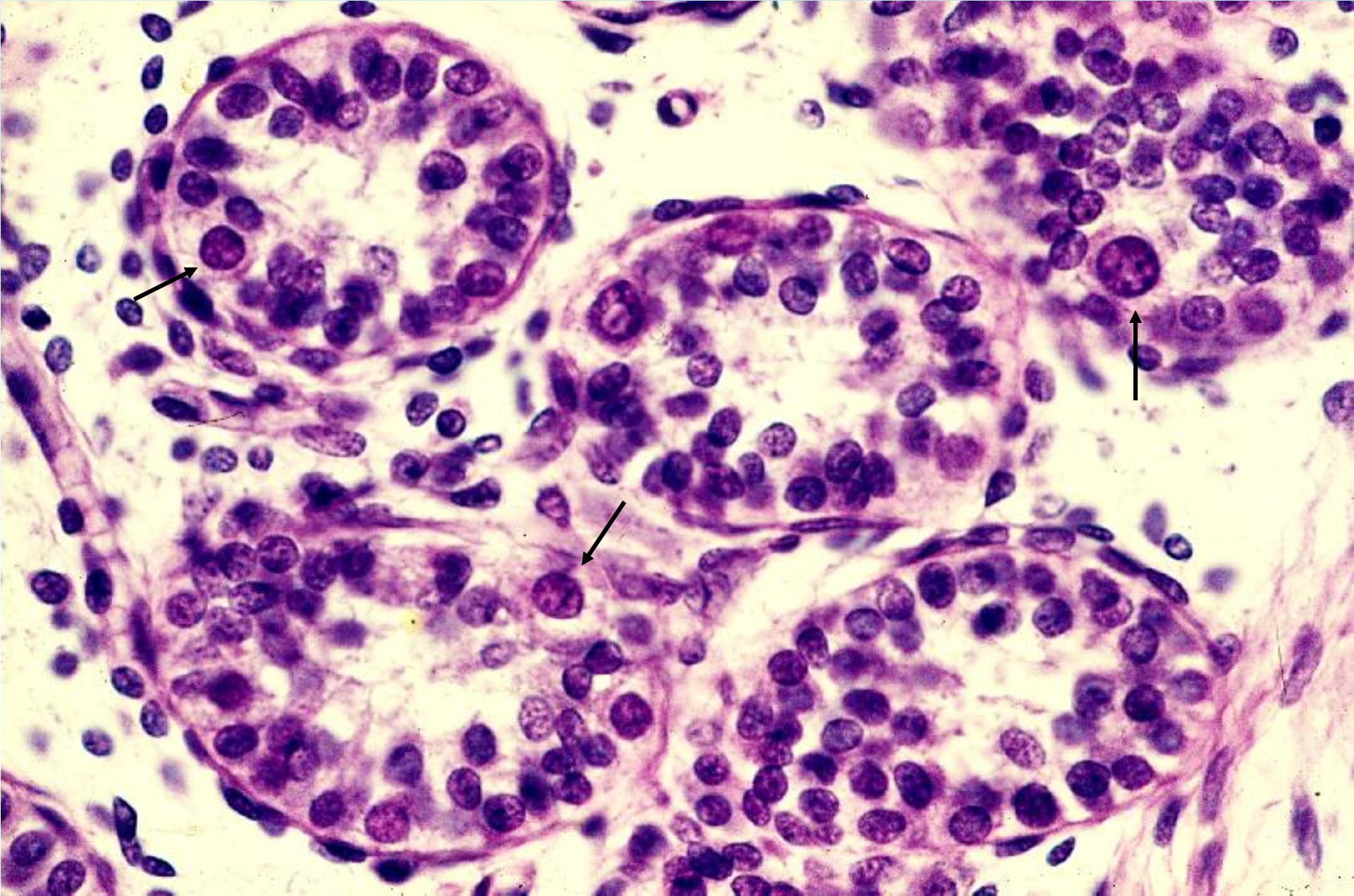
**16-48 Testis of a 2.9-year-old boy, 1. Sagittal section, general view. Human, H-E stain, x10.**





**16-49 Testis of a 2.9-year-old boy, 2. Human, H-E stain, x 25.**





16-50 Testis of a 2.9-year-old boy, 2. Human, H-E stain, x 160.



## 16-00 Male Reproductive System

- The male reproductive system consists of the testes, spermatozoa producing organs, the excurrent duct system, tubuli semineferi contorti, ductus epididymidis, ductus deferens, and ductus ejaculatorius, through that spermatozoa are conveyed until the male urethra, and the penis, the male copulatory organ, through which spermatozoa are discharged into the female corresponding copulatory organ, vagina. Three accessory glands, the seminal vesicles, the prostata and the bulbourethral glands belong to the duct system.

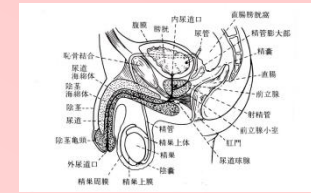


## 16-001 Testis

- The paired testes are suspended in a cutaneous sac, the scrotum. The human testes are ovoid in form, 4~5 cm in length, about 2.5 cm in width and about 3 cm in anteroposterior diameter. Their average weight is 14 g. The testis is enclosed in a thick dense fibrous capsule, the tunica albuginea, which thickens on the posterior surface of the testis forming a thick dense connective tissue mass and extending inward to form the mediastinum testis. Thin fibrous partitions radiate from the mediastinum to the tunica albuginea and divide the interior of the testis into about 250 pyramidal compartments, the lobuli testis.



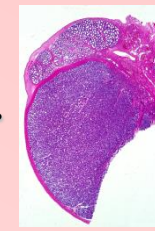
## 16-01 Scheme of male reproductive system.



- This is to show the midline structures of the male reproductive system in sagittal section. The bilateral structures are depicted intact.



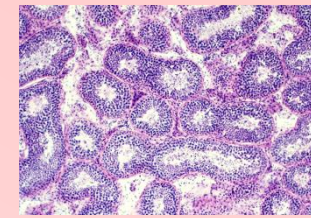
## 16-02 Sagittal section of a human testis. General view. H-E stain, x 1.0.



- This is a general view of a human testis, sagittally sectioned.
- The lower two thirds of this figure occupies the testis, deep violet stained and consisting of a lot of seminiferous tubules. The testis is enclosed by a dense collagen fiber capsule, tunica albuginea, which thickens at the posterior surface of the testis forming the mediastinum testis. To the tip of the testis attaches the epididymis, also enclosed by the tunica albuginea. The epididymis is composed of two portions, the anterior half consisting of ductuli efferentes testis ( double arrows ), and the posterior half, of ductus epididymidis ( arrow ).
- The mediastinum testis sends thin fibrous partitions, septulae testis, inward and divides the interior of the testis into 200~300 pyramidal compartments, lobuli testis.
- In the mediastinum testis, there is a complex cleft-like space system lined by the squamous epithelium, called rete testis.



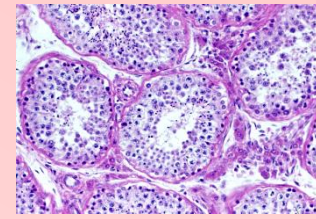
## 16-03 Seminiferous tubules and interstitium. General view. Human, H-E stain, x 25.



- The substance of the testis consists of a large number of seminiferous tubules and interstitium, very loose, highly vascular connective tissue filling the interstices among the seminiferous tubules. Within this connective tissue there are clusters of interstitial cells, Leydig cells, that are the endocrine cells secreting the male sex hormone, testosterone.
- Each lobule contains 1~4 seminiferous tubules, that are 150~250  $\mu$  m in diameter, 30~70 cm long, and extremely tortuous, and form highly convoluted loops. The lining cells are the spermatozoa producing cells, arranged in 4~8 layers on the basement membrane, and supporting Sertoli cells, standing perpendicular on the basement membrane at a regular interval.
- This figure shows a general view of the seminiferous tubules and very loose interstitial connective tissue containing numerous clusters of the Leydig cells ( arrows ).



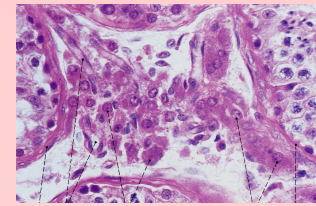
## 16-04 Seminiferous tubules and Leydig cells. Human, H-E stain, x 64.



- Higher magnification of 16-03.
- The seminiferous tubules are encircled by a thick conspicuous basement membrane. The kinds of cells and their arrangement differ in each section of the seminiferous tubules. The interstitial connective tissue is very loose and highly vasculated and contains many clusters of Leydig cells, stained deep red.



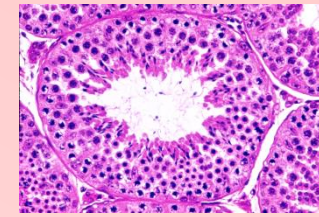
## 16-05 Interstitial cells of Leydig. Human, H-E stain, x 160.



- Higher magnification of 16-04.
- The angular interstice between the seminiferous tubules, upper right and upper left, is occupied by clusters of the Leydig cells, secreting the male sex hormone, androgen. They are large ovoid cells containing a spherical nucleus and their plenty cytoplasm stains deeply with acid dye, eosin. These clusters are penetrated by blood vessels. The Leydig cells contain in the cytoplasm crystals of variable size, called crystals of Reinke; in this figure, however, these crystals are not recognized.



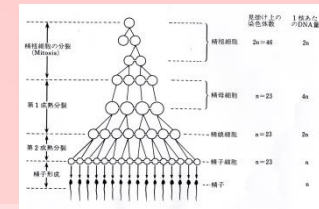
## 16-06 Seminiferous tubules 1. Monkey, H-E stain, x 100.



- Figures, 16-06, 16-08~16-13 and 16-15~16-19, are made from a monkey testis, which was properly fixed and suitably prepared so that the processes of the spermatogenesis are very clearly observed.
- This figure, 16-06, shows the general features of the spermatogenesis. In the region A, the spermatogonia and primary spermatocytes are observed; in the regions B1 and B2, the spermatogonia and secondary spermatocytes; and in the region C, the spermatogonia and spermatids. The superficial layer, surrounding the lumen, is occupied by the spermatids, performing the spermiogenesis. In the interstices between the seminiferous tubules there are small clusters of the Leydig cells.



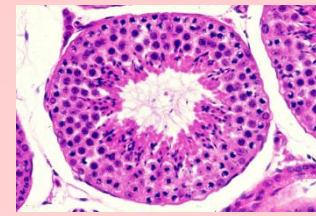
## 16-07 Scheme showing the spermatogenesis.



- This scheme shows the whole process of the spermatogenesis from the spermatogonia to the mature spermatozoa. The stem cells in the spermatogenesis are called the spermatogonia, which rest on the basement membrane of the seminiferous tubule. They repeat the mitotic cell division rhythmically to expand their numbers, and give rise to the primary spermatocytes. The primary spermatocytes begin the meiotic cell division. They grow larger and their nucleus displays the chromosomal figures of the first meiotic prophase, from the leptotene stage, via sygoten and pachitene sages to the diplotene stage. At metaphase these diplotene chromosomes are arranged on the equatorial plate. In anaphase each primary spermatocyte divides into two secondary spermatocytes, containing half numbers of diploide chromosomes. Soon they all perform the second meiotic division to become the spermatids. having haploid nuclei. Thus, one primary spermatocyte, after twice successive meiotic divisions, produces four spermatids of haploid nucleus. The spermatids are small round cells, about  $7$  to  $8\ \mu\text{m}$  in diameter, and begin the spermiogenesis or spermatohistogenesis to become the mature spermatozoa.



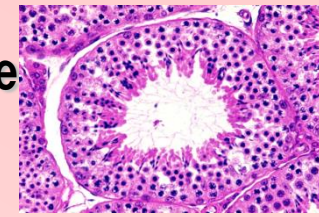
## 16-08 Seminiferous tubule 2. Spermatogonia and primary spermatocytes. Monkey, H-E stain, x 100.



- Figures 16-08 to 16-10 are photomicrographed with a magnification x 100.
- In 16-08 spermatogonia, primary spermatocytes and spermatids, performing the spermiogenesis. Along the inner surfaced of the basement membrane line the spermatogonia, some of which have the nucleus in resting stage, whereas others performing the mitotic cell division. Above them the primary spermatocytes, large round cells with a large round nucleus of pachitene stage, are arranged in two to four layers. The uppermost layers surrounding the lumen consist of spermatids, performing the spermiogenesis. The lower one fourth of this tubule there are no primary spermatocytes, instead cells of meta- or anaphase nuclei; they are cells performing the first meiotic division.



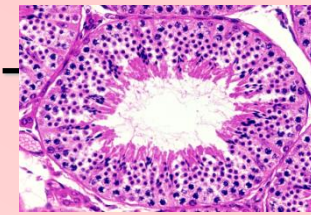
### 16-09 Seminiferous tubule 3. Spermatogonia and secondary spermatocyte Monkey, H-E stain, x 100.



- In this tubule, spermatogonia and secondary spermatocytes are encountered. The primary spermatocytes in 16-08 performed all the first meiotic division and became the secondary spermatocytes. The spermatids surrounding the lumen progress the spermiogenesis and their nuclei approach to the form of the head of spermatozoa. Arrow indicates the interstitial cells of Leydig.



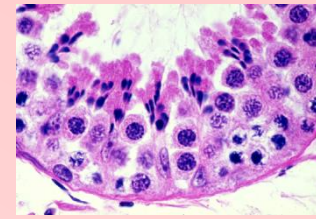
**16-10 Seminiferous tubule 4. Spermatogonia and spermatids. Monkey, H-stain, x 100.**



- The secondary spermatocytes in 16-09 performed all the second meiotic division and have become the spermatids. The spermatids of the previous generation surrounding the lumen almost completed the spermiogenesis. Along the inner surface of the basement membrane numerous spermatogonia are performing the mitotic division. Among these spermatogenetic cells the Sertoli cells are recognized standing perpendicular to the basement membrane at regular intervals. Arrow indicates the interstitial cells of Leydig.



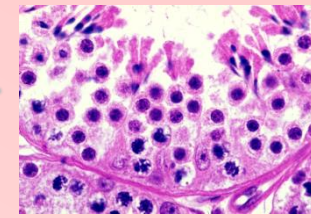
## 16-11 Spermatogenesis 1. Spermatogonia and primary spermatocytes. Monkey, H-E stain, x 250.



- 16-11~16-13 show the spermatogenesis in detail at higher magnification, x 250.
- In 16-11, the spermatogonia in resting stage as well as in mitotic stage, the primary spermatocytes and the spermatids of previous generation performing the spermiogenesis are shown. The Sertoli cells stand on the basement membrane, perpendicular to it are evidently seen (arrows). To the tip of each Sertoli cell attach the spermatids and are performing the spermiogenesis.



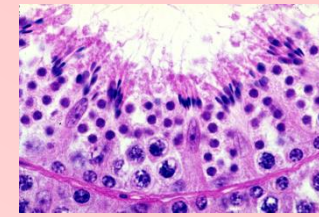
## 16-12 Spermatogenesis 2. Spermatogonia and secondary spermatocytes. Monkey, H-E stain, x 250.



- On the basement membrane stand the Sertoli cells perpendicular to the membrane at regular intervals and the interspaces between them are occupied by the secondary spermatocytes. The primary spermatocytes in 16-11 did all the first meiotic division and have become the secondary spermatocytes. The spermatids surrounding the lumen show the advanced figure in spermiogenesis. The spermatogonia show the mitotic figure except for one locating at the right edge.



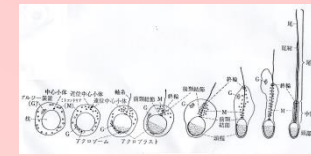
### 16-13 Spermatogenesis 3. Spermatogonia and spermatids. Monkey, H-E stain, x 250.



- In this figure the Sertoli cells standing on the basement membrane at regular intervals are evident ( arrows ). The interspaces between them are occupied by the spermatids, small round cells about  $10\mu\text{m}$  in diameter. The spermatids of the previous generation, surrounding the lumen, are now completing the spermiogenesis.
- The spermatogonia are resting on the basement membrane. At the center five large round cells having a large round nucleus of the pachitene stage are the primary spermatocytes of the following generation.



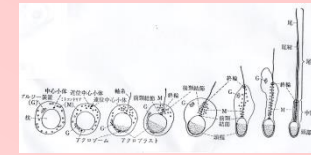
## 16-14 Scheme showing the spermiogenesis. (1/3)



- The spermatids carry out further post meiotic changes to transform into spermatozoa. The successive morphological changes from the spermatids to the spermatozoa are called the spermiogenesis.
- The spermatids just after the meiotic division are the smallest round cells among the spermatogenic cells in the seminiferous tubules. They are round cells of about  $10\text{ }\mu\text{m}$  in diameter having a round nucleus of **haploid** chromosomes. **p 775 右**
- Their cytoplasm contains short mitochondria, vesicular and tubular profiles of endoplasmic reticulum and a prominent Golgi complex. The first sign of their differentiation into the spermatozoa is the appearance of small membrane-bounded **proacrosomal granules** at the trans-face of the juxta-nuclear Golgi complex (1). As development progresses, these coalesce into a single large granule within a larger **acrosomal vesicle** (2). The limiting membrane of this vesicle becomes adherent to the nuclear envelope. The point of its initial adherence marks the future apex of the condensed sperm nucleus (3). The Golgi complex remains closely associated with the surface of the acrosomal vesicle and continues to form condensing vacuoles that fuse with it, adding its contents. As the volume of the acrosomal vesicle increases, the area of its membranes adhering to the nuclear envelope spreads laterally from the point of initial contact and it becomes hemispherical in shape (4). Then, the dense acrosomal granule remains at the pole of the nucleus, while the surrounding vesicle further expands its area of attachment to the nuclear envelope by forming a thin fold that extends laterally and posteriorly until it covers the whole anterior hemisphere of the nucleus (5). The greater part of the substance of the acrosomal granule become redistributed throughout the interior of the cap formed by the acrosomal vesicle. With these changes, the formation of the acrosome is completed. .



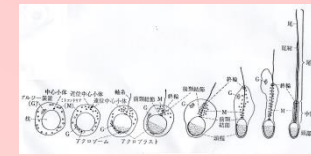
## 16-14 Scheme showing the spermiogenesis. (2/3)



- Concurrent with the later stages of acrosomal formation, there is a condensation of the nucleoplasm beginning with the appearance of thin filaments that then shorten and thicken to form coarse granules of chromatin. These increase in size and ultimately coalesce, transforming the chromatin to a dense homogeneous state devoid of resolvable substructure (6). The considerable decrease in volume of the nucleus, due to condensation of the chromatin, is accompanied by a change in its shape to a form characteristic of the human spermatozoa, pyriform.
- While the acrosome is forming at the anterior pole of the nucleus, the centrioles move to the cell surface at the posterior pole of the spermatid.(2). There, one of the centrioles becomes oriented perpendicular to the cell membrane and the triplet microtubules in its wall serve as templates for assembly of doublet microtubules, initiating the formation of the **axoneme** of the sperm flagellum. The lengthening flagellum grows out into the space between the spermatid and its supporting Sertoli cell. At about the time that nuclear condensation begins, the pair of the centrioles move inward to the posterior pole of the nucleus. In doing so, the initial portion of the flagellum and its enveloping membrane are drawn into a deep tubular recess in the cell surface (3, 4, 5).
- In the spermatid cytoplasm, microtubules increase in number and become associated in a roughly cylindrical array forming the **manchette**, which extends caudally from a circumferential specialization of the nuclear envelope at the posterior margin of the acrosomal cap. With the formation of the manchette, there is a marked elongation of the spermatid, with the bulk of the cytoplasm moving behind the posterior pole of the nucleus where it surrounds the proximal portion of the flagellum. As a consequence of this shift, the membrane at the anterior end of the cell becomes closely applied to the outer membrane of the acrosome with no intervening cytoplasm.



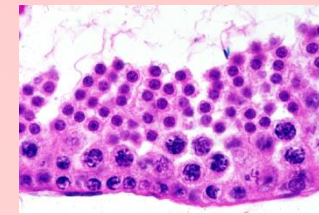
## 16-14 Scheme showing the spermiogenesis. (3/3)



- Until this stage of spermatid differentiation, the tail of the future spermatozoon is represented only by the axoneme enclosed in a flagellar membrane. Where the flagellar membrane is continuous with the membrane of the cell body, dense material adhering to its cytoplasmic face condenses to form a ring that is the precursor of the **annulus** that will later be situated at the junction of the mid-piece and principal piece of the sperm tail. The annulus and its adherent membrane then move caudad along the axoneme obliterating the tubular invagination of the cell surface and exposing the first few microns of the axoneme to the cytoplasm. Concurrently, the microtubules of the manchette disperse and mitochondria gather around the initial segment of the axoneme, where they become arranged end-to-end in a tight helix, forming the **mitochondrial sheath** of the sperm middle-piece.
- While these events are in progress, nine longitudinal **dense fibers** form immediately outside of the nine doublets of the axoneme. These are continuous at their proximal end with nine cross-striated columns of the **connecting piece** that surrounds the centrioles and attaches to the rim of a shallow depression in the posterior surface of the condensed nucleus. The outer dense fibers course parallel to the doublets of the axoneme from the connecting piece to the caudal end of the principal piece of the future spermatozoon. After formation of the dense fibers, a succession of circumferentially oriented **ribs** form around that portion that is distal to the annulus. At their ends, these semicircular ribs are joined to two longitudinal dense columns that run along the dorsal and ventral aspects of the tail. Together, the ribs and the longitudinal columns make up the **fibrous sheath** of the principal piece of the sperm tail( 6, 7, 8 ).p 779 右



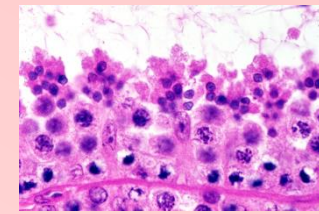
## 16-15 Spermiogenesis 1. Monkey, H-E stain, x 250.



- 16-15~16-19 show the successive morphological changes in the spermiogenesis.
- 16-15 shows the spermatids just after the second meiotic cell division. They are small round cells of about  $10\mu\text{m}$  diameter and each contains a spherical nucleus showing the rest stage. They occupy the highest position in the seminiferous tubule making 5 to 7 layers. They do not show still any special sign of differentiation.
- Lower to them there are large round cells with a large spherical nucleus if the pachitene stage. They are the primary spermatocytes of the following generation. The lowermost layer consists of the spermatogonia making one-cell-layer on the basement membrane. Arrows indicate the Sertoli cells.



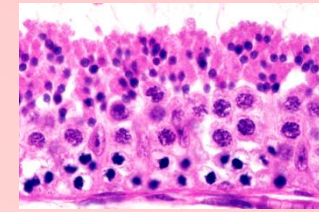
## 16-16 Spermiogenesis 2. Monkey, H-E stain, x 250.



- The spermatids attach their head to the tip of the Sertoli cells ( arrow ) and their nuclei become smaller and angular in form and the nucleoplasm is condensed. The bulk of the cytoplasm moved behind the posterior pole of the nucleus. The large round primary spermatocytes, making 2- to 3- cell-layer, attach to both sides of the Sertoli cells. The spermatogonia on the basement membrane are performing the mitotic cell division.



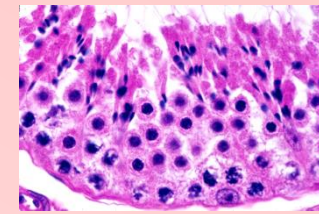
## 16-17 Spermiogenesis 3. Monkey, H-E stain, x 250.



- The transformation of the spermatids progressed. They attach their head to the tip of the Sertoli cells ( arrow ), both side of which attach the primary spermatocytes in two cell layers. The spermatogonia constituting the lowermost layers on the basement membrane are doing the mitotic cell division.



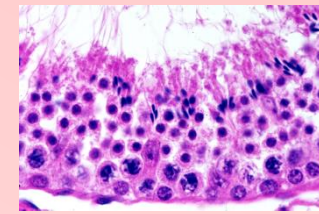
## 16-18 Spermiogenesis 4. Monkey, H-E stain, x 250.



- The spermiogenesis of the spermatids progressed further nearing the final form. The primary spermatocytes in the previous figure all disappeared and instead the secondary spermatocytes replaced the space in 3- to 4 -cell-layer. On the basement membrane the spermatogonia are doing the mitotic cell division. At lower right there is a spermatogonium with resting nucleus.



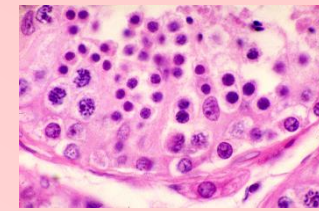
## 16-19 Spermiogenesis 5. Monkey, H-E stain, x 250.



- The uppermost layers surrounding the lumen consists of the spermatids that almost accomplished the spermiogenesis and attained final form, leaving the residual cytoplasm into the lumen. Lower to them there are the spermatids of the following generation, replacing the secondary spermatocytes. On the basement membrane form a line the spermatogonia. Between these spermatogonia and the spermatids appear the primary spermatocytes of the next generation to the spermatids. Therefore, in this figure three generations of the spermatogenesis are observed. Arrows indicate the Sertoli cells.



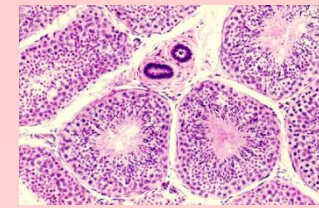
## 16-20 Spermatogenesis in the human testis. H-E stain, x 250.



- In human the spermatogenesis do not progress synchronously, so that it is seldom to encounter three generations on one section. This figure shows the rare case. The Sertoli cell indicated by arrow with two arrow heads embraces six secondary spermatocytes on both sides and two spermatids on the tip of the cell. Three Sertoli cells indicated by arrows embrace the numerous spermatids and the most left one further three primary spermatocytes. On the basement membrane line the spermatogonia. The arrowhead indicates the interstitial cell of Leydig.



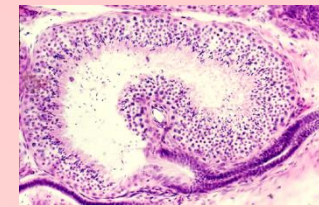
## 16-21 Tubuli seminiferi contorti et recti. Monkey, H-E stain, x 64.



- At the center above there are two sections of tubulus seminiferus rectus, lined by a simple columnar epithelium. Others surrounding them are all sections of tubulus seminiferus contortus, lined by spermatogenic epithelium.



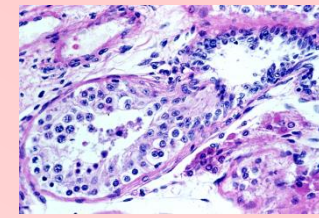
## 16-22 Transition from contortus to rectus tubule 1. Monkey, H-E stain, x 64.



- Each testicular lobule is pyramidal in shape and composed of highly convoluted seminiferous tubules. At the narrow apex of the pyramid the convoluted seminiferous tubule transits abruptly to a short straight tubule, tubulus seminiferus rectus.
- This figure shows the transition of the contortus tubule to the rectus tubule. Here spermatogenic cells abruptly disappear ( arrow ) and remain only the tall Sertoli cells forming a valve-like structure which prevents the back flow of the sperm. The epithelium of this valve is continuous with that of the rectus tubule, the simple columnar epithelium.



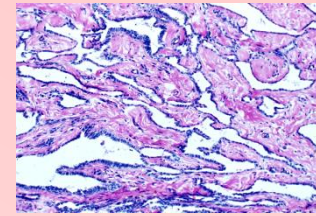
## 16-23 Transition from contortus to rectus tubule 2. Human, H-E stain, x 100.



- This figure shows also the transition from the contortus tubule to the rectus tubule. The valve-like structure formed by the Sertoli cells is conspicuous. Right side to this structure is the beginning of the rectus tubule. Arrow indicates the Leydig cells.



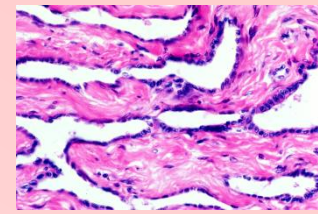
## 16-24 Rete testis 1. Human, H-E stain, x 40.



- The tubuli seminiferi recti converge on the rete testis, a plexus of epithelium-lined spaces in the dense connective tissue of the mediastinum. This figure shows a general view of the human rete testis.



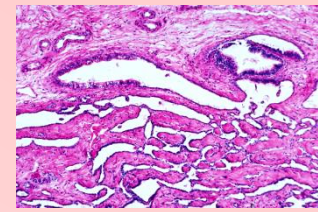
## 16-25 Rete testis 2. Human, H-E stain, x 100.



- Higher magnification of 16-24. The lumen of the rete testis is a plexus of the irregular cleft-like spaces, lined by simple cuboidal or simple squamous epithelium, in the dense connective tissue of the mediastinum testis.



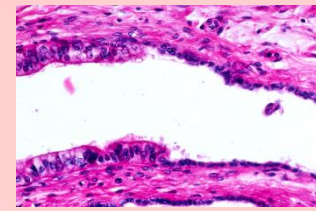
**16-26 Transition from rete testis to efferent ductulus 1. Human,  
H-E stain, x 25.**



- At the upper front portion of the mediastinum lumen of the rete testis continues with that of the ductulus efferens testis. This transition is also abrupt. In this figure, at upper left corner the lumen of the rete testis is continuous with that of the efferent ductulus ( arrow ), lined by a tall columnar epithelium. The lower half of this figure is occupied by the rete testis.



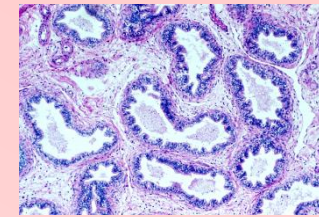
## 16-27 Transition from rete testis to efferent ductulus 2. Human, H-E stain, x 100.



- Higher magnification of 16-26. The transition from the rete testis to the efferent ductulus is evident. The lumen of the rete testis is lined by a simple squamous or simple cuboidal epithelium, whereas that of the efferent ductulus is lined by a epithelium consisting of tall columnar ciliated cells and low cuboidal cells.



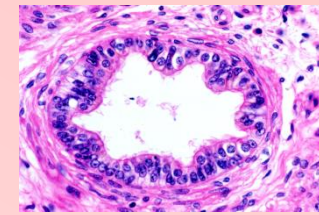
## 16-28 Ductuli efferentes testis 1. Human, H-E stain, x 64.



- From the rete testis emerge 10 to 15 ductuli efferentes testis, that traverse the tunica albuginea and appear on the anterosuperior surface of the testis. They constitute the frontal half of the epididymis. Each ductulus is highly convoluted and forms as a whole a long pyramid, whose base looks front-upward. At the base of the pyramids all ductuli open into one common duct, ductus epididymidis. The initial portion of the ductus epididymidis is highly convoluted and composes the posterior half of the epididymis ( see 16-02 ).
- This figure shows sections of the ductuli efferentes that are lined by an epithelium consisting of two groups of cells alternately, the one are tall columnar cells, the other low cuboidal cells, resulting in the uneven contour of the lumen. The interstitial connective tissue filling the space between the ductuli is very loose and contains numerous blood vessels and lymphatics ( arrow ).



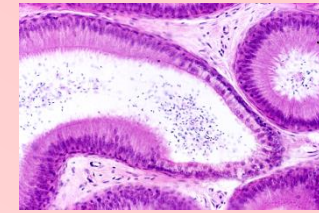
## 16-29 Ductulus efferens testis 2. Human H-E stain, x 160.



- Higher magnification of 16-28. The ductulus efferens is lined by an epithelium, consisting of groups of tall columnar ciliated cells alternating with groups of low cuboidal nonciliated cells. The nuclei of the tall ciliated cells are arranged in two layers and the cells containing the superficially located nucleus possess conspicuous cilia, that beat toward the epididymis, moving the luminal fluid and spermatozoa in this direction. The nonciliated cells contain coarse granules in the cytoplasm, that are the lysosomes. Each ductulus is encircled by a conspicuous basement membrane and further by the concentrically oriented collagen fibers. Arrow indicates a lymphatic.



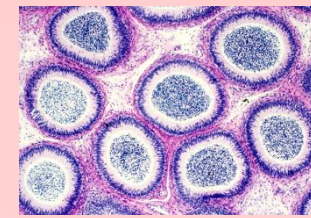## 16-30 Transition from the ductulus efferens to the ductus epididymidis. Monkey, H-E stain, x 64.



- Ductuli efferentes testis open into one common duct, ductus epididymidis, at the upper frontal region of the epididymis. This ductus epididymidis proceeds posteriorly and at about the middle of the epididymis, posterior to the ductuli efferentes testis, begins the highly convoluted course, composing the posterior half of the epididymis. The transition from the ductulus efferens testis to the ductus epididymidis is also abrupt.
- This figure (16-30) shows this abrupt transition from the ductulus efferens to the ductus epididymidis ( arrows ). The cuboidal epithelium is continuous abruptly with the tall columnar ciliated epithelium of the ductus epididymidis.



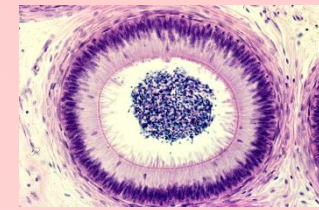
## 16-31 Ductus epididymidis 1. Human, H-E stain, x 25.



- The ductus epididymidis is a highly convoluted and surprisingly very long duct, total about 6 m long, which constitutes the epididymis, an organ attaching to the upper and posterior surface of the testis. The epididymis is roughly divided into three regions: the caput ( head ) at the upper pole of testis, the corpus ( body ) along the posterior surface of the testis, and cauda ( tail ) at its postero-lower pole. The frontal ( anterior ) half of the caput consists of the ductuli efferentes testis, and the posterior half exclusively of ductus epididymidis. At the distal ( postero-lower ) end of the cauda, the ductus epididymidis straightens and turns upward as the ductus deferens.
- The spermatozoa leaving the testis are still not mature and during conveyance within the ductus epididymidis, about 3 to 5 days , they acquire motility and capacity to fertilize ova..
- The ductus epididymidis is lined by a pseudstratified tall columnar epithelium consisting of two types of cells: principal cells and basal cells. The principal cells are very tall and each have on their free surface a tuft of very long microvilli, being nonmotile and called stereocilia.
- External to the epithelium of the duct, there is a layer of contractile cells ( smooth muscle fibers ). It is thin in the caput and thickens gradually in the corpus and in the cauda it is very thick, consisting of three layers of smooth muscle fibers.
- This figure shows the sections of ductus epididymidis, containing a lot of spermatozoa in the lumen. As the height of the epithelial cells is even, the contour of the lumen appears smooth. External to the epithelium encircles a thin layer of smooth muscle fibers.



## 16-32 Ductus epididymidis 2. Monkey, H-E stain, x 64.



- This is a transverse section of the ductus epididymidis, which is lined by a pseudo-stratified very tall columnar epithelium. The tall columnar cells are provided with conspicuous terminal bar and thick and long stereocilia protruding into the lumen. External to the epithelium encircles a layer of the contractile cells consisting of the concentrically oriented thin smooth muscle fibers. Innumerable spermatozoa are seen in the lumen.

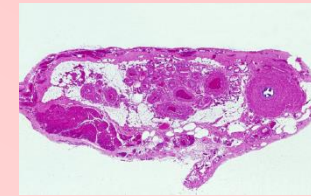

## 16-002 Spermatic cord, Seminal vesicle, Prostata and Penis

- The spermatic cord ( funiculus spermaticus ) consists of ductus deferens, plexus pampiniformis of veins, spermatic artery and nerves, that are loosely surrounded and bundled by a connective tissue sheath.
- The spermatic cord is surrounded by the cremaster muscle which consists of slender fascicles of striated muscle fibers that arise from the inguinal ligament and internal oblique muscle of the abdominal wall and form long loops that are incorporated in the connective tissue of the sac-like cremaster fascia in which the testes are suspended.
- In the transition from the ductus epididymidis to the ductus deferens , the lumen widens and the wall thickens. The epithelium and its lamina propria form longitudinal folds that give the lumen a highly irregular in cross section. The height of the pseudostratified columnar epithelium is lower and there is an extensive network of elastic fibers in underlying loose connective tissues. The muscular coat is 1 mm thick and consists of inner and outer layers of longitudinal smooth muscular muscle and intermediate circular layer. The muscle is enveloped in an adventitial layer of connective tissue.



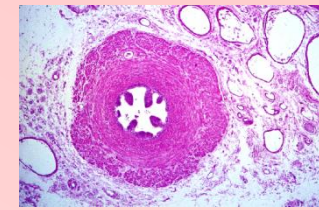
## 16-33 Funiculus spermaticus. Transverse section. Human, H-E stain, x 2.4.



- This is a transverse section of human spermatic cord ( funiculus spermaticus ). At the posterior end is the ductus deferens whose wall consists of very thick muscular layers. In the middle there are numerous sections of veins constituting the plexus pampini- formis, and anterior to them sections of the spermatic artery. These are all surrounded by adipose tissue and further outside by a connective tissue sheath. At the lower anterior corner the cremaster muscle is seen as a large mass of transversely sectioned muscle bundles.

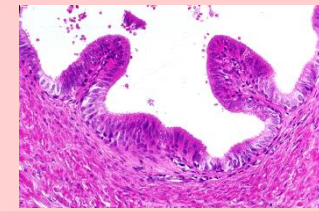


## 16-34 Ductus deferens, transverse section. Human, H-E stain, x 10.



- The lumen shows a highly irregular contour, because the epithelium and its scant lamina propria protrude into the lumen forming numerous longitudinal folds. The surrounding muscular coat is very thick consisting roughly of three layers, inner longitudinal, intermediate circular, and outer longitudinal smooth muscle fibers. The muscle is enveloped in an adventitial layer of loose connective tissue.

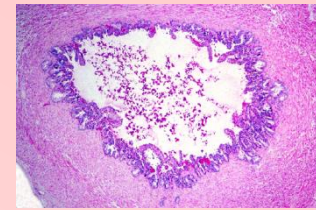
## 16-35 Epithelium of ductus deferens. Human, H-E stain, x 64.



- The pseudostratified or simple tall columnar epithelium and its underlying scant connective tissue, lamina propria, protrude into the lumen forming longitudinal folds. The mucous membrane is surrounded by the muscle layers; in this figure the innermost layer consisting mainly of longitudinally oriented smooth muscle fibers are seen.

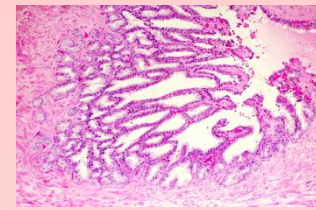


## 16-36 Seminal vesicle 1. Transverse section. Human, H-E stain, x 10.



- At the distal end the ductus deferens forms a fusiform expansion, the ampulla ductus deferentis, and then continues to the ductus ejaculatorius. Just before this junction a blind diverticulum diverges postero-laterally; this is the seminal vesicle, about 5 cm long saccular structure, consisting of a coiled or convoluted tube with numerous diverticula along its length. In sections the mucosa forms thin folds from which secondary and tertiary folds project into the lumen resulting in a very complicated labyrinthine appearance.
- This figure shows a relatively simple appearance of the lumen surrounded by numerous folds of the mucosa. The surrounding muscular layers are here relatively thick and three layers, inner longitudinal, intermediate circular, and outer longitudinal layers, are distinguished.

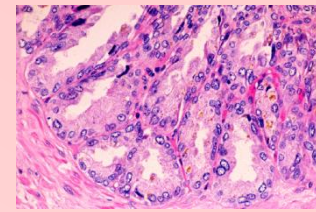
## 16-37 Seminal vesicle 2. Human, H-E stain, x 25.



- In this figure the folds of mucosa are thin and anastomose with one another forming a complex labyrinth. Smooth muscle fibers are loosely arranged around the main lumen.

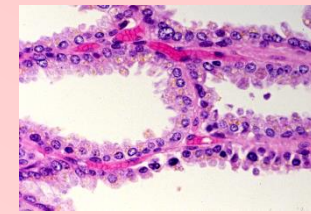


### 16-38 Seminal vesicle 3. Human, H-E stain, x 100.



- At the basis of the folds, the narrow lumina are lined by a simple cuboidal or columnar epithelium and show the glandular appearance. The epithelial cells contain often brownish granules in the apical cytoplasm; they are called lipofuscin-granules. They are now regarded as lysosomes.

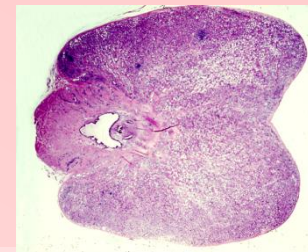
## 16-39 Seminal vesicle 4. Human, H-E stain, x 100.



- The folds of the mucous membrane anastomose with one another forming a complex labyrinth. In this figure each lumen is lined by a simple cuboidal epithelium, whose cells are performing the apocrine secretion. The lamina propria dividing each lumen is very thin and contain blood capillaries.

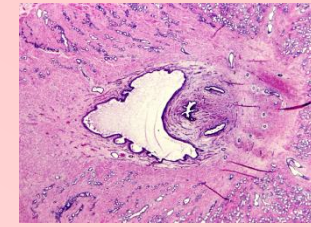


## 16-40 Prostate gland 1, Horizontal section, general view. Monkey, H-E stain, x 2.0.



- The prostate gland is a large chestnut-shaped gland attaching to the inferior aspect of the urinary bladder and its frontal portion penetrates the urethra downward, which makes a fusiform extension during the course of penetration. The posterior wall of this extension rises slightly forming a longitudinal hillock, colliculus seminalis, at the top of which is a small blind diverticulum, utriculus prostaticus, being homologous with the uterus in the female. The urethra is surrounded, together with the colliculus, by a thick dense layer of smooth muscle fibers and connective tissue fibers. Numerous thin septa radiate from this toward the surface collagen fiber capsule and divide the parenchyma into numerous lobules.
- The parenchyma of the prostate gland consists of compound tubulo-acinar glands, differing in length and degree of branching. The connective tissue filling the interstices between the glands contains a lot of smooth muscle fibers resulting in the characteristic hardness of the prostate gland.
- This is a general view of horizontal section of a monkey prostate gland, showing the general organization of the gland. Higher magnification of the urethra and colliculus seminalis is shown in 16-41.

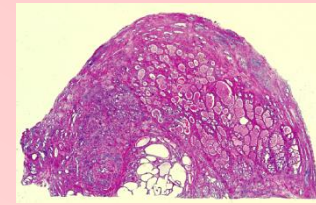
## 16-41 Prostate gland 2, Urethra and colliculus seminalis, Monkey, H-E stain, x 4.0.



- At center is the urethra, pars prostatica, triangular in shape, with its tip oriented to front. The posterior wall arises into the lumen forming a longitudinal fusiform hillock, colliculus seminalis, from the tip of which emerges a blind diverticle posteriorly, named utriculus prostaticus. This is the remnant of the embryonic Mullerian duct and regarded the homolog of uterus in the female. Posterior to the utriculus there are two ductus ejaculatorii symmetrically. In spite of their name ductus ejaculatorii have no encircling muscular coat. The urethra and colliculus seminalis are together enclosed by a very thick and dense coat consisting of smooth muscle fibers and collagen fibers, through which numerous excretory ducts radiate toward the parenchyma.

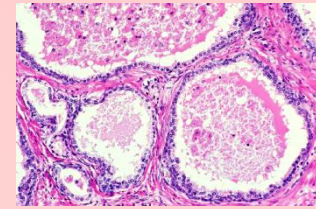


## 16-42 Prostate gland 3. General view. Human, H-E stain, x 1.8.



- This is a general view of horizontal section of a human prostate gland, consisting of a lot of small as well as large acini surrounded by a dens interstitium.

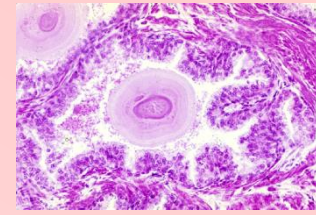
## 16-43 Prostate gland 4. Acini and interstitium. Human, H-E stain, x 25.



- The tubulo-acinar units of the gland are quite variable in form. The epithelium is usually simple cuboidal or pseudostratified columnar, but sometimes they are simple squamous in dilated or cystic region. In the interstitium there are so numerous smooth muscle fibers weaving densely, resulting in the characteristic toughness of the prostate gland. In the acinar lumen there are much excrete stained deep pink but the sperms are usually not encountered.

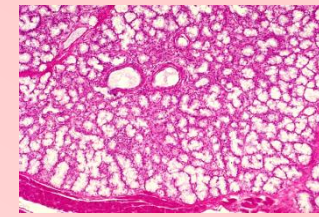


## 16-44 Prostate gland 5. Prostatic concretions. Human, H-E stain, x 64.



- In the acinar lumen, ovoid or spherical bodies with concentric laminations are often encountered. They are called prostatic concretions. These are glycoprotein in composition, their significance is unknown.

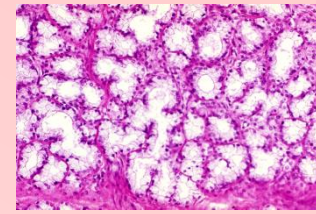
## 16-45 Glandula bulbourethralis 1. Human, H-E stain, x 25.



- The bulbourethral gland is a compound tubuloalveolar gland, green pea-sized and locating beneath the urogenital diaphragm. The gland is a mucous gland, consisting of branched and contorted tubules, and opens by a single duct into the floor of the proximal portion of the cavernous urethra. The secretion of this gland is emitted at the onset of the ejaculation.
- This figure shows the general structure of this gland, consisting of numerous branching and convoluting tubules. At the center there are two sections of large excretory ducts.

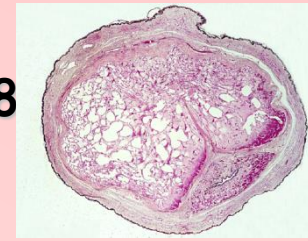


## 16-46 Glandula bulbourethralis 2. Human, H-E stain, x 64.



- Higher magnification of 16-45. The glandular epithelium, lining the lumen, consists of cuboidal or columnar cells with clear cytoplasm and basally located nuclei.

## 16-47 Penis, transverse section. General view. Human, H-E stain, x 0.8

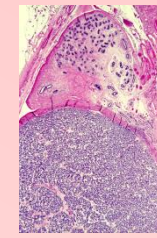


- This is the whole view of a transverse section of a human penis.
- The penis is the male copulatory organ and with skin covered cylindrical body, 15~20 cm long and 3~4 cm in diameter. The core of the penis consists of three cavernous erectile bodies, namely two dorsally located paired corpora cavernosa penis and ventrally located unpaired corpus spongiosum penis ( corpus cavernosum urethrae ), which is penetrated by the urethra throughout the length.
- The corpora cavernosa penis are enclosed by a common thick collagenous tissue, tunica albuginea, and the corpus cavernosum urethrae is also enclosed by a much thinner tunica albuginea. At the distal end the corpus cavernosum urethrae makes an expansion, the glans penis, which caps the distal ends of the corpora cavernosa. The three corpora cavernosa, are enveloped in the lump by very loose connective tissue and further on the surface by the thin skin.
- The erectile tissue of the corpora cavernosa is a sponge-like system of irregularly shaped vascular spaces fed by afferent arteries and drained by efferent veins. In the flaccid penis these cavernous spaces contain very little blood and appear as irregular narrow clefts. During erection, they expand as they become engorged with blood under pressure. The increased inflow of blood and relative restriction of outflow results in enlargement and rigidity of the erect penis.
- The male urethra serves as the terminal portion of both the urinary tract and the reproductive tract. The lining of the penile urethra, 12~14 cm in length, is stratified columnar epithelium. At its most distal portion the lining becomes into stratified squamous epithelium, which is alike to that covering the glans penis.



## 16-003 Testis of a 2.9-year-old Boy

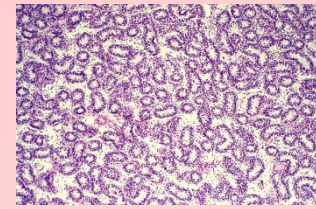
**16-48 Testis of a 2.9-year-old boy, 1. Sagittal section, general view.  
Human, H-E stain, x10.**



- This is the upper one third of the sagittal section of testis of a 2.9-year-old boy. In this testis seminiferous tubules and tunica albuginea are already well developed, whereas the rete testis, ductuli efferentes testis and ductus epididymidis are poorly developed.

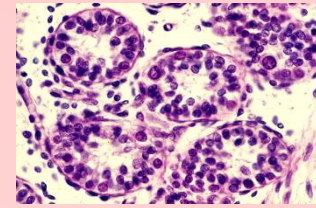


## 16-49 Testis of a 2.9-year-old boy, 2. Human, H-E stain, x 25.



- The seminiferous tubules are numerous but separated by the wide interstitium, resulting in a loose appearance, as a whole. In the interstitial spaces the interstitial cells are not encountered.

## 16-50 Testis of a 2.9-year-old boy, 2. Human, H-E stain, x 160.



- The seminiferous tubules are lined by two layers of epithelial cells, among that a few primordial germ cells are scattered (arrows). In the very loose interstitial connective tissue, no cluster of interstitial cells of Leydig is encountered.