

14-00

Respiratory System

14 Respiratory System 4

Menu 1 / 2

[14-00.](#) Respiratory System

[14-001.](#) Nasal Cavity

[14-01.](#) Nasal cavity, frontal section. Human newborn, H-E stain, x 1.3.

[14-02.](#) Concha nasalis media, transverse section. Human, H-E stain, x 2.7.

[14-03.](#) Mucous membrane of nasal concha, 1. Human, H-E stain, x 10.

[14-04.](#) Mucous membrane of nasal concha, 2. Human, H-E stain, x 64.

[14-05.](#) Epithelium of concha nasalis media. Human, H-E stain, x 160.

[14-06.](#) Epithelium of the respiratory portion. Human, H-E stain, x 250.

[14-07.](#) Mucous membrane of the olfactory area, 1. Human, H-E stain, x 40.

[14-08.](#) Olfactory epithelium and olfactory glands, 1. Human, H-E stain, x 160.

[14-09.](#) Mucous membrane of the olfactory area, 2. Monkey, H-E stain, x 64.

[14-10.](#) Olfactory epithelium and olfactory glands, 2. Monkey, H-E stain, x 160.

[14-002.](#) Larynx

[14-11.](#) Epiglottis, sagittal section, 1, general view. Human, H-E section, x 2.5.

[14-12.](#) Epiglottis, sagittal section, 2 Human, H-E stain, x 9.0.

[14-13.](#) Larynx, frontal section. General view. Human, H-E stain, x 2.5.

[14-14.](#) Plica vocalis, frontal section. Human, H-E stain, x 10.

[14-003.](#) Trachea

[14-15.](#) Trachea. transverse section. General view. Human, H-E section, x 1.2.

[14-16.](#) Wall of the trachea. General view. Human, H-E stain, x 3.0.

[14-17.](#) Cartilage of the trachea. Human, H-E stain, x 64.

[14-18.](#) Mucous membrane of the trachea. Human, M-G stain, x 50.

[14-19.](#) Tracheal gland. Human, H-E stain, x 25.

[14-004.](#) Lung

[14-20.](#) Lung, 1. General view. Monkey, H-E stain, x 4.0.

[14-21.](#) Lung, 2. Intrapulmonary bronchus. Monkey, H-E stain, x 10.

[14-22.](#) Lung, 3. Terminal bronchiole. Monkey, H-E stain, x 10.

[14-23.](#) Lung, 4. Respiratory bronchiole and alveoli, 1. Monkey, H-E stain, x 12.5.

[14-24.](#) Lung, 5. Respiratory bronchiole and alveoli, 2. Monkey, H-E stain, x 25.

[14-25.](#) Lung, 6. Respiratory bronchiole and alveoli, 3. Monkey, H-E stain, x 64.

[14-26.](#) Lung, 7. Alveolar duct and alveoli, 1. Monkey, H-E stain, x 64.

14 Respiratory System 4

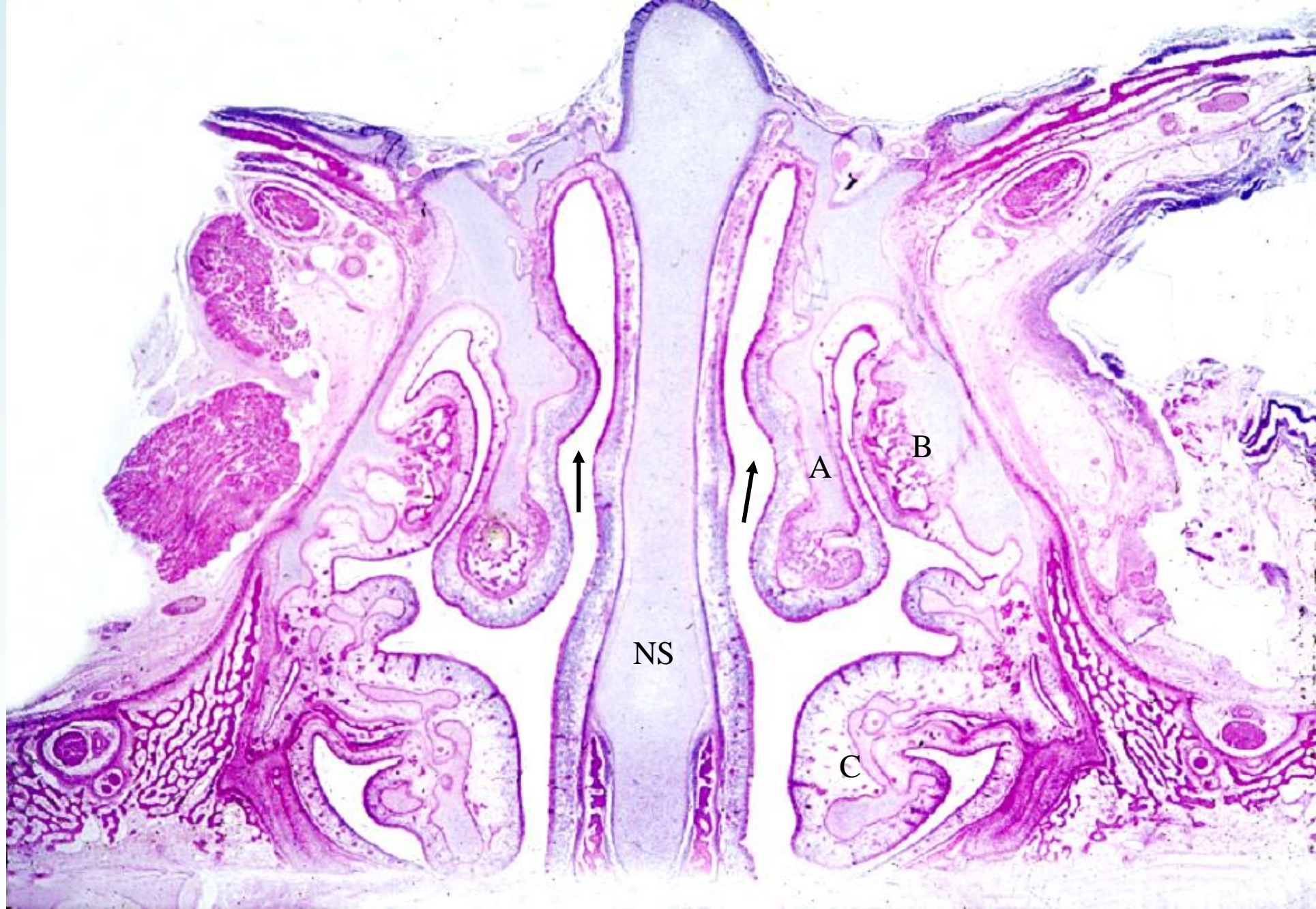
Menu 2/2

- [14-27.](#) Scheme showing the branching of the respiratory tree.
- [14-28.](#) Scheme showing the ultra fine structure of the alveolar epithelium.
- [14-29.](#) Human lung, 1. General view. H-E stain, x 1.3.
- [14-30.](#) Human lung, 2. Pleura and alveoli. H-E stain, x 25.
- [14-31.](#) Human lung, 3. Terminal bronchulus and alveoli. H-E stain, x 25.
- [14-32.](#) Human lung, 4. General view. H-E stain, x 10.
- [14-33.](#) Human lung, 5. Terminal bronchiole and respiratory bronchiole. H-E stain, x 25.
- [14-34.](#) Human lung, 6. Respiratory bronchiole and alveoli. H-E stain, x64.
- [14-35.](#) Human lung, 7. Terminal bronchiole and alveoli, 1. H-E stain, x 160.
- [14-36.](#) Human lung, 8. Terminal bronchiole and alveoli, 2. H-E stain, x 160.
- [14-37.](#) Human lung, 9. Alveolar duct and alveoli, 1. H-E stain, x 33.
- [14-38.](#) Human lung, 10. Alveolar duct and alveoli, 2. H-E stain, x 64.
- [14-39.](#) Human lung, 11. Alveolar sac and alveoli. H-E stain, x 25.
- [14-40.](#) Alveoli, 1. Human, H-E stain, x 100.
- [14-41.](#) Alveoli, 2. Human, H-E stain, x 100.
- [14-42.](#) Alveoli, 3. Human, H-E stain, x 250.
- [14-43.](#) Alveoli, 4. Human, H-E stain, x 250.

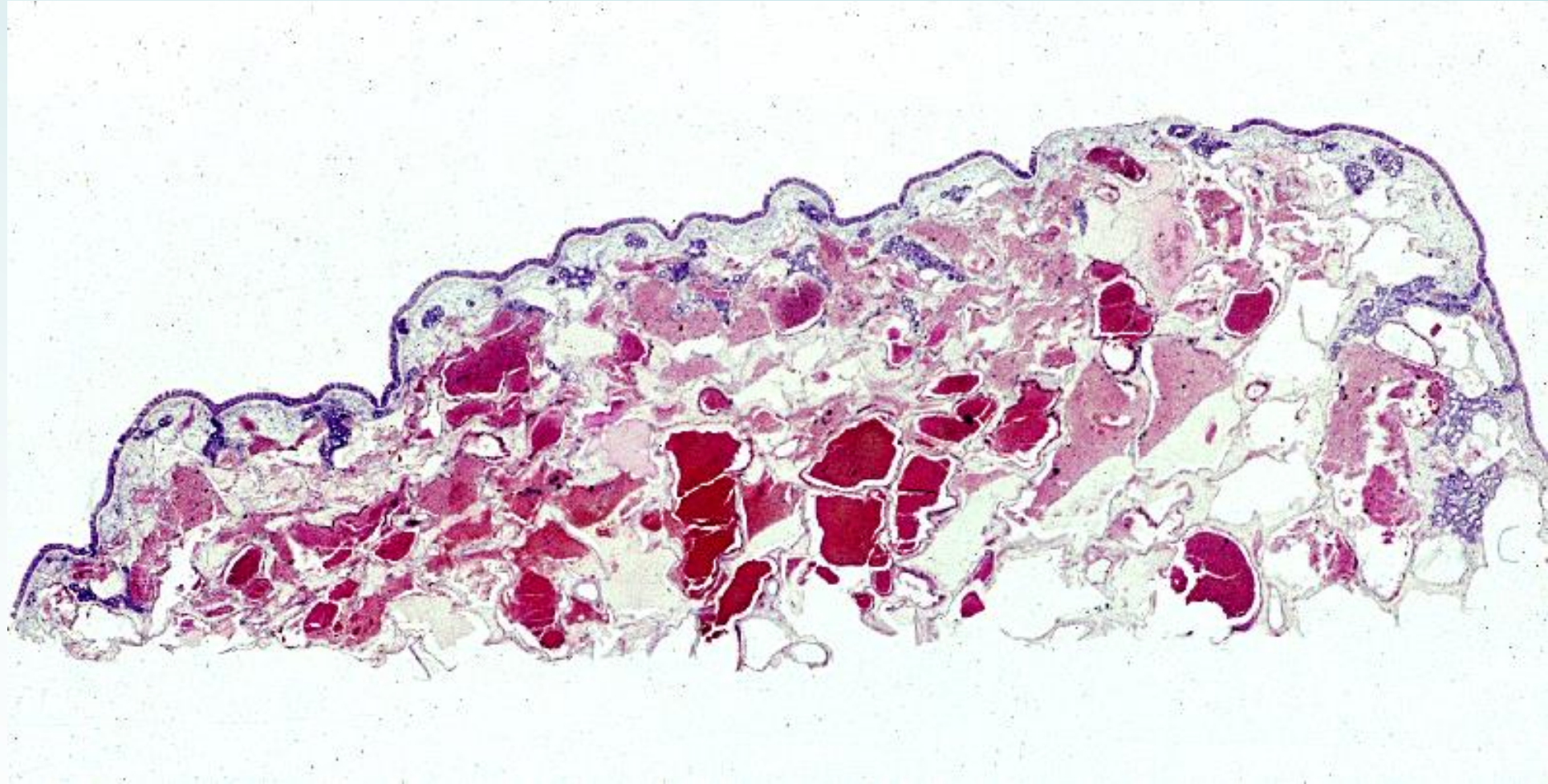
- [14-44.](#) Capillary network in the alveolar wall. Human, infusion with cinnabar. x 64.
- [14-45.](#) Elastic fibers in the alveolar wall. Human, resorcin-fuchsin stain, x 64.
- [14-46.](#) Lung of embryo, 1. Monkey, H-E stain, x 25.
- [14-47.](#) Lung of embryo, 2. Monkey, H-E stain, x 160.

14-001

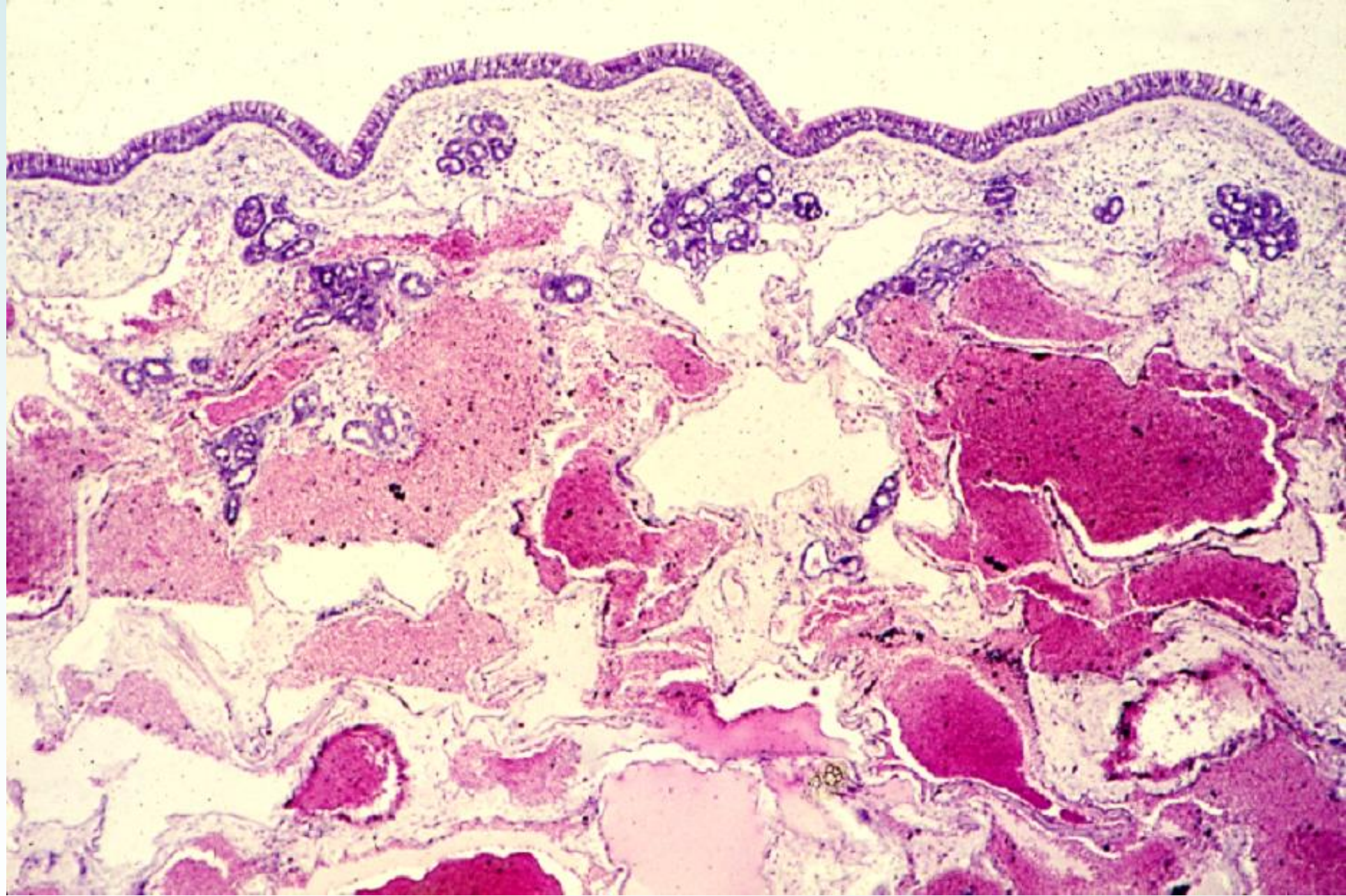
Nasal Cavity



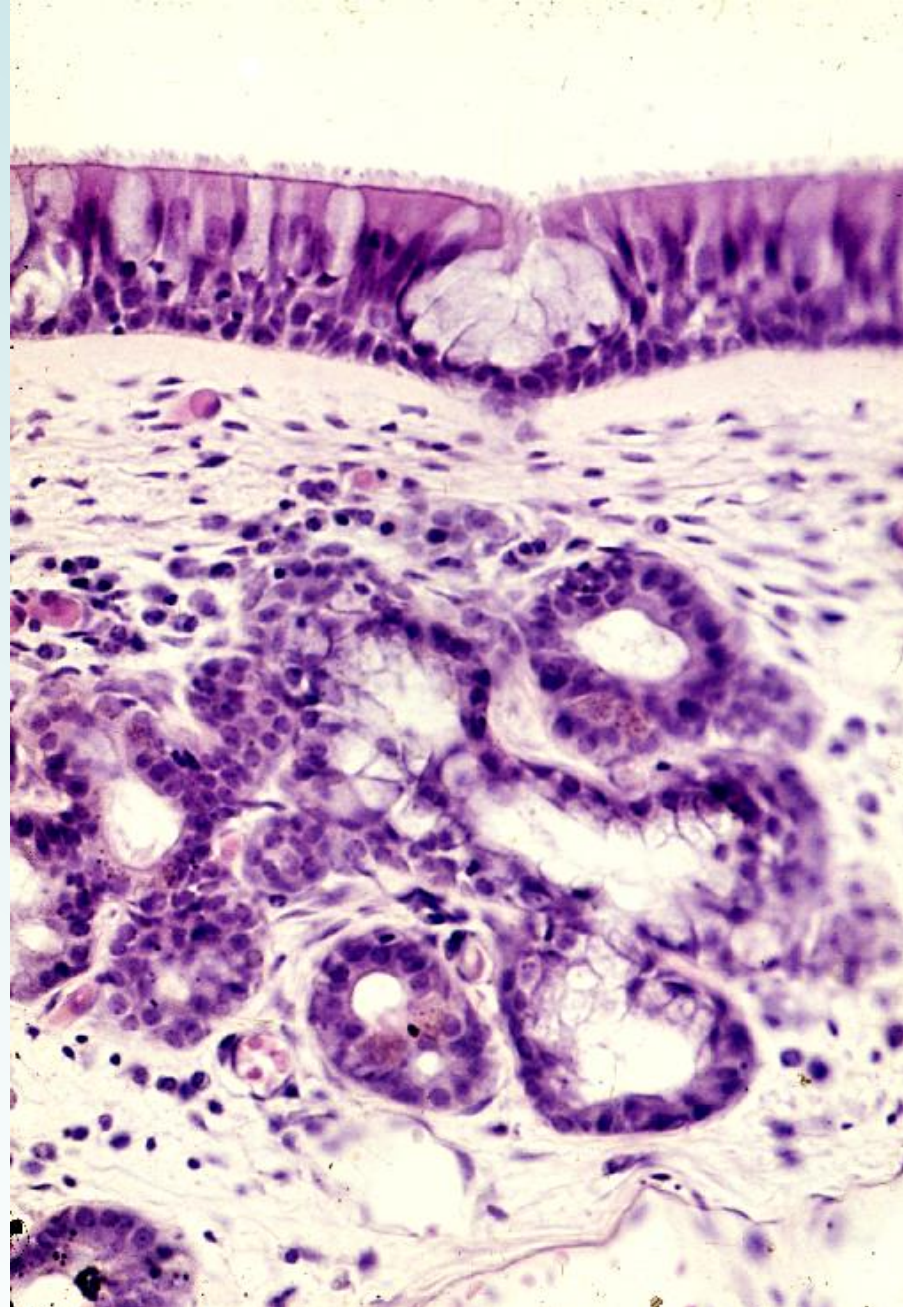
14-01 Nasal cavity, frontal section. Human newborn, H-E stain, x 1.3.



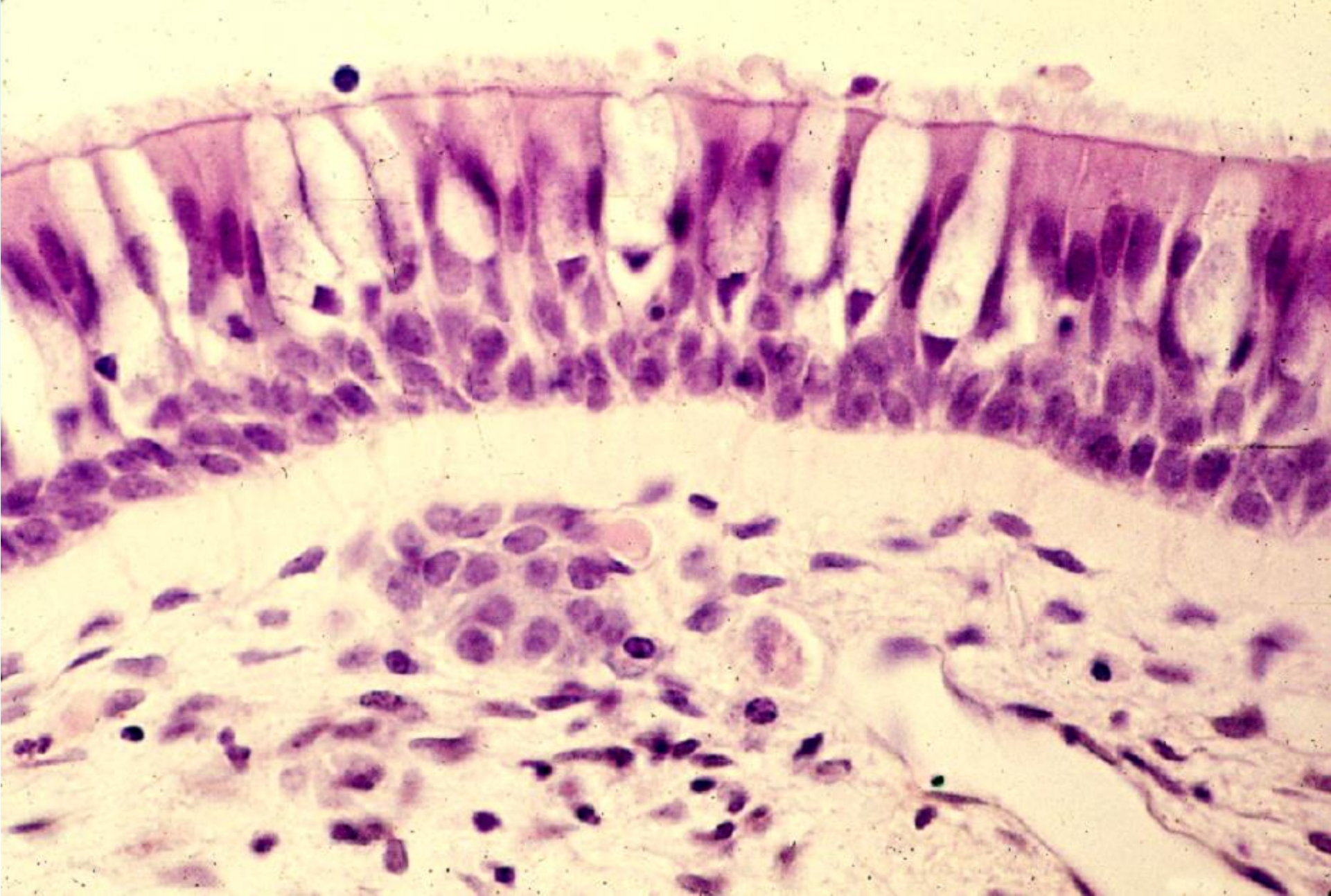
14-02 Concha nasalis media, transverse section. Human, H-E stain, x 2.7.



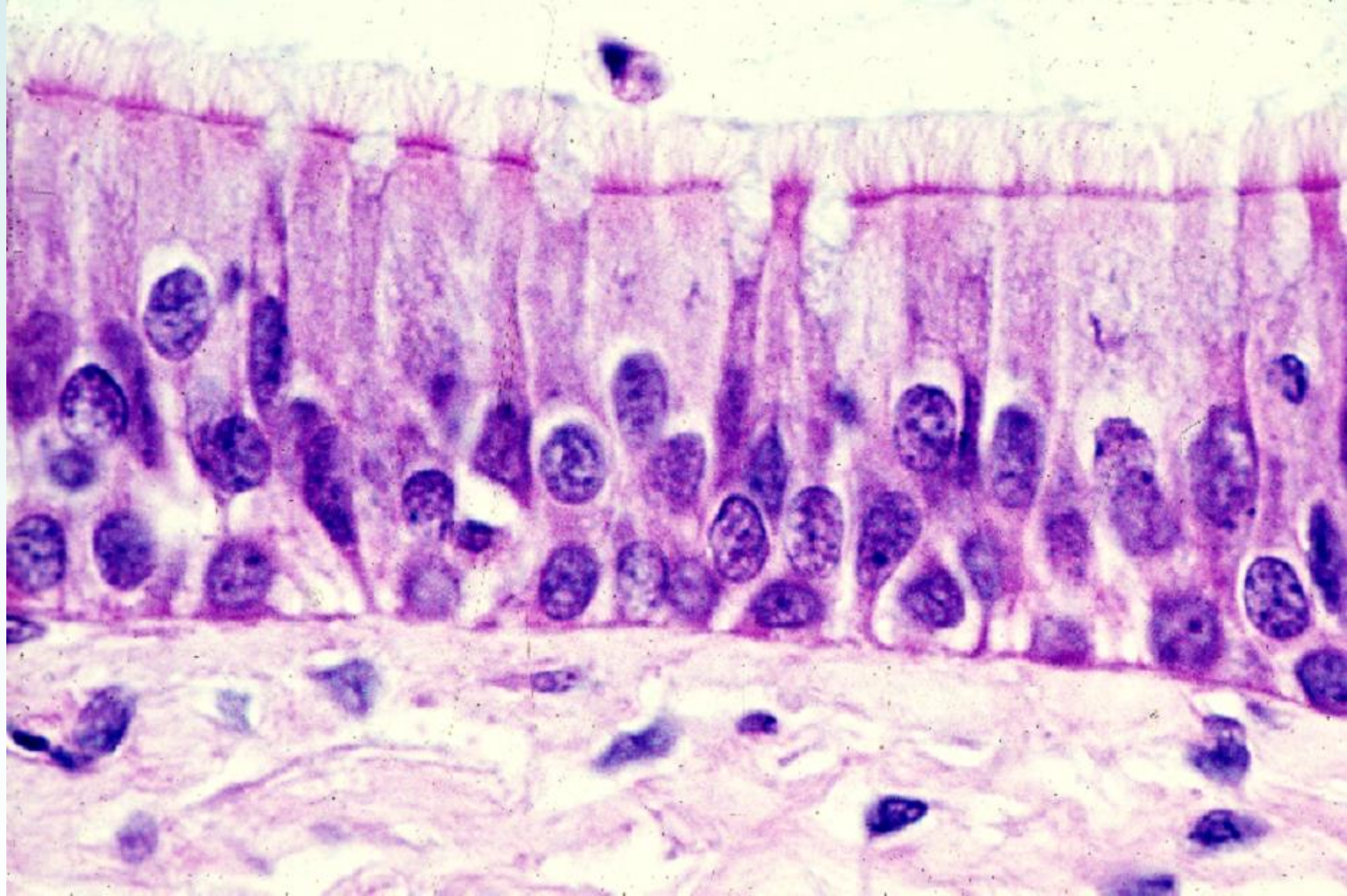
14-03 Mucous membrane of nasal concha, 1. Human, H-E stain, x 10.



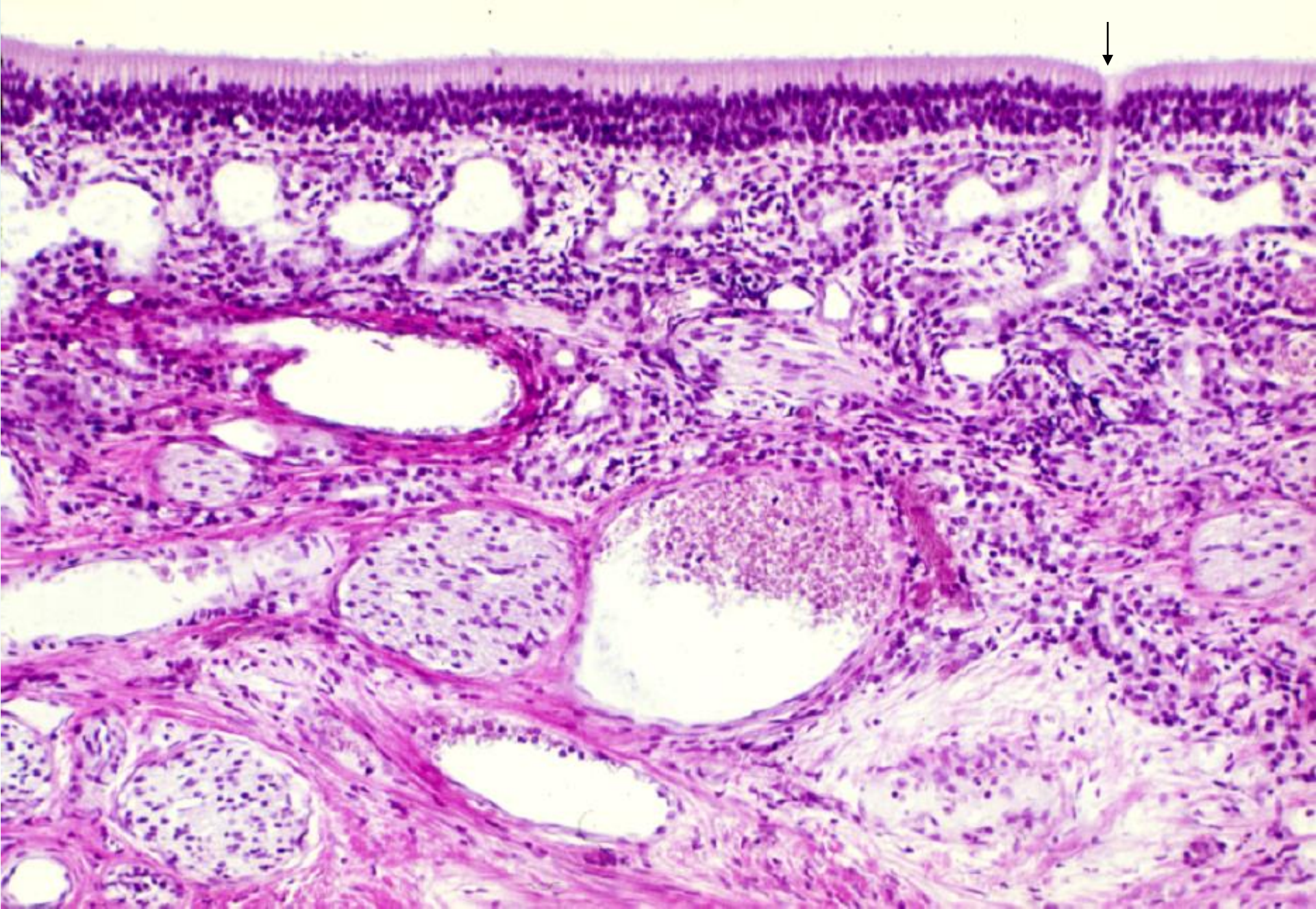
14-04 Mucous membrane of nasal concha, 2. Human, H-E stain, x 64.



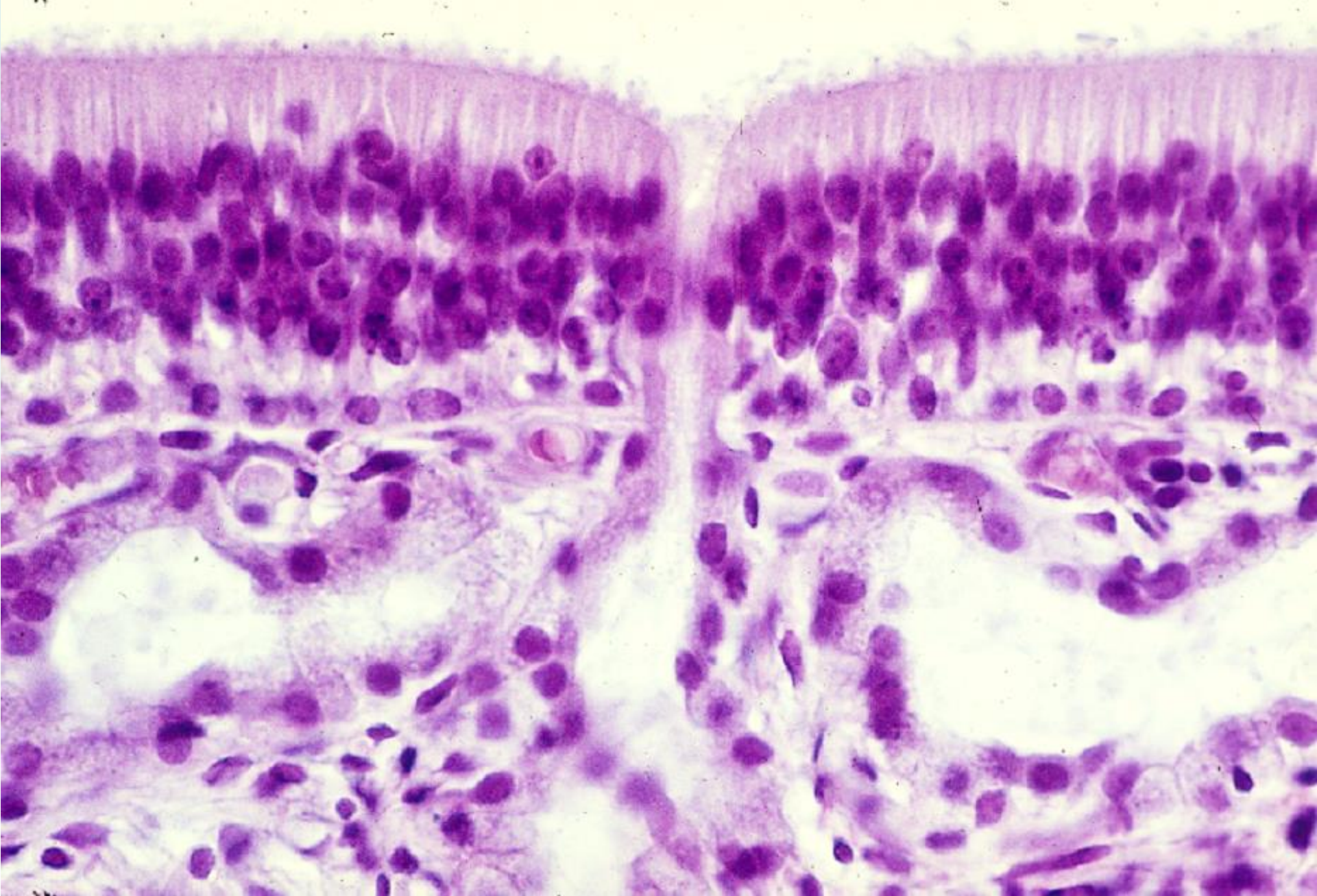
14-05 Epithelium of concha nasalis media. Human, H-E stain, x 160.



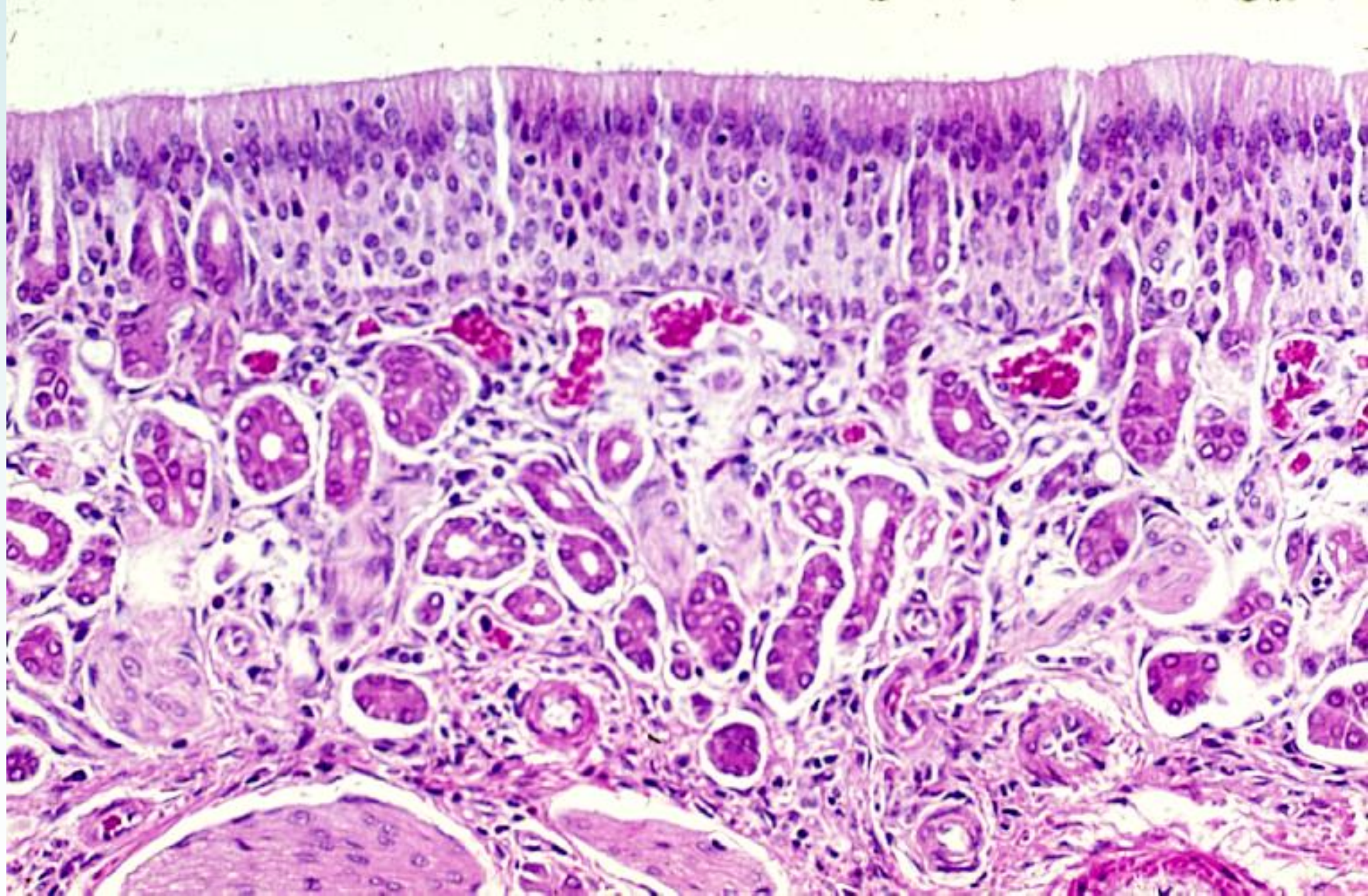
14-06 Epithelium of the respiratory portion. Human, H-E stain, x 250.



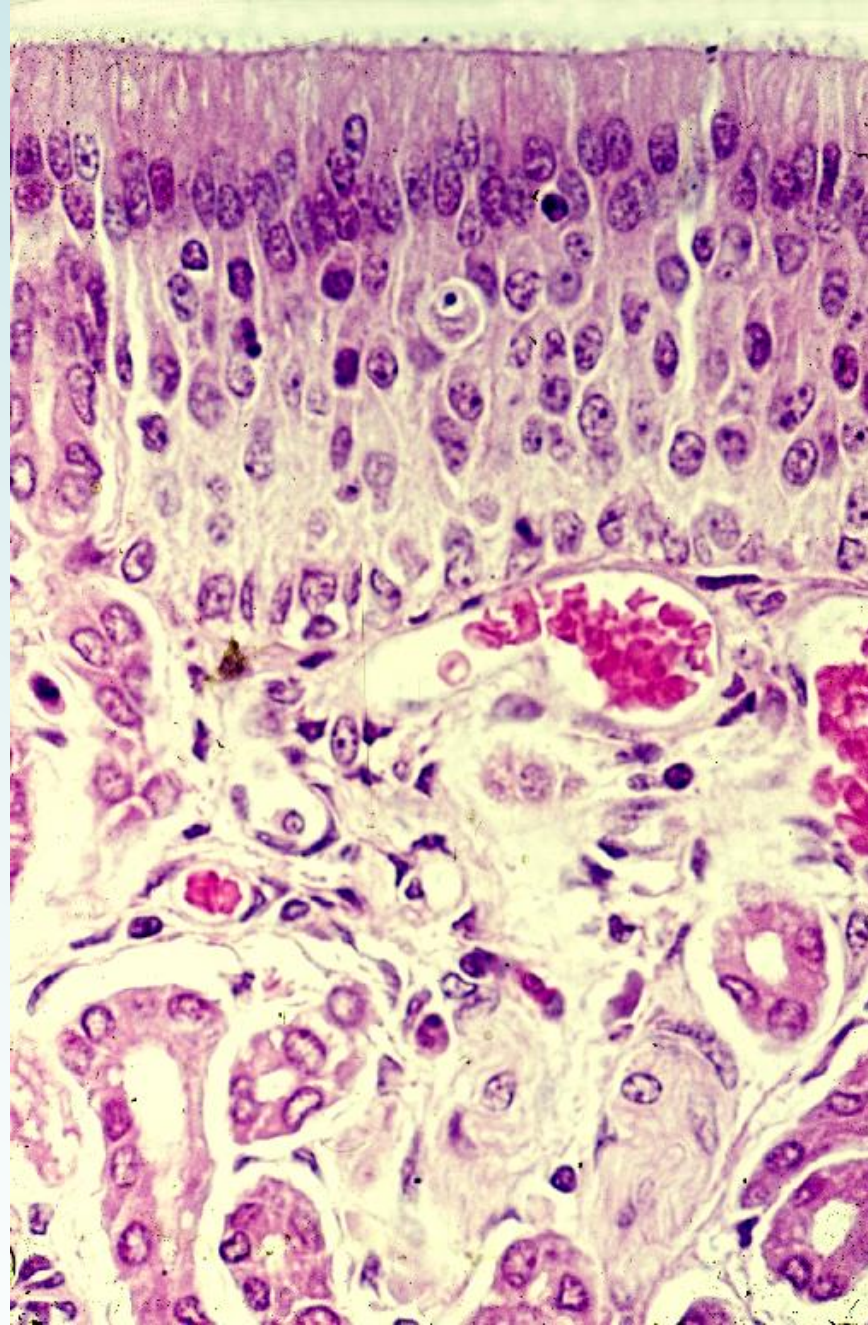
14-07 Mucous membrane of the olfactory area, 1. Human, H-E stain, x 40.



14-08 Olfactory epithelium and olfactory glands, 1. Human, H-E stain, x 160.



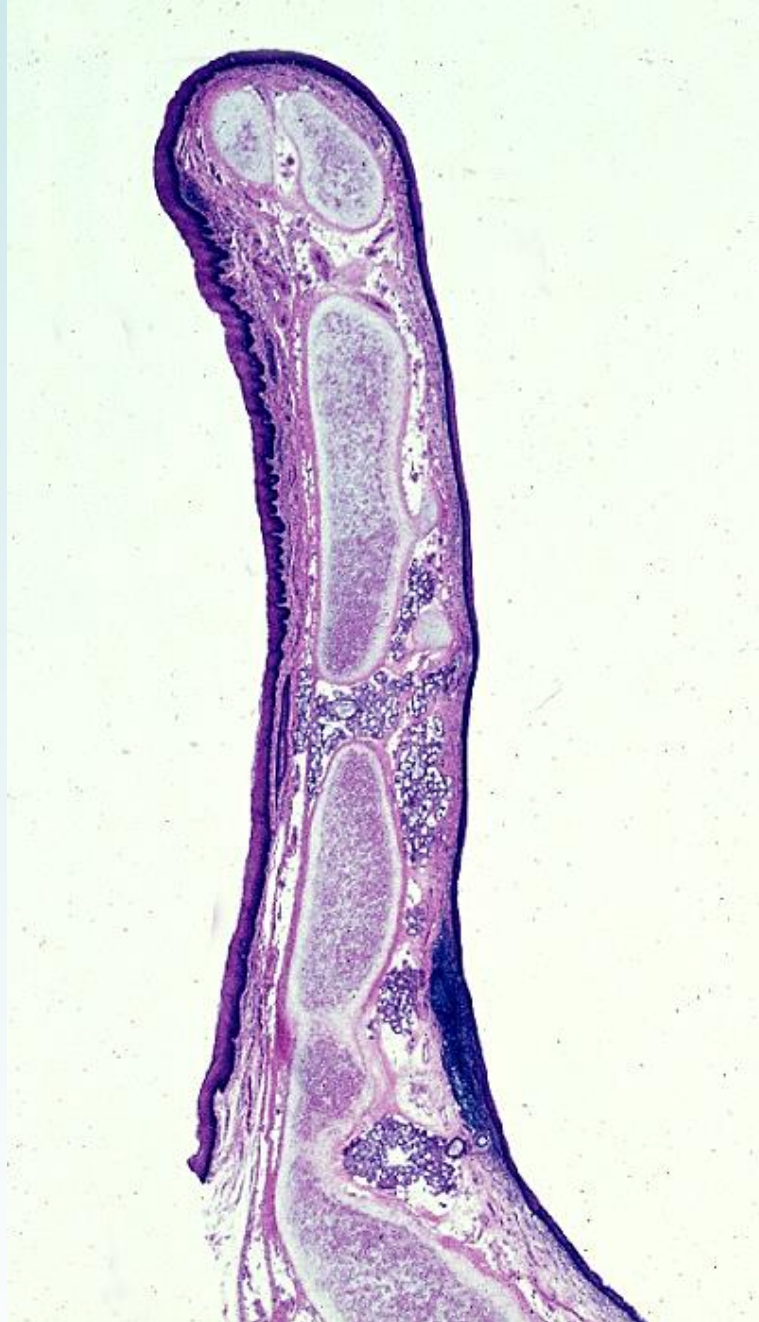14-09 Mucous membrane of the olfactory area, 2. Monkey, H-E stain, x 64.



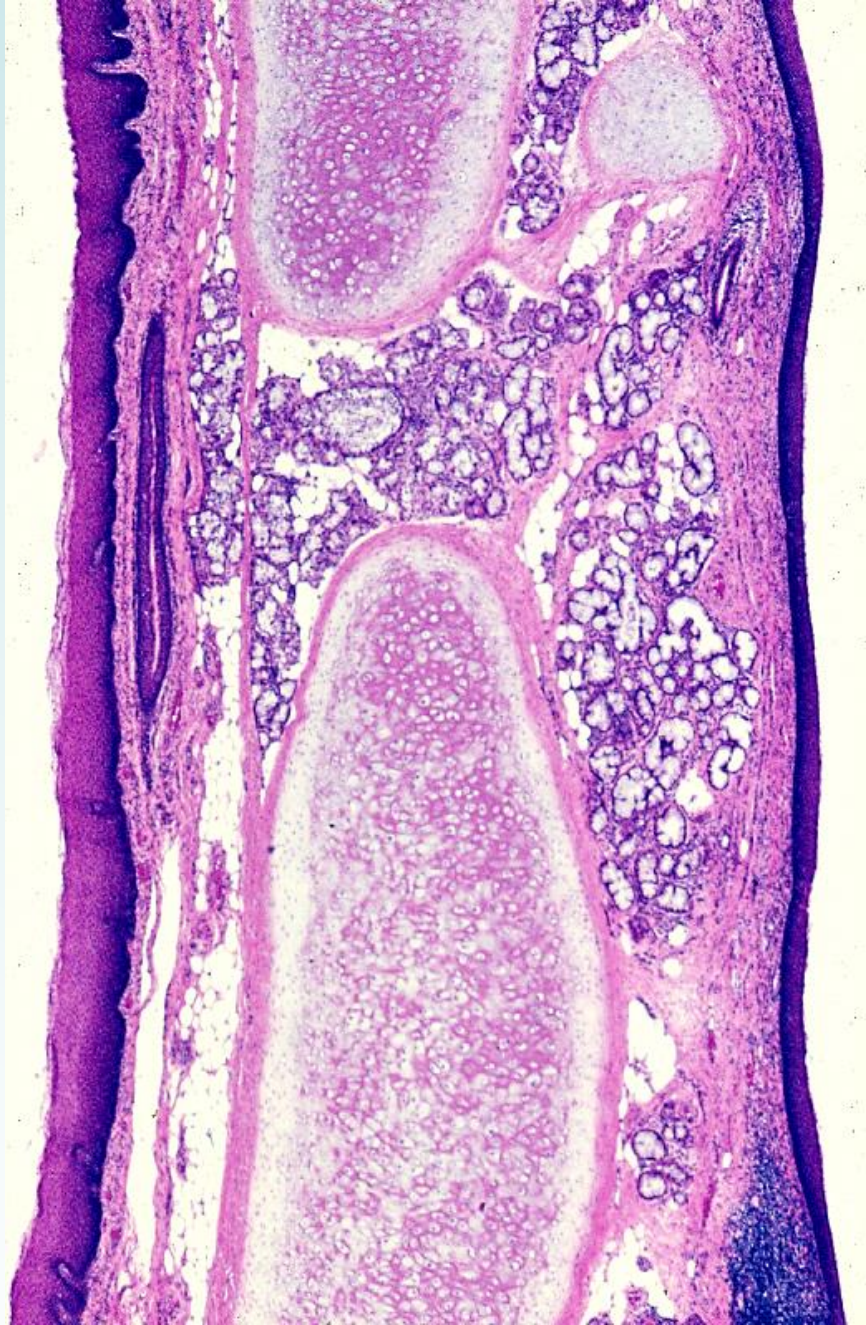14-10 Olfactory epithelium and olfactory glands, 2. Monkey, H-E stain, x 160.

14-002

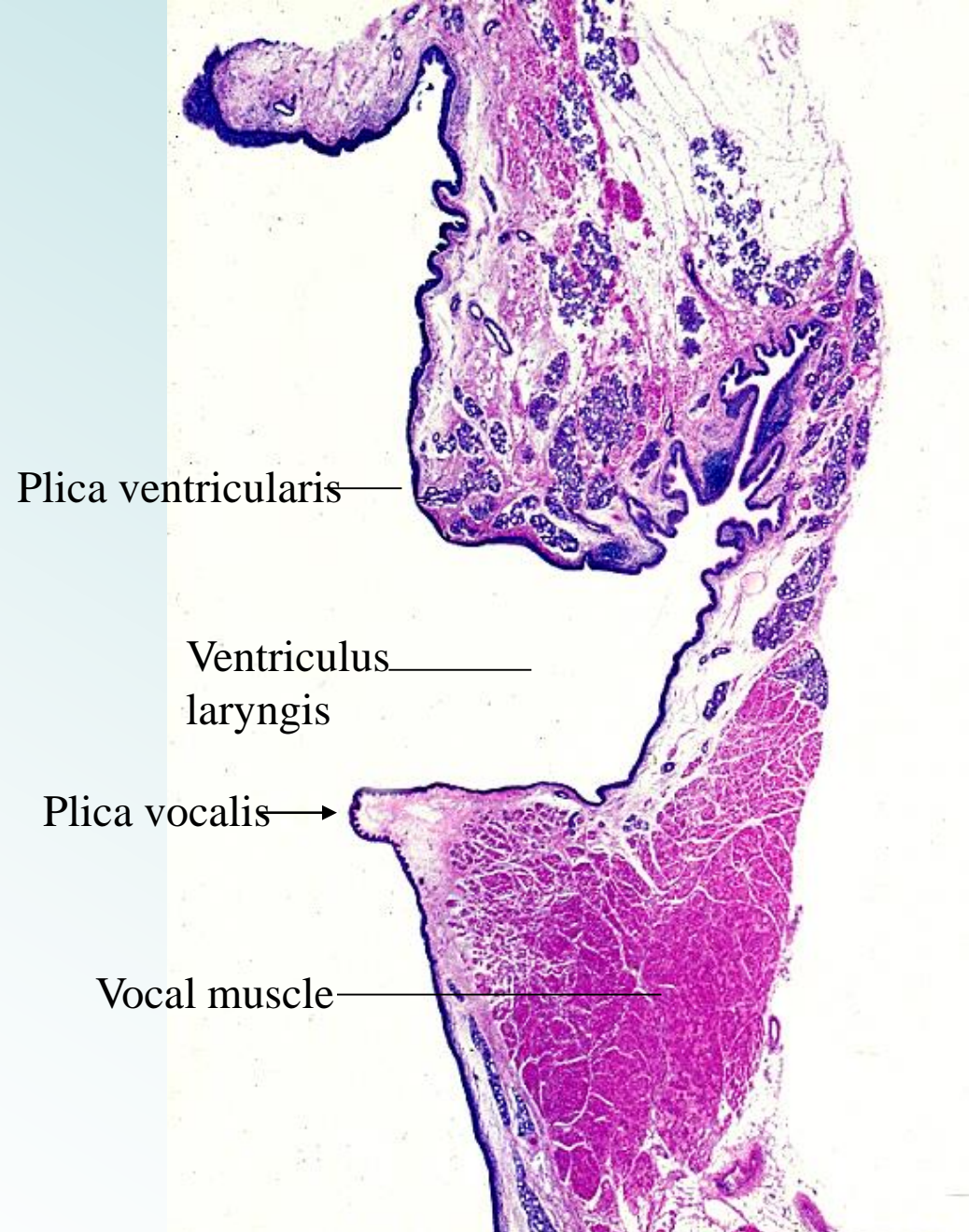
Larynx



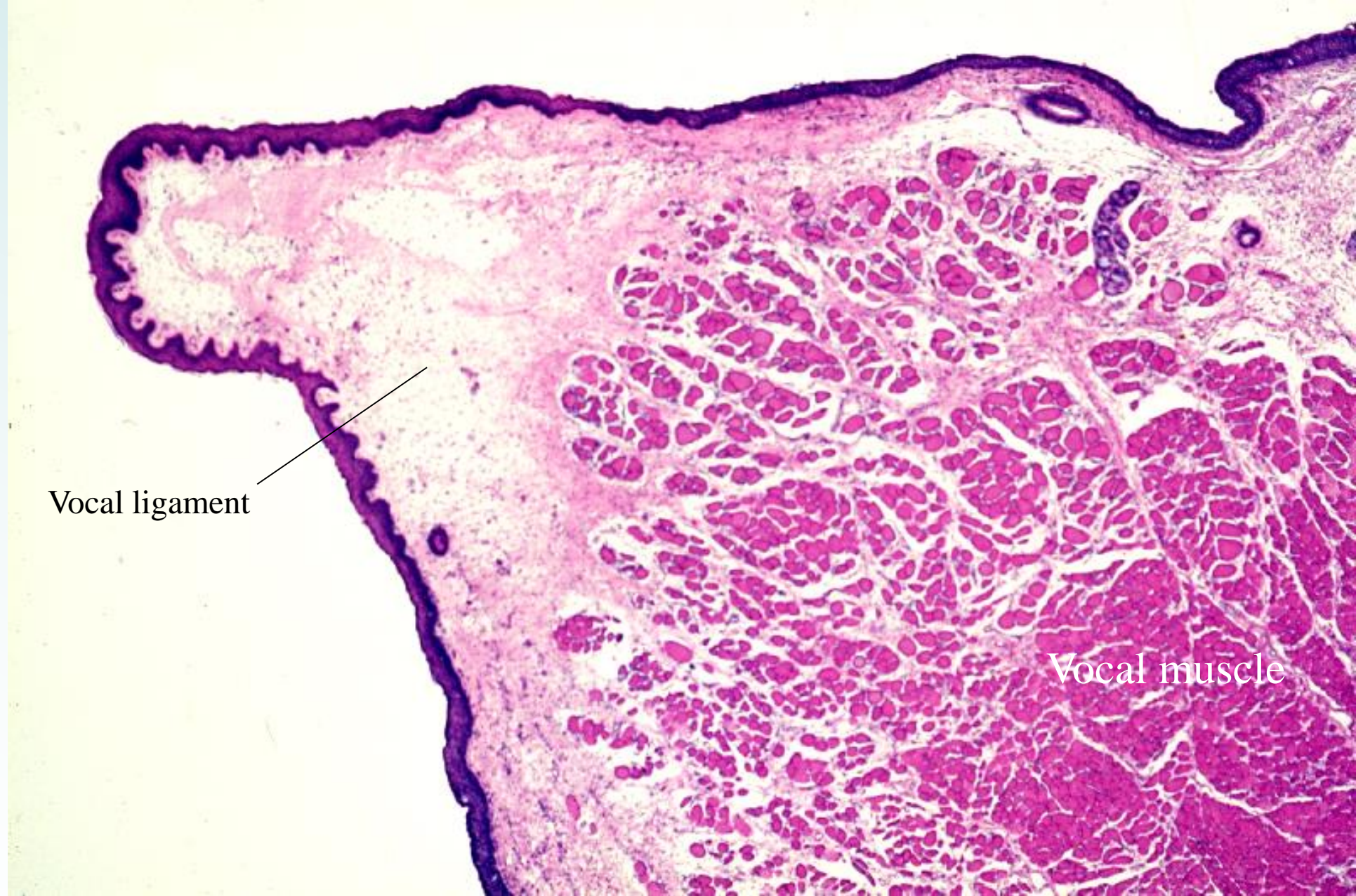
14-11 Epiglottis, sagittal section, 1, general view. Human, H-E section, x 2.5.



14-12 Epiglottis, sagittal section, 2 Human, H-E stain, x 9.0.



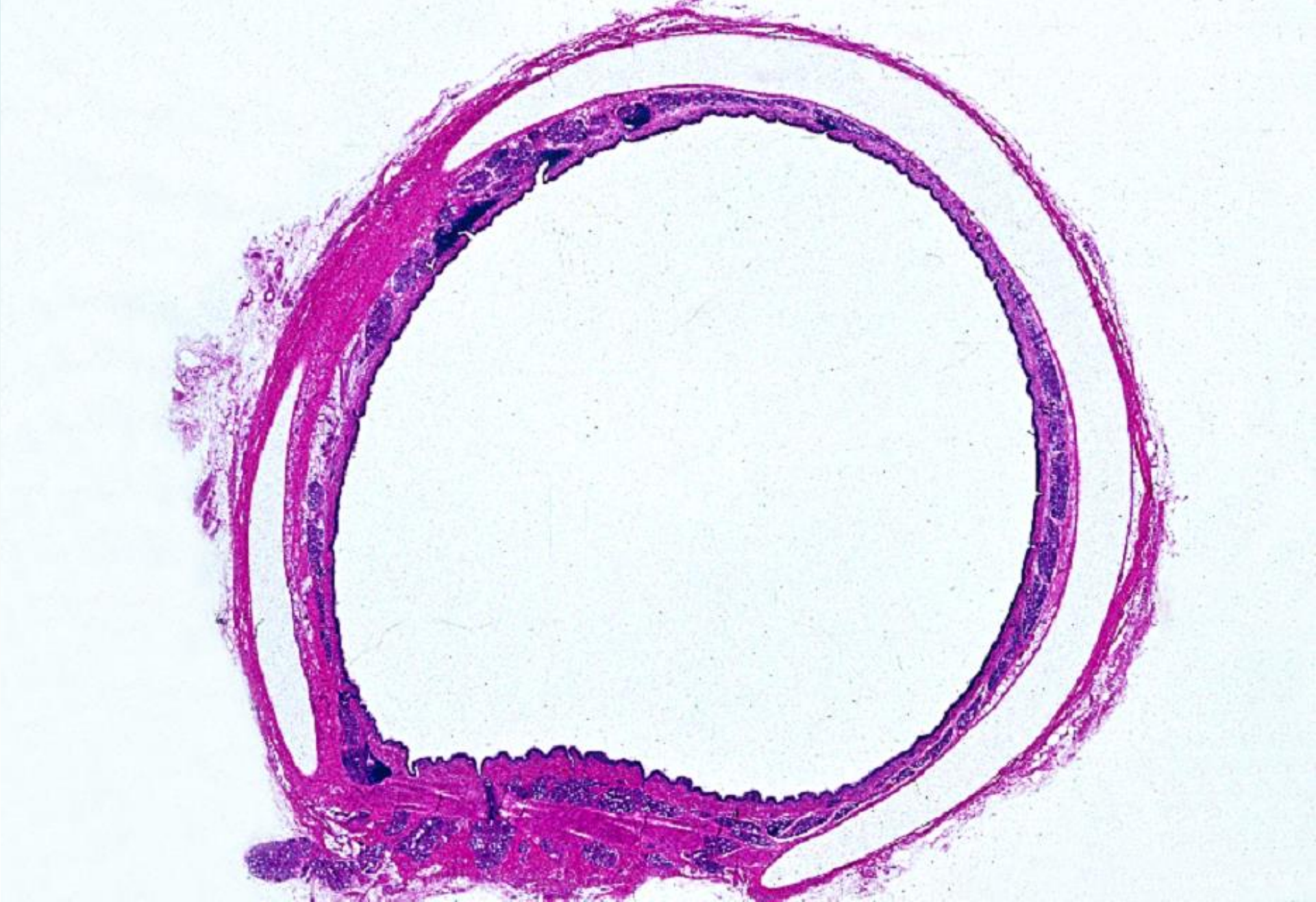14-13 Larynx, frontal section. General view. Human, H-E stain, x 2.5.



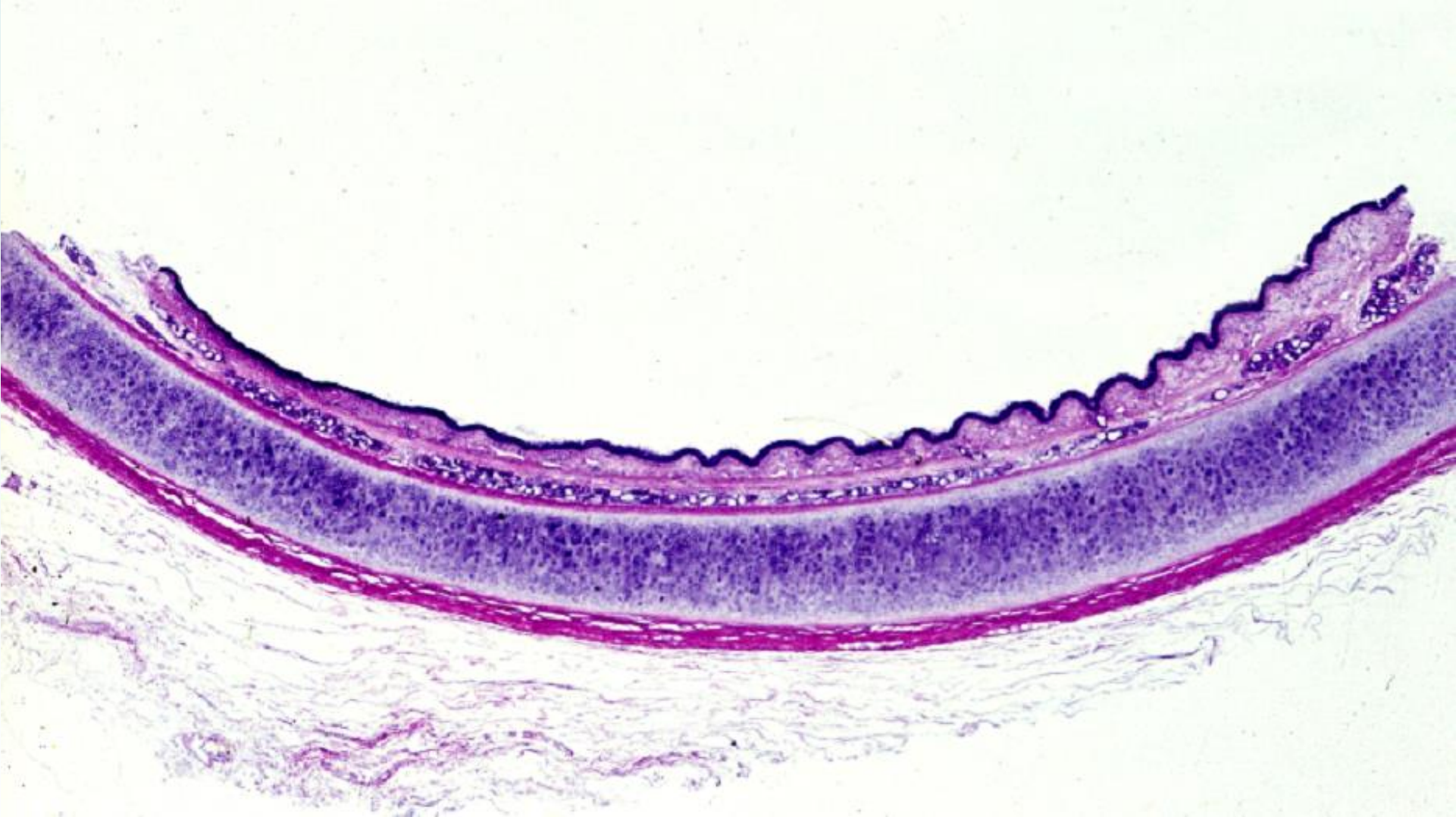14-14 Plica vocalis, frontal section. Human, H-E stain, x 10.

14-003

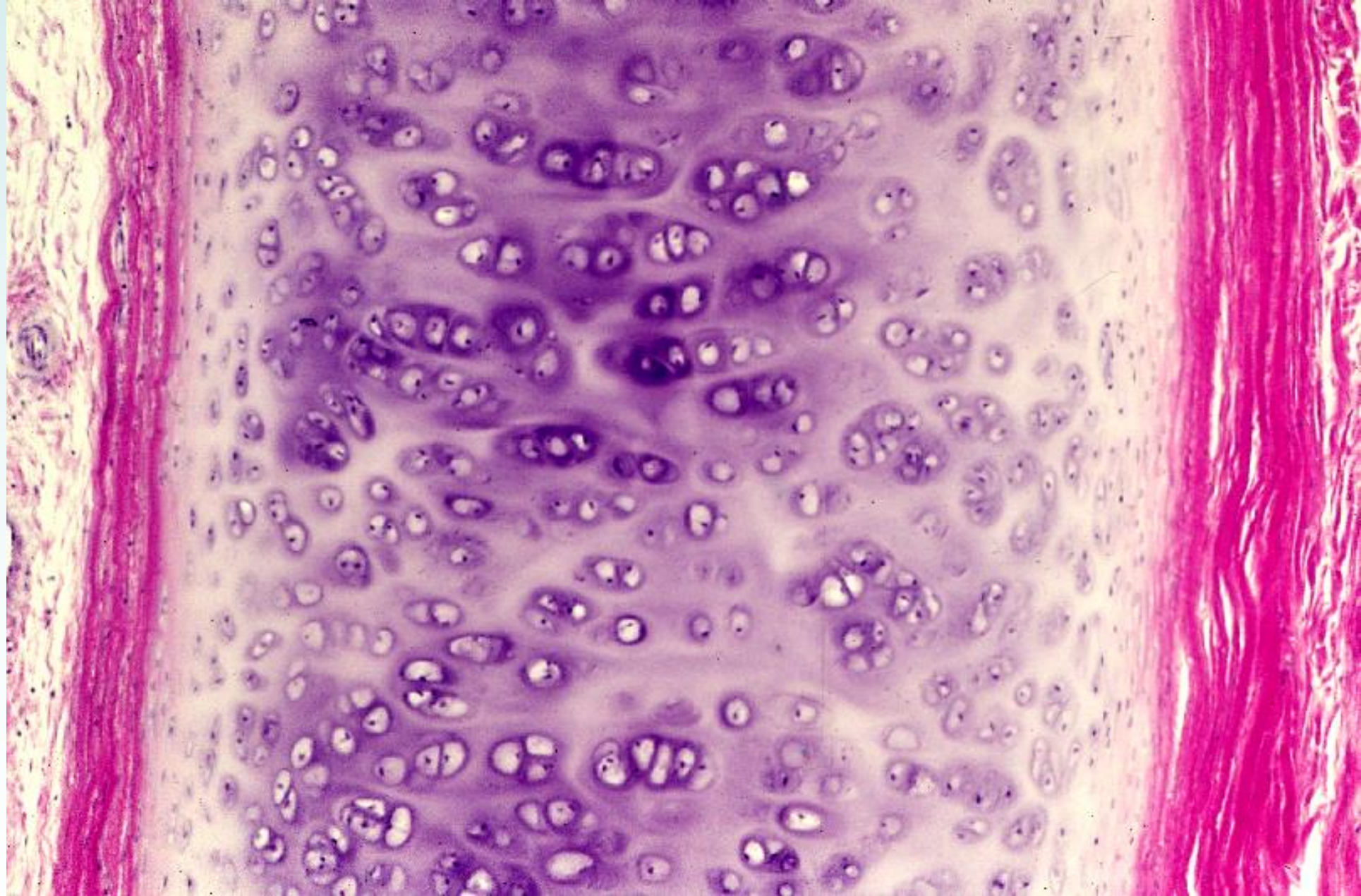Trachea



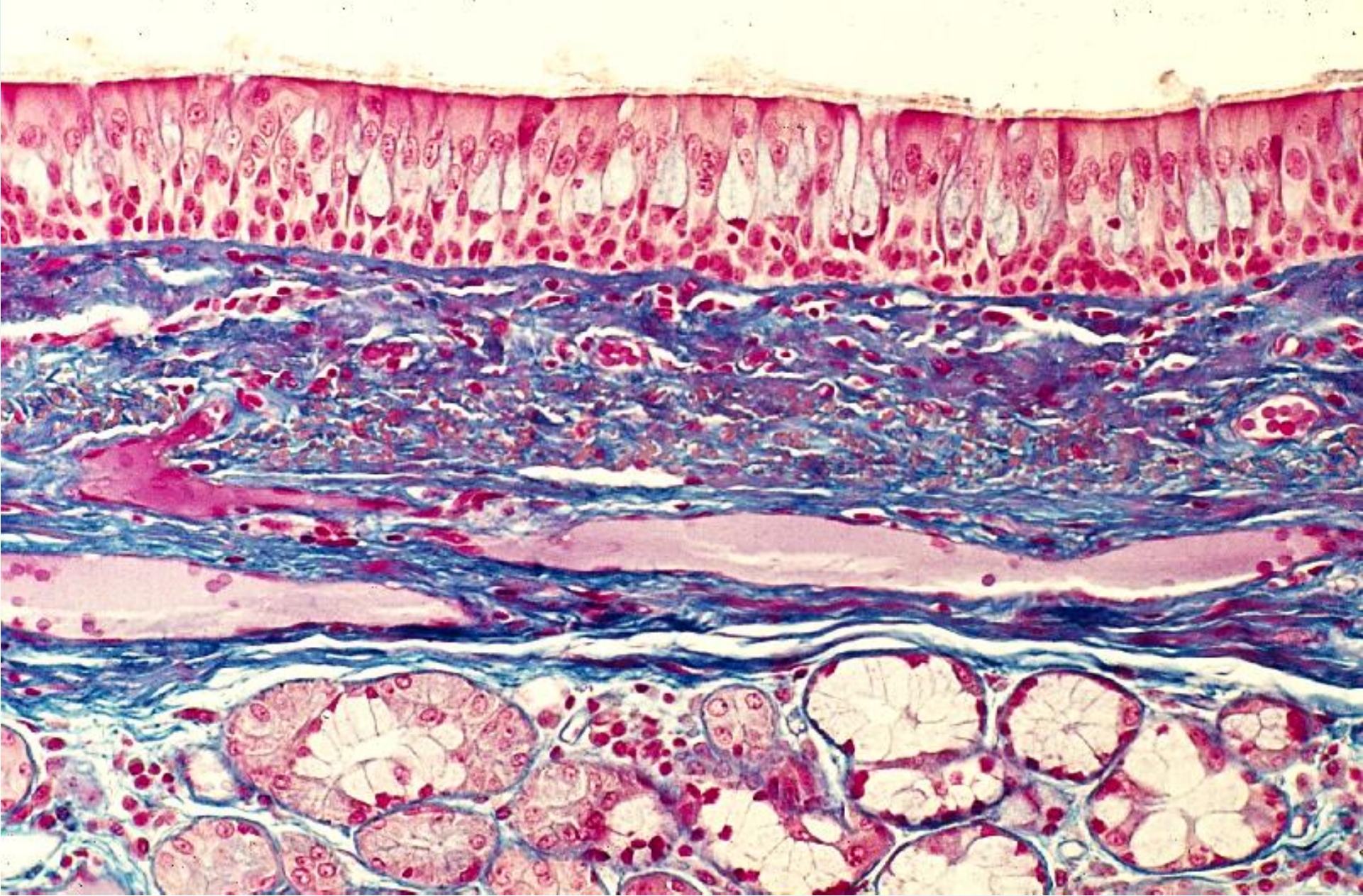
14-15 Trachea. transverse section. General view. Human, H-E section, x 1.2.



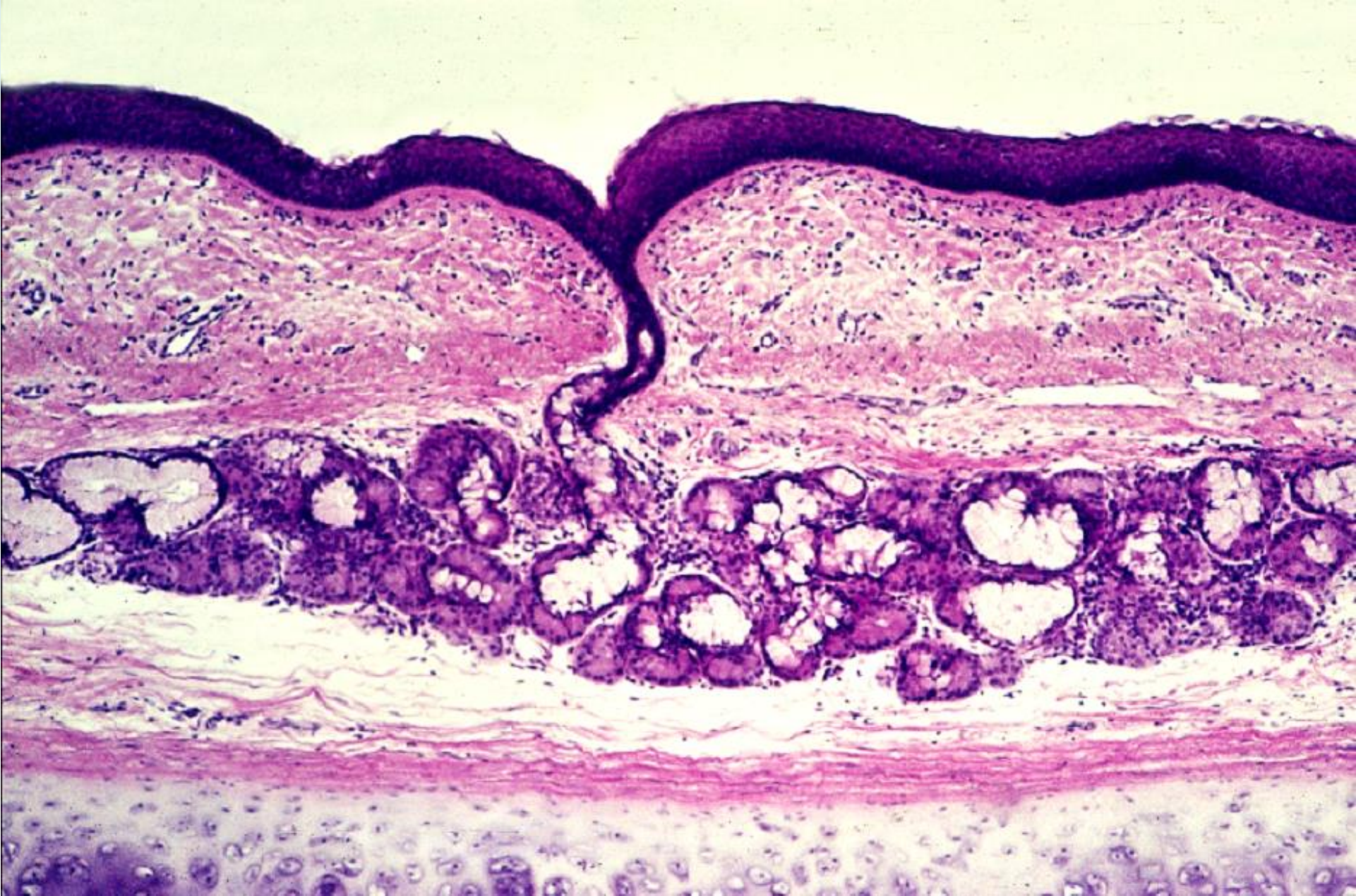
14-16 Wall of the trachea. General view. Human, H-E stain, x 3.0.



14-17 Cartilage of the trachea. Human, H-E stain, x 64.



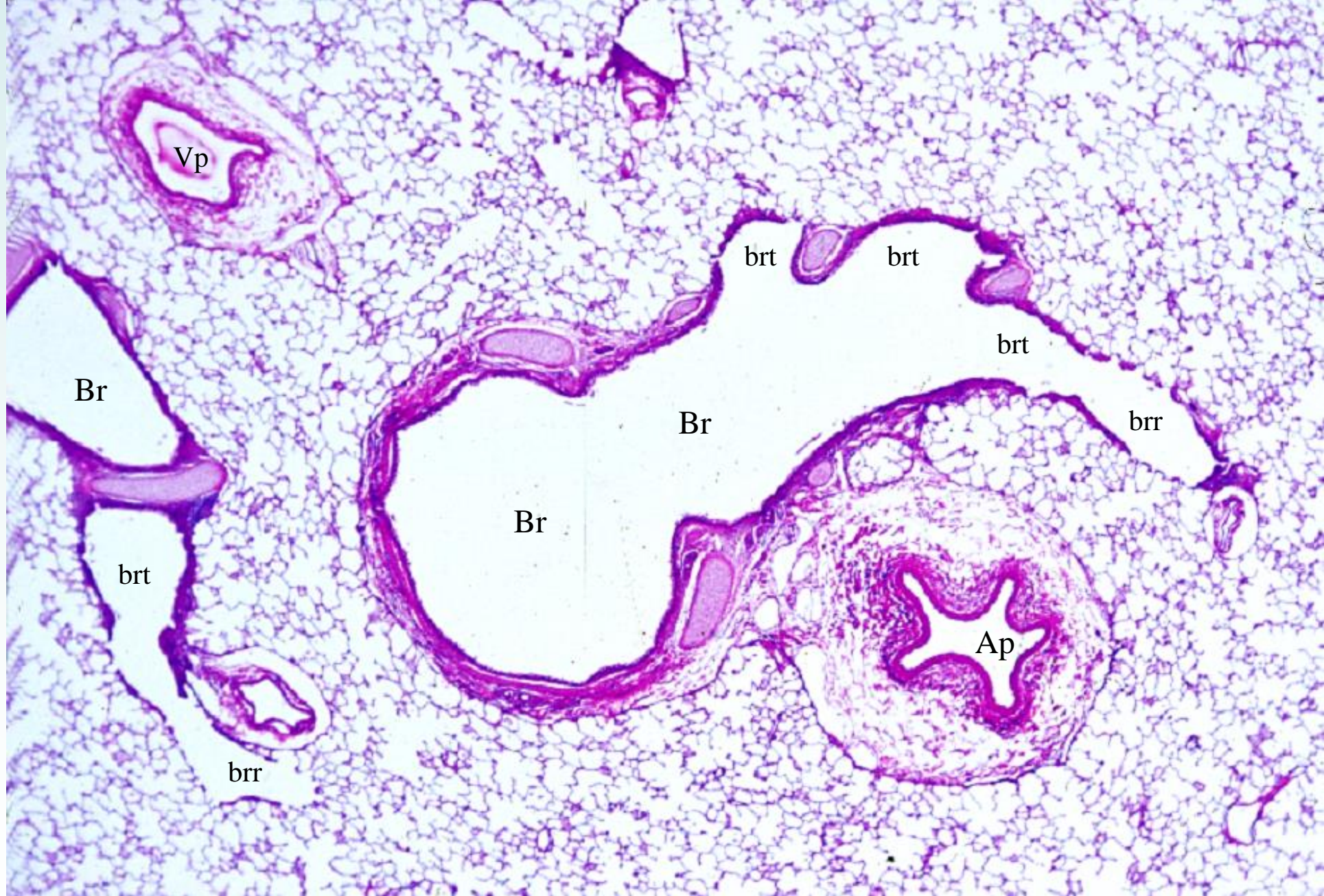
14-18 Mucous membrane of the trachea. Human, M-G stain, x 50.



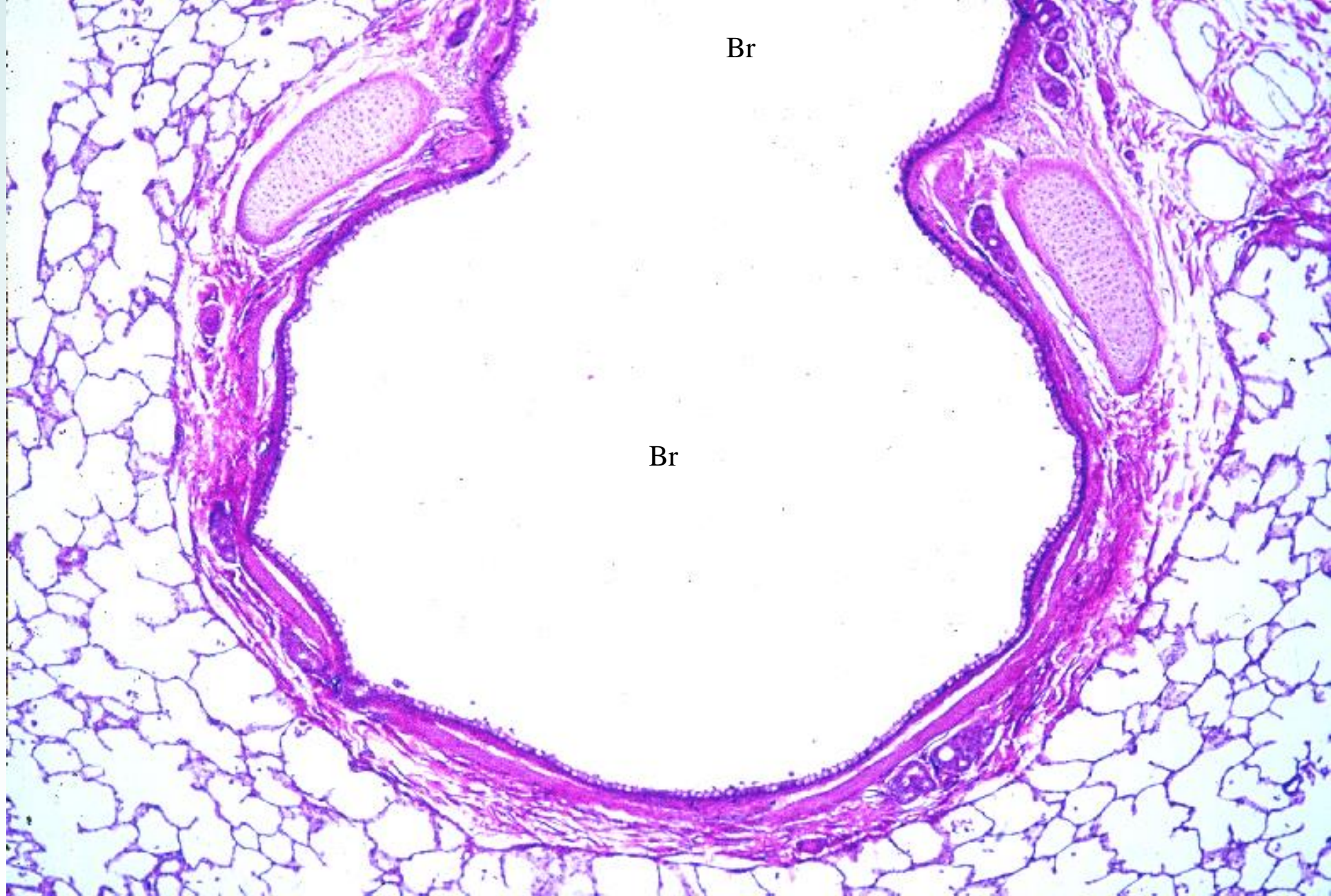
14-19 Tracheal gland. Human, H-E stain, x 25.

14-004

Lung



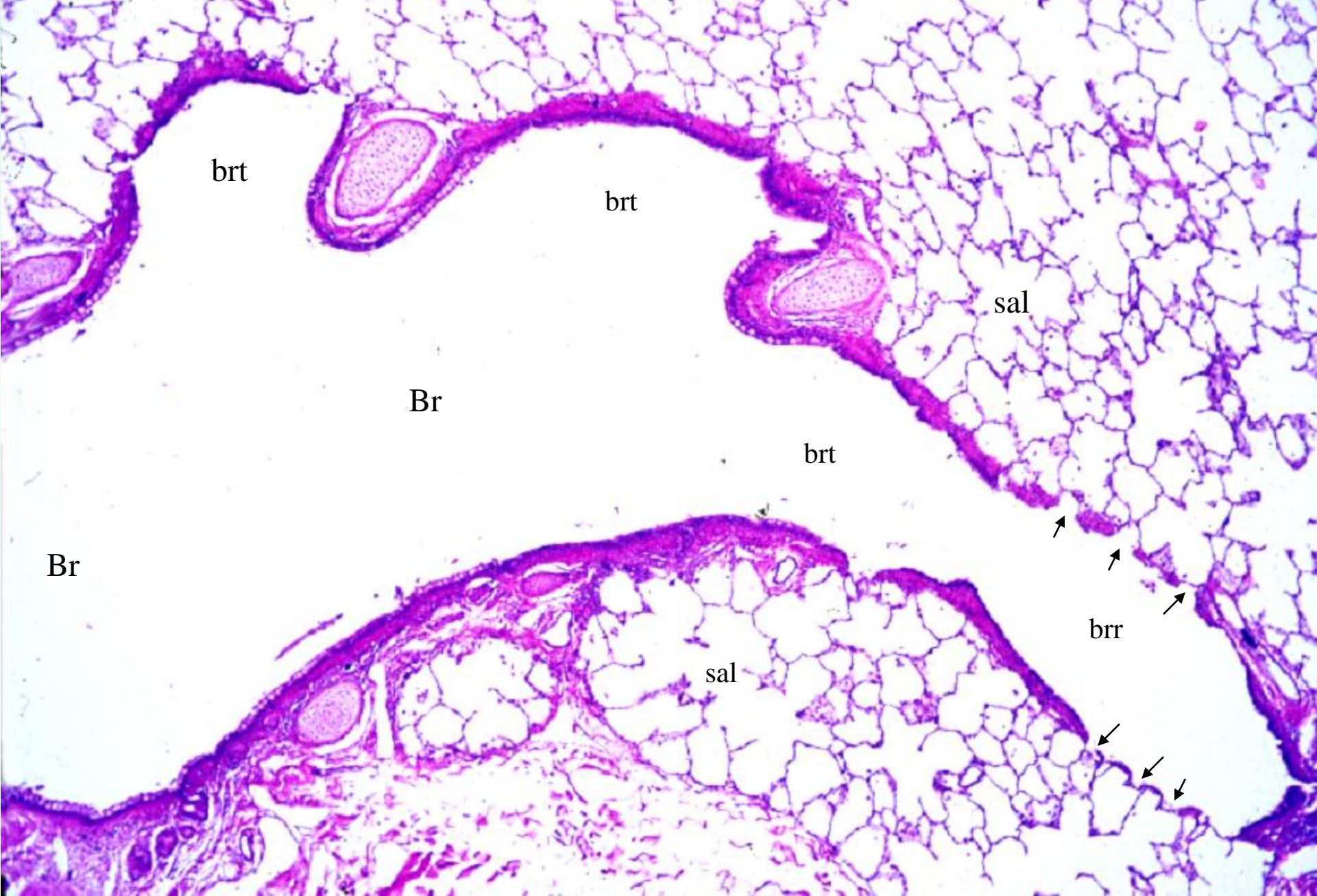
14-20 Lung, 1. General view. Monkey, H-E stain, x 4.0.



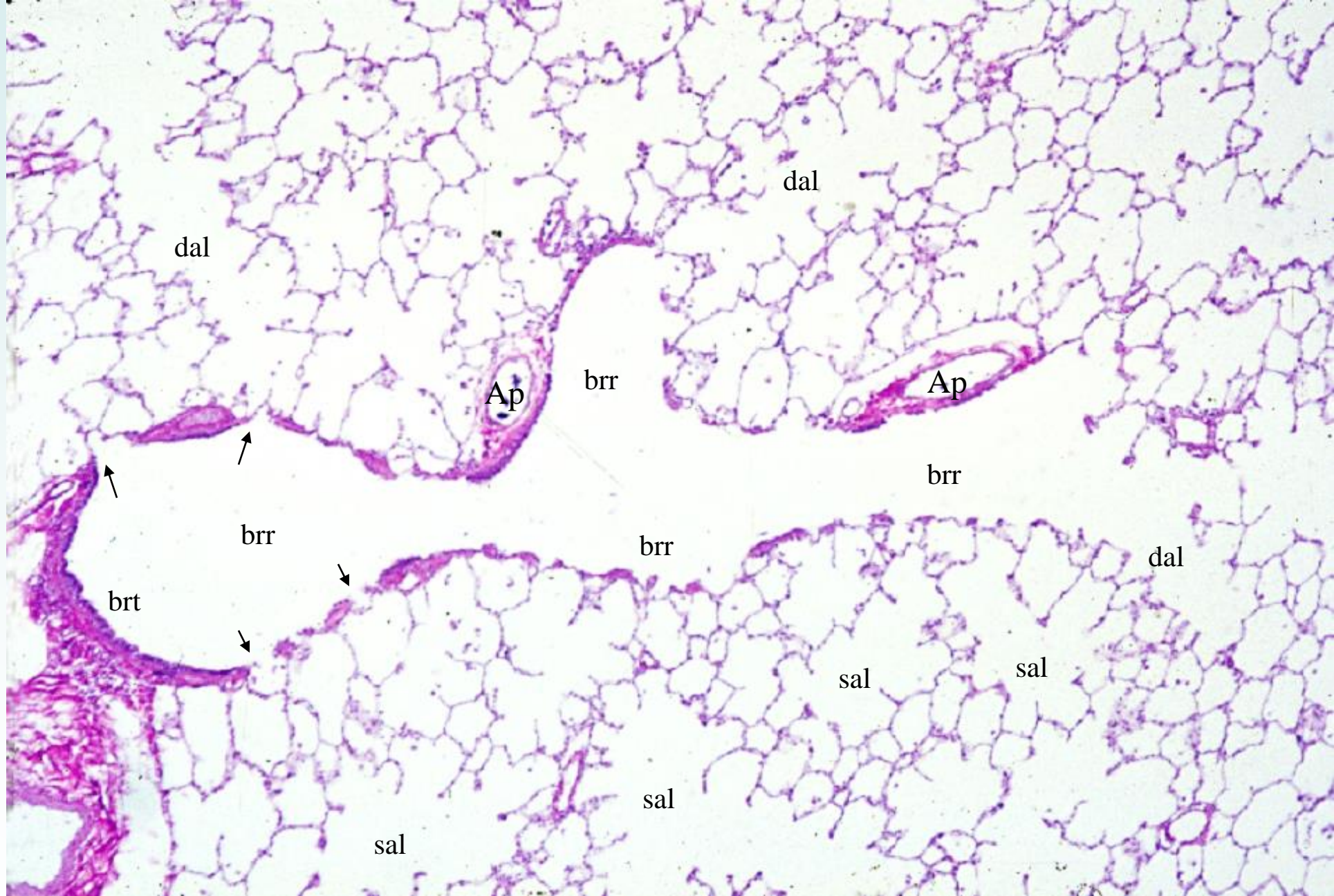
Br

Br

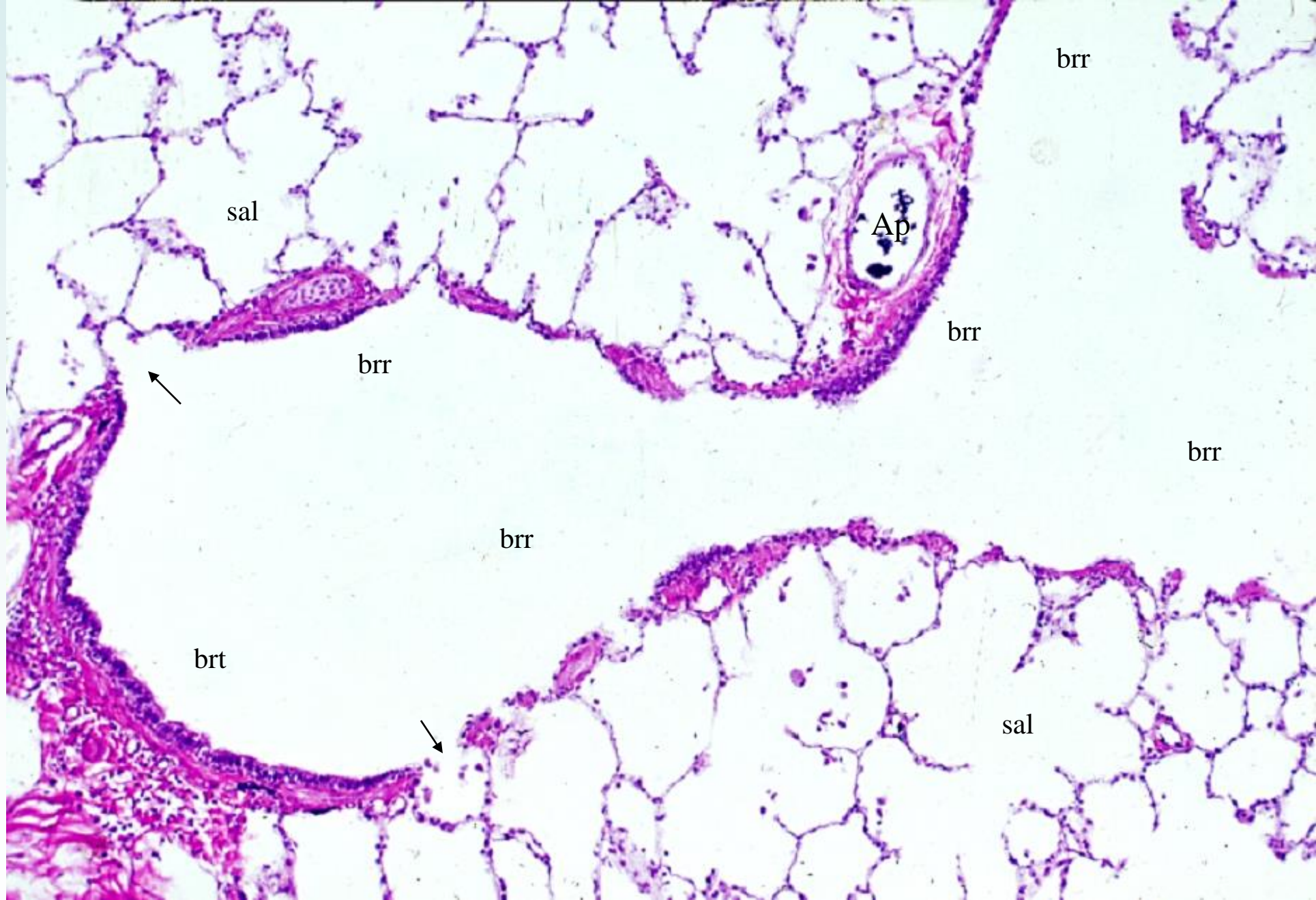
14-21 Lung, 2. Intrapulmonary bronchus. Monkey, H-E stain, x 10.



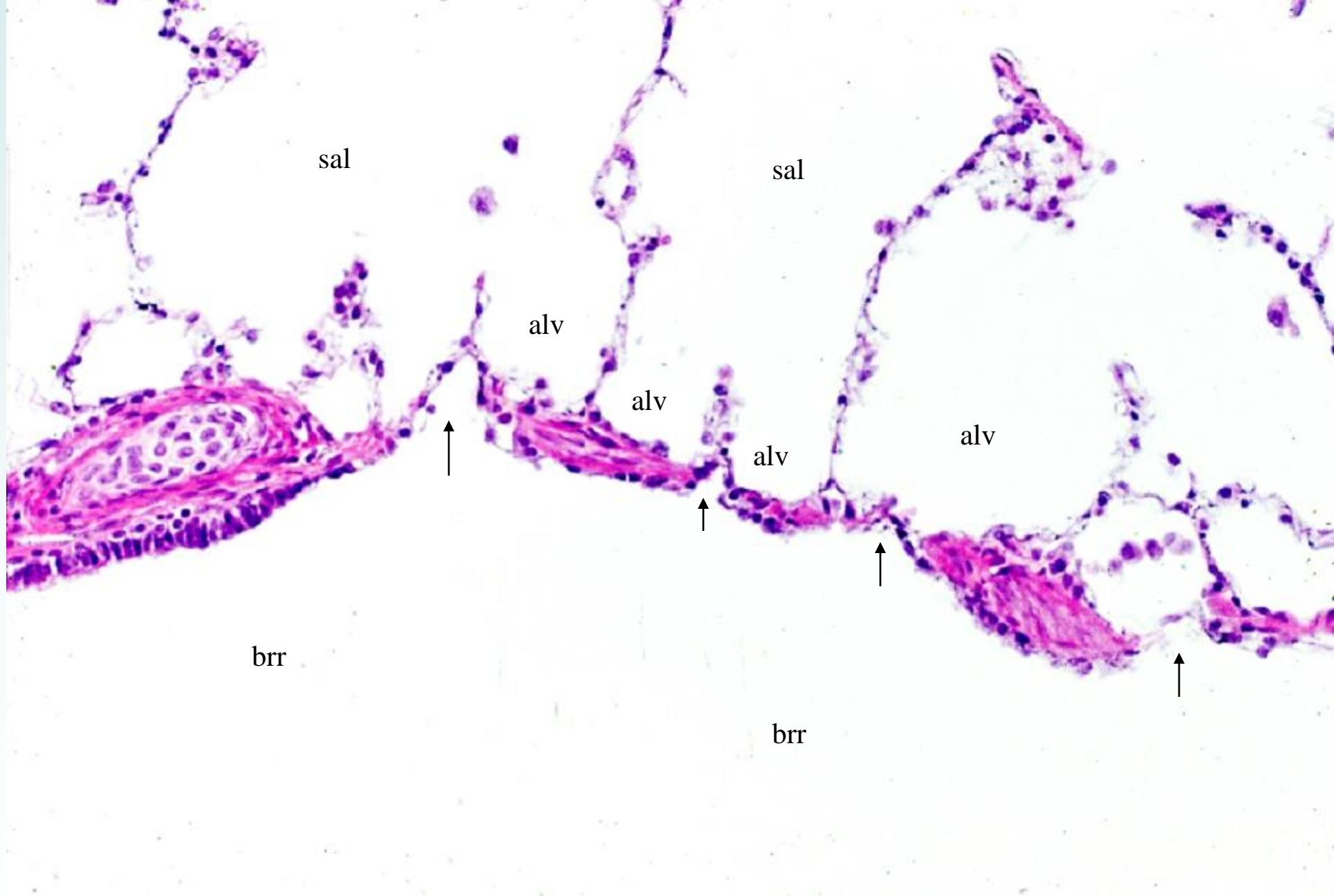
14-22 Lung, 3. Terminal bronchiole. Monkey, H-E stain, x 10.



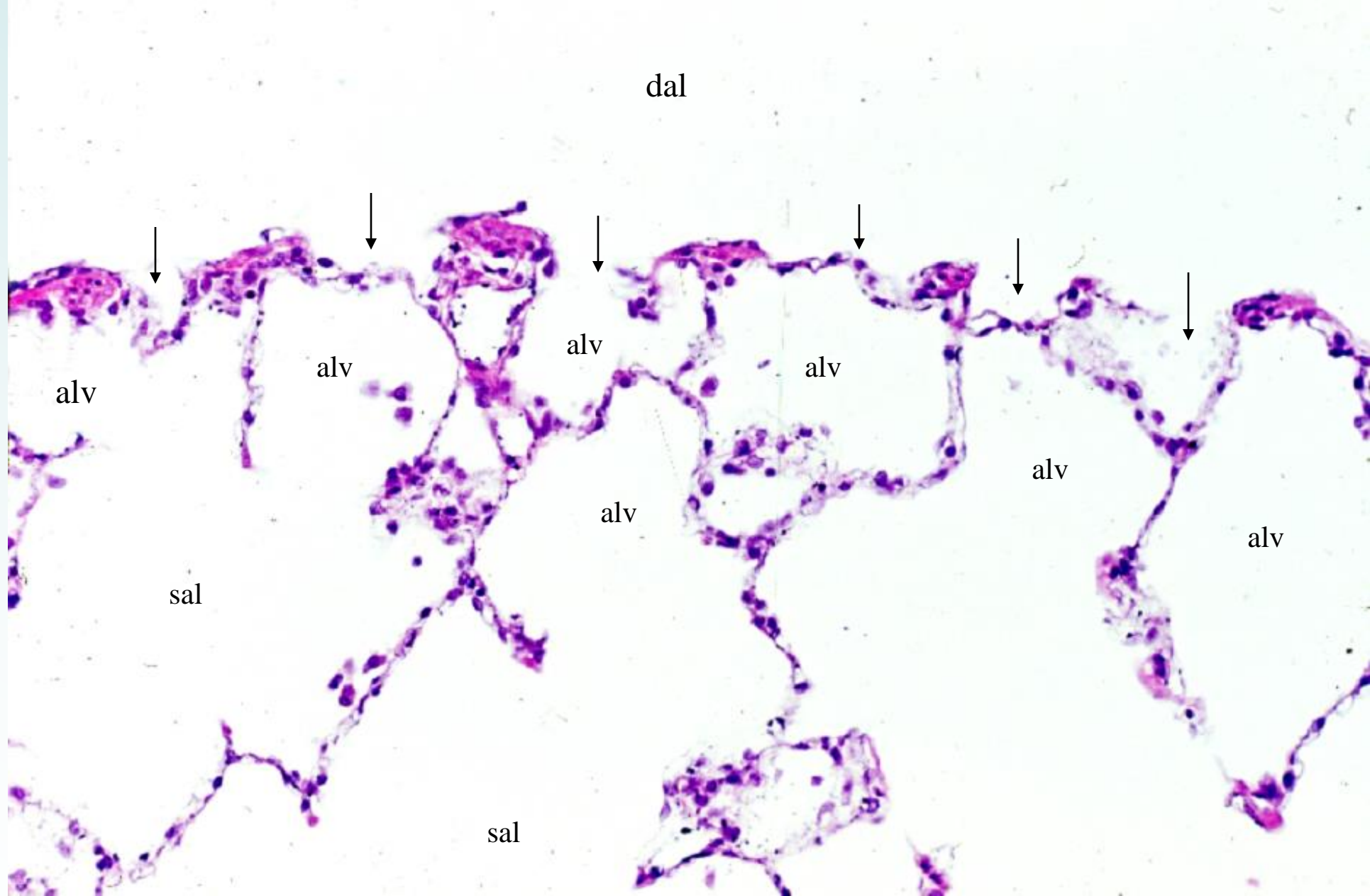
14-23 Lung, 4. Respiratory bronchiole and alveoli, 1. Monkey, H-E stain, x 12.5.



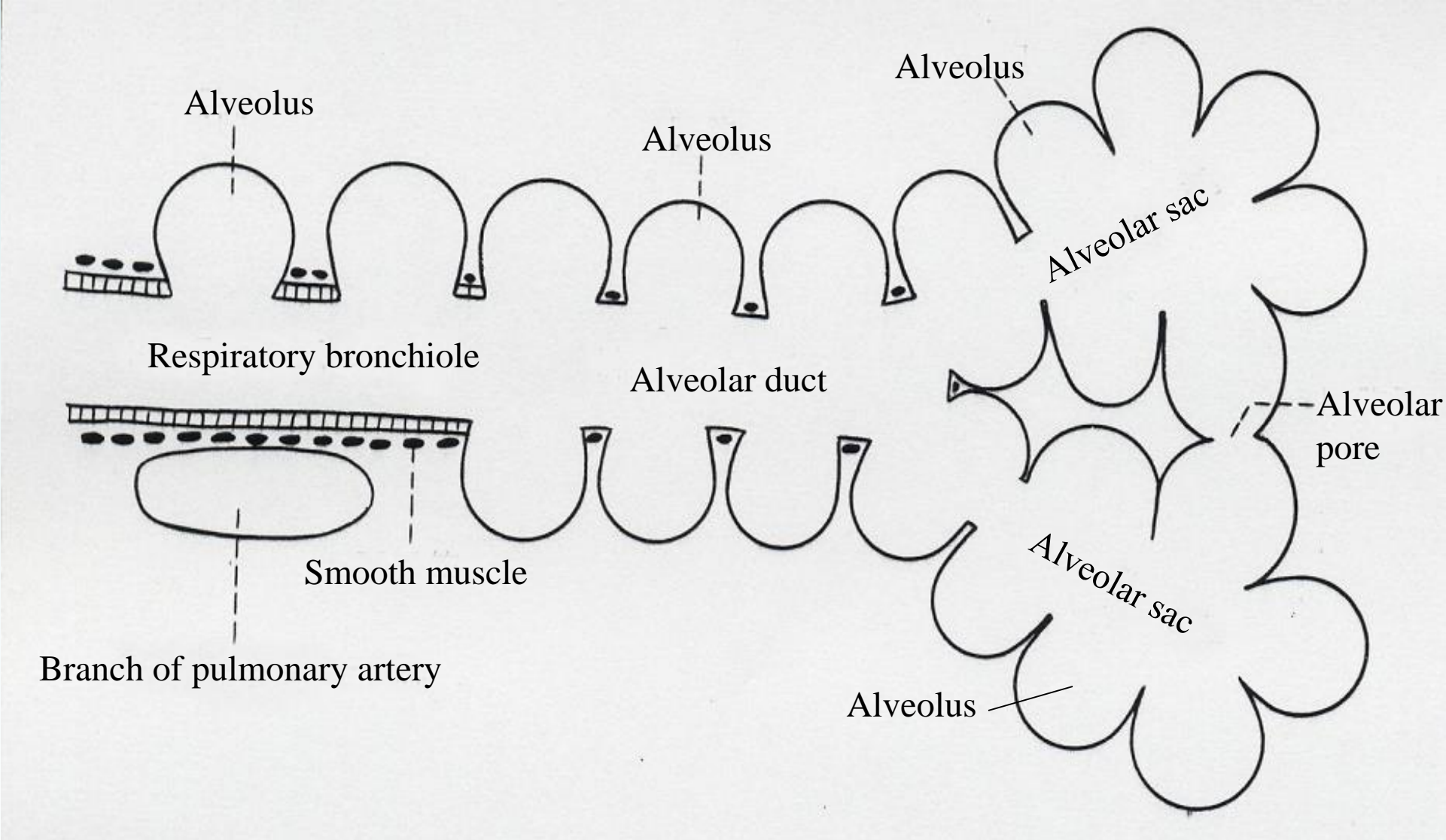
14-24 Lung, 5. Respiratory bronchiole and alveoli, 2. Monkey, H-E stain, x 25.



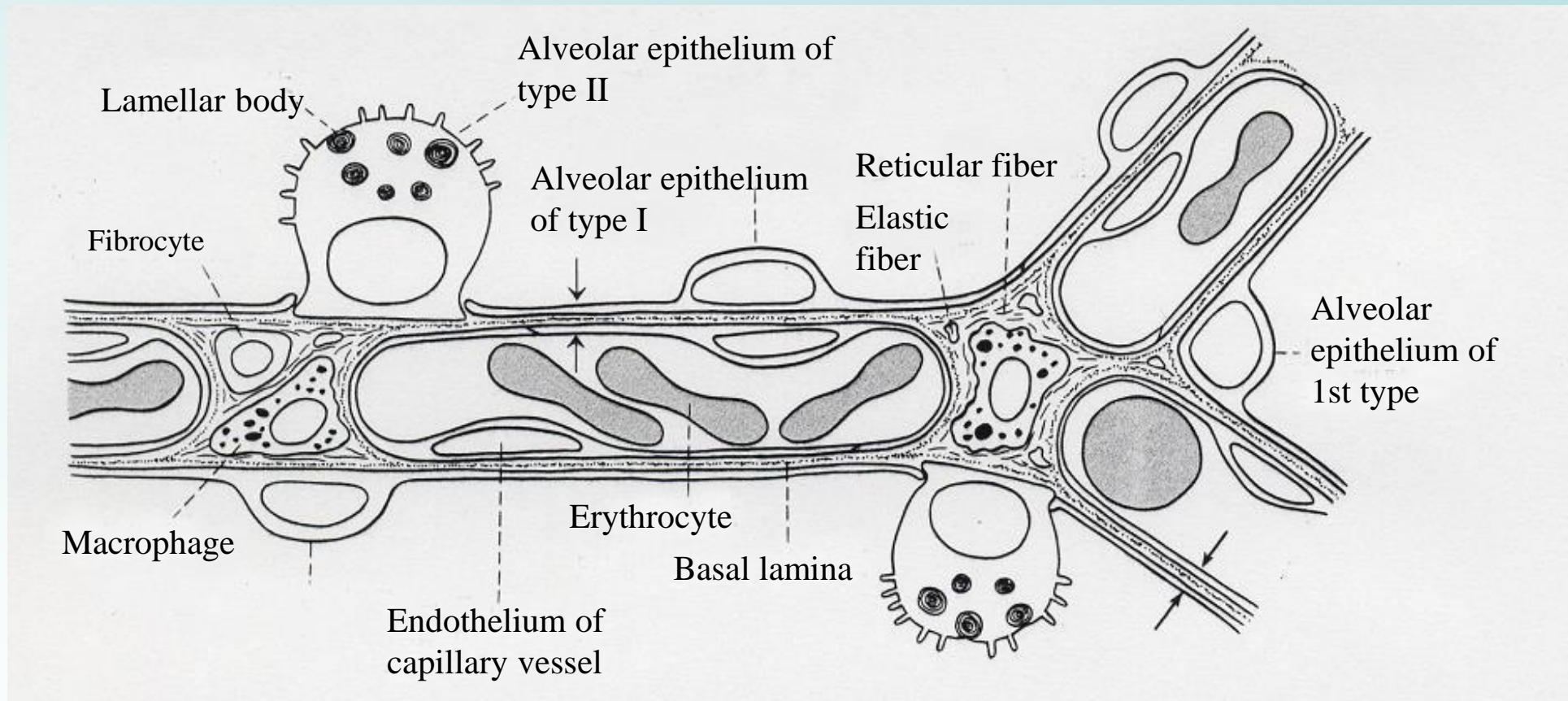
14-25 Lung, 6. Respiratory bronchiole and alveoli, 3. Monkey, H-E stain, x 64.



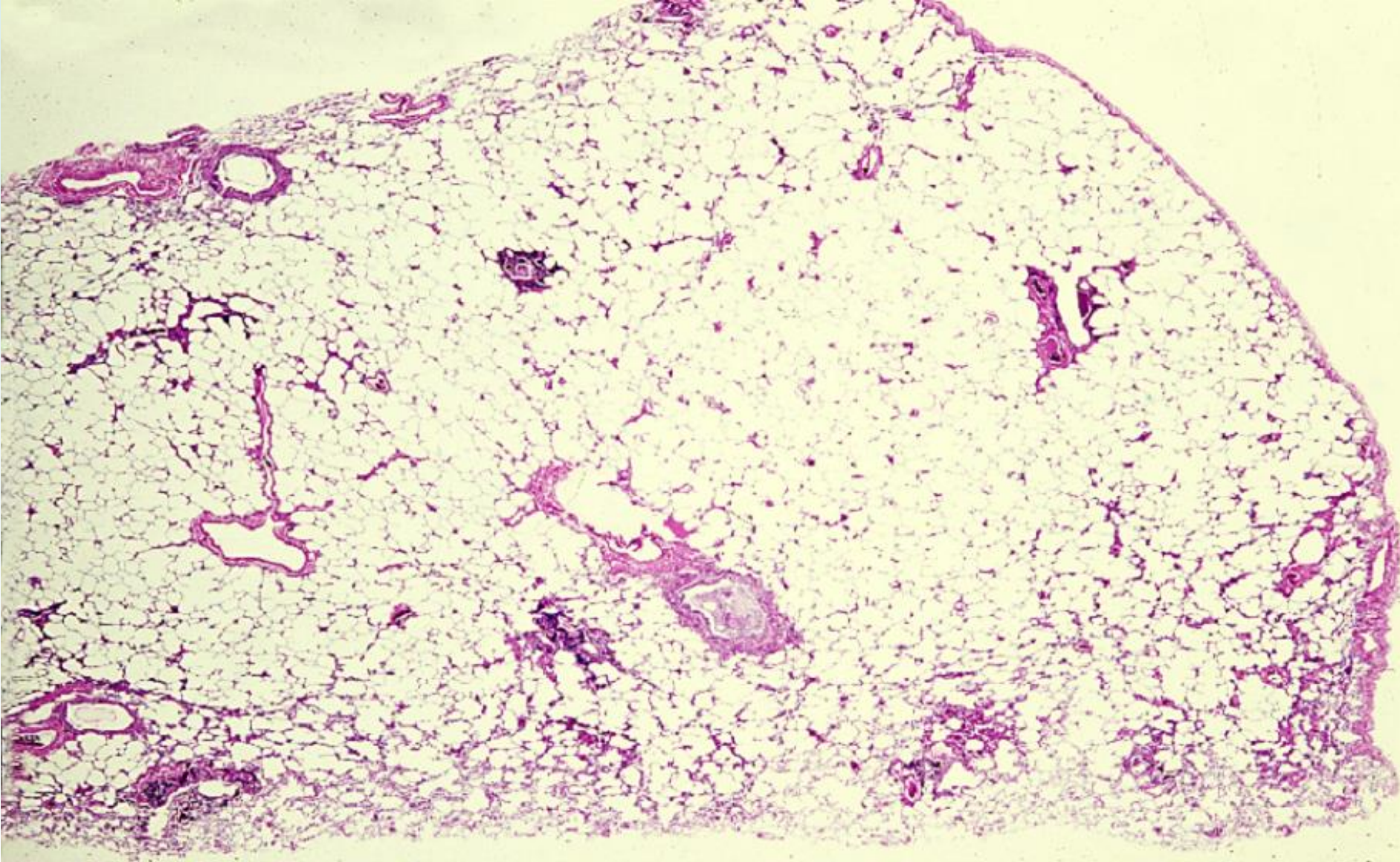
14-26 Lung, 7. Alveolar duct and alveoli, 1. Monkey, H-E stain, x 64.



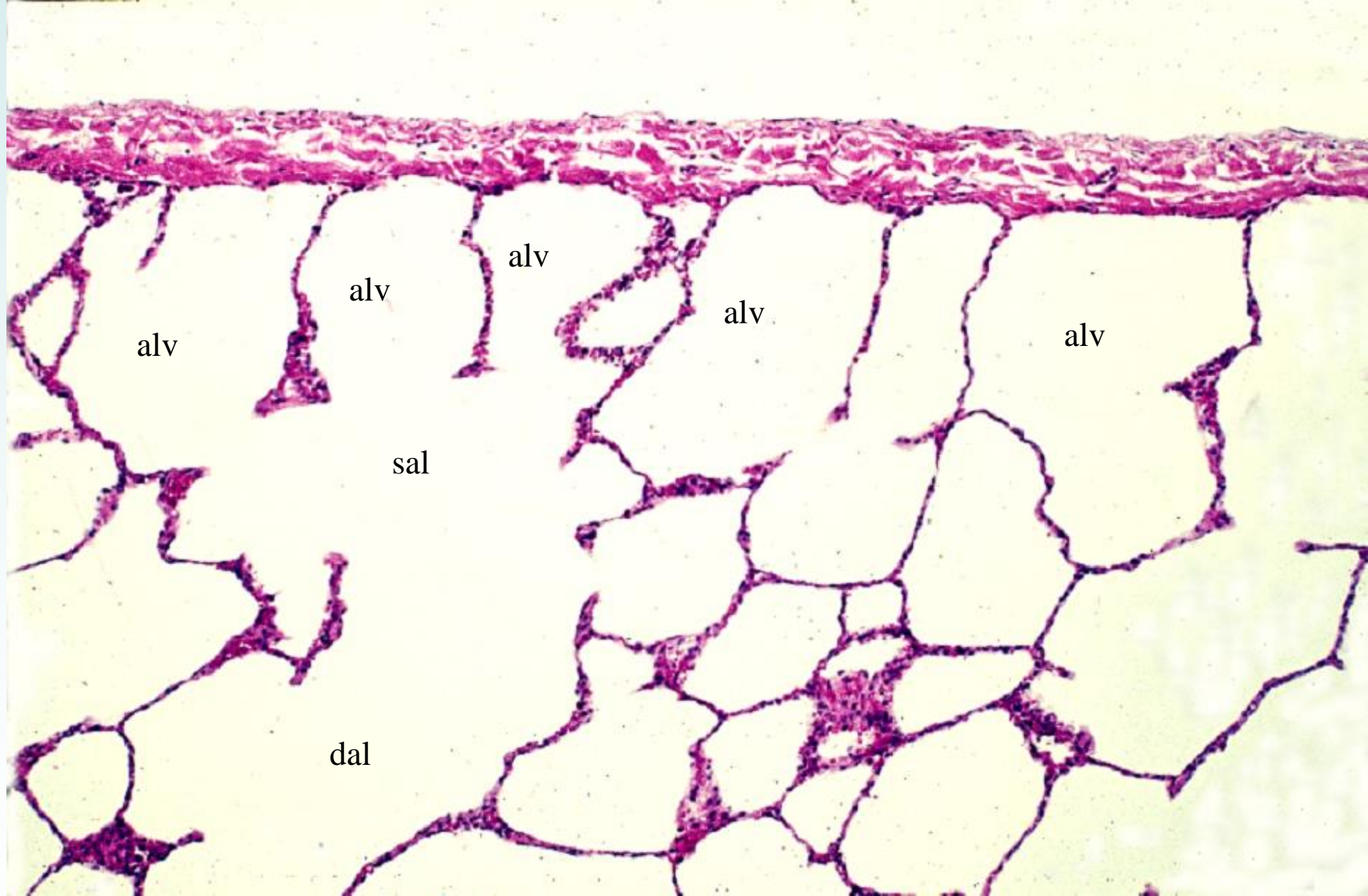
14-27 Scheme showing the branching of the respiratory tree.



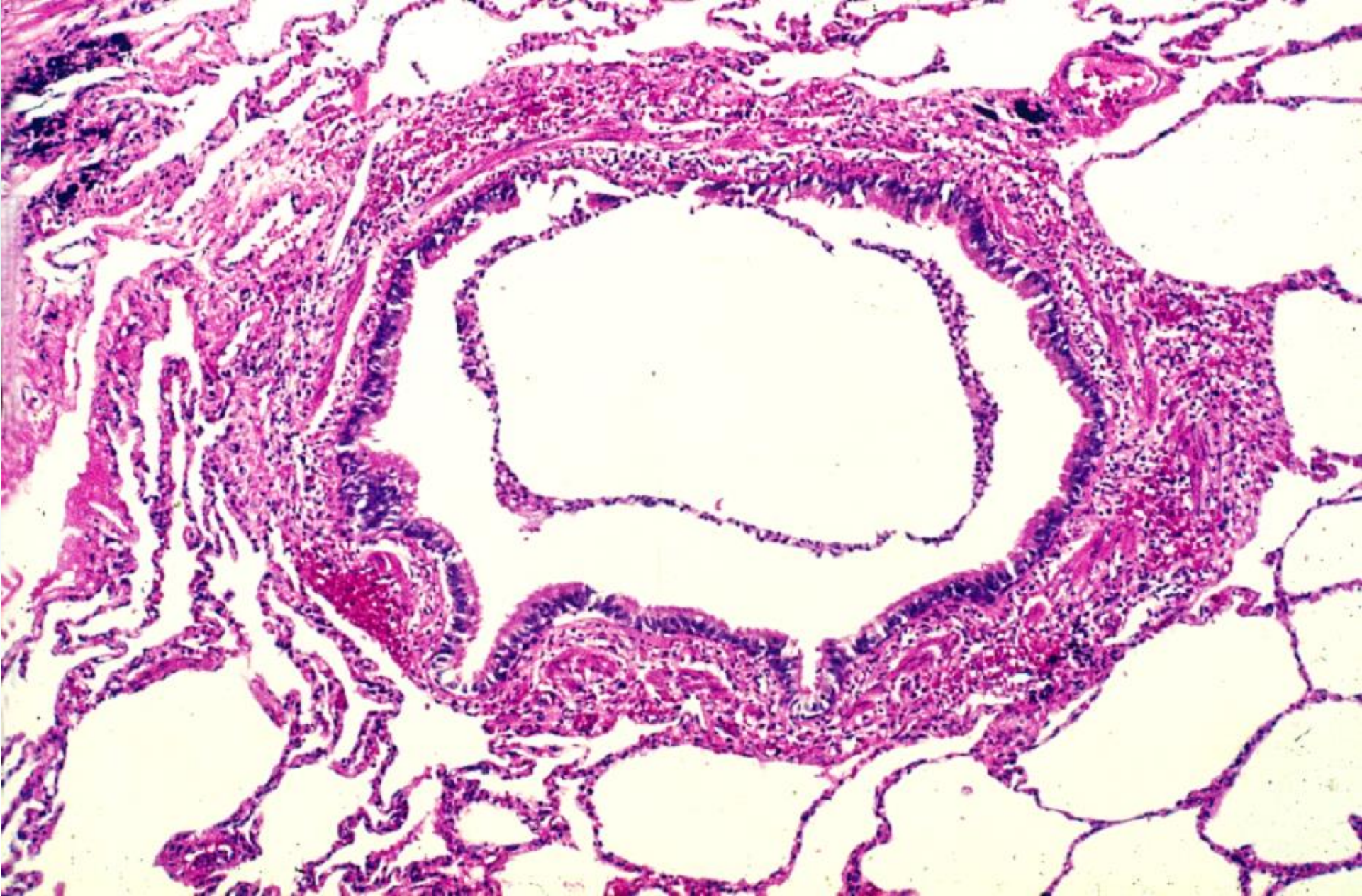
14-28 Scheme showing the ultra fine structure of the alveolar epithelium.



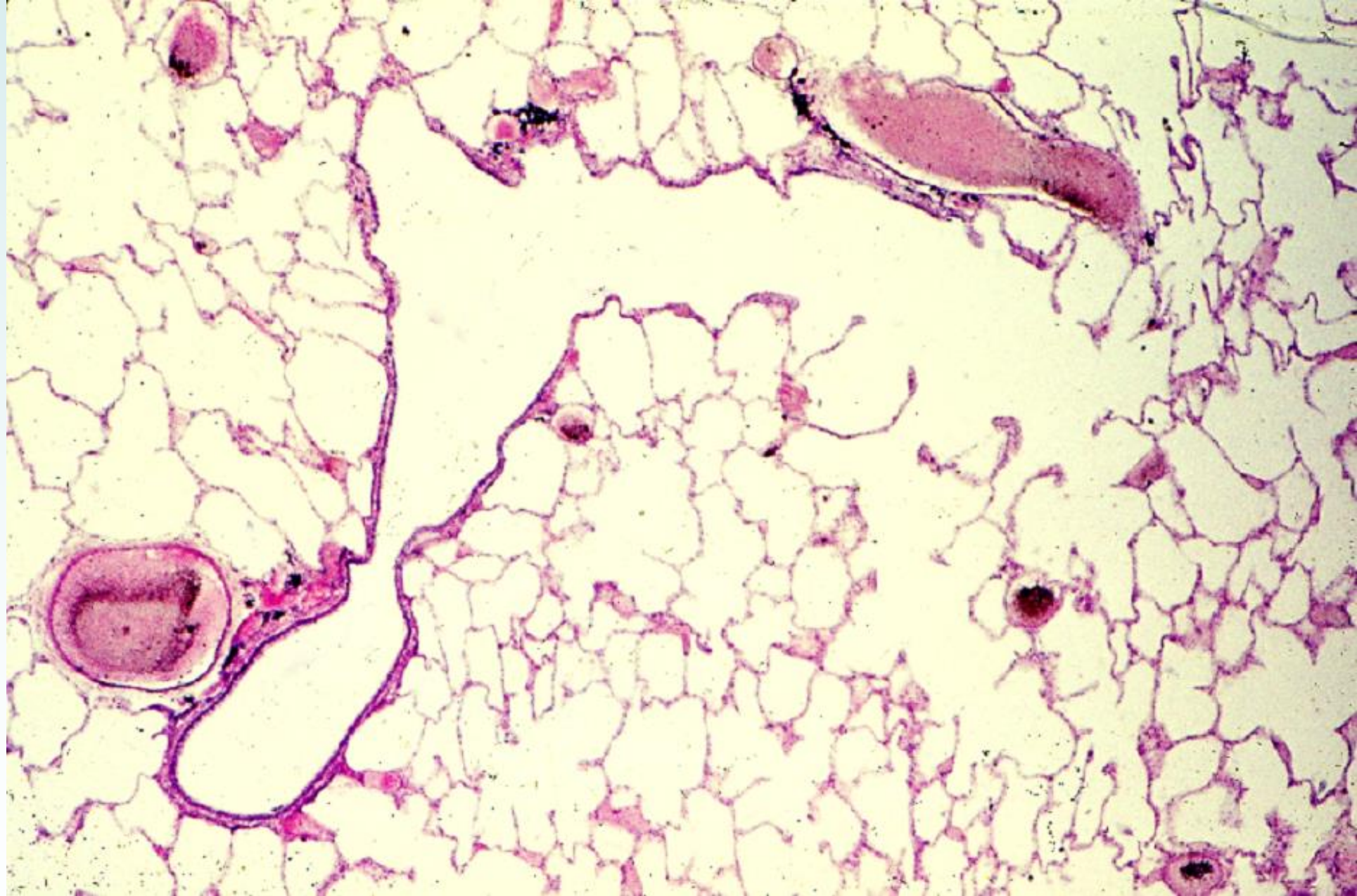
14-29 Human lung, 1. General view. H-E stain, x 1.3.



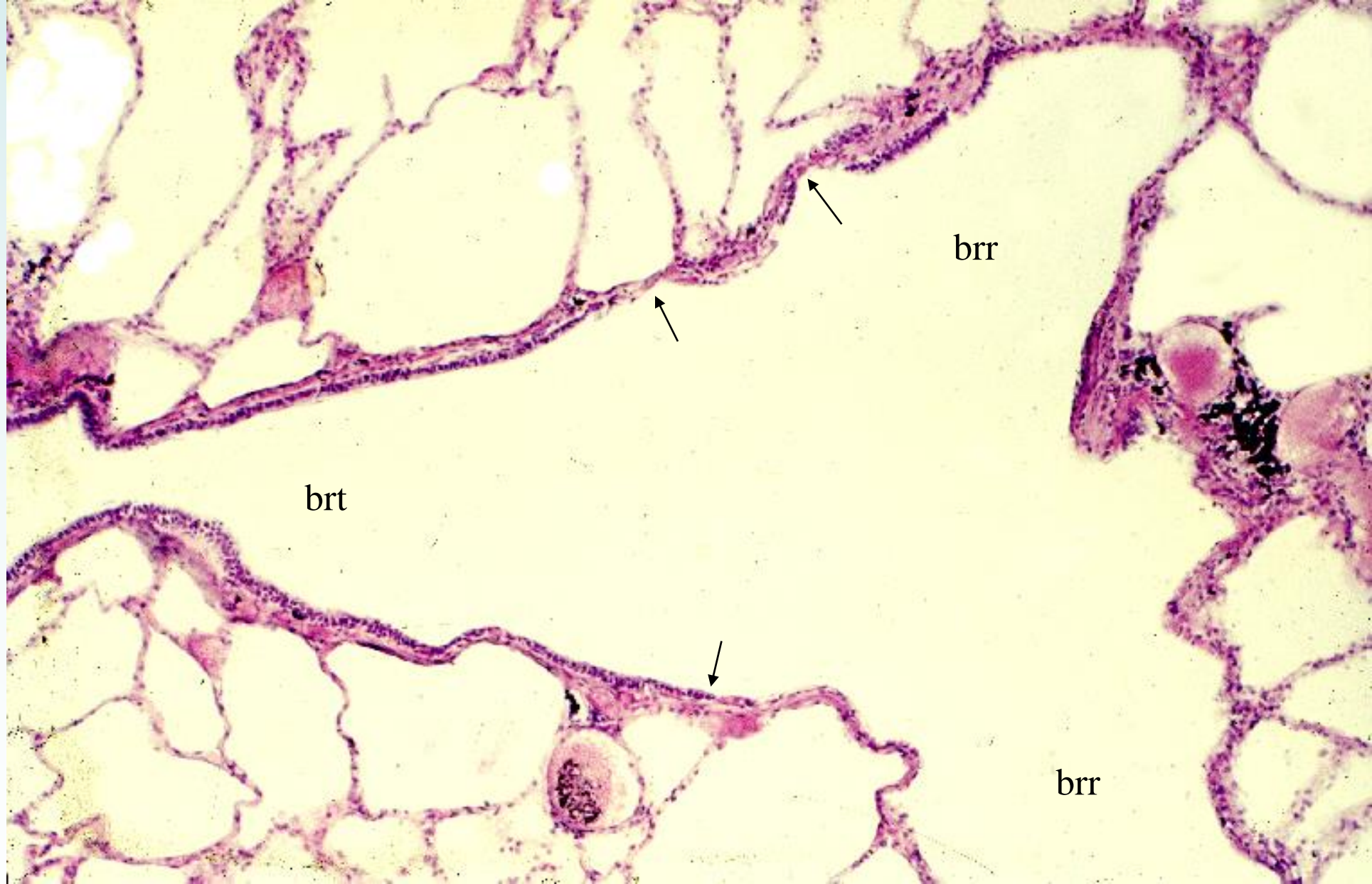
14-30 Human lung, 2. Pleura and alveoli. H-E stain, x 25.



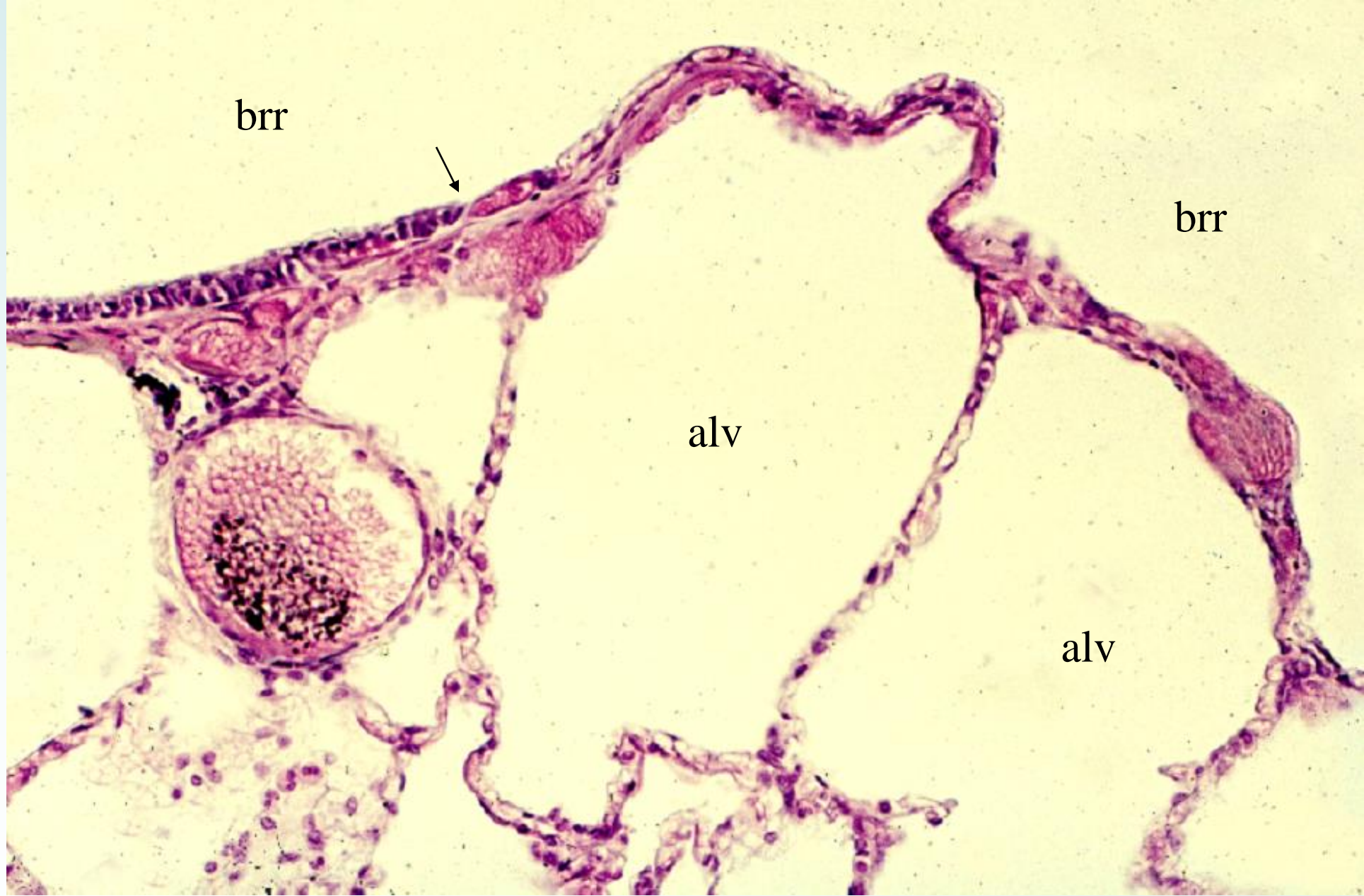14-31 Human lung, 3. Terminal bronchulus and alveoli. H-E stain, x 25.



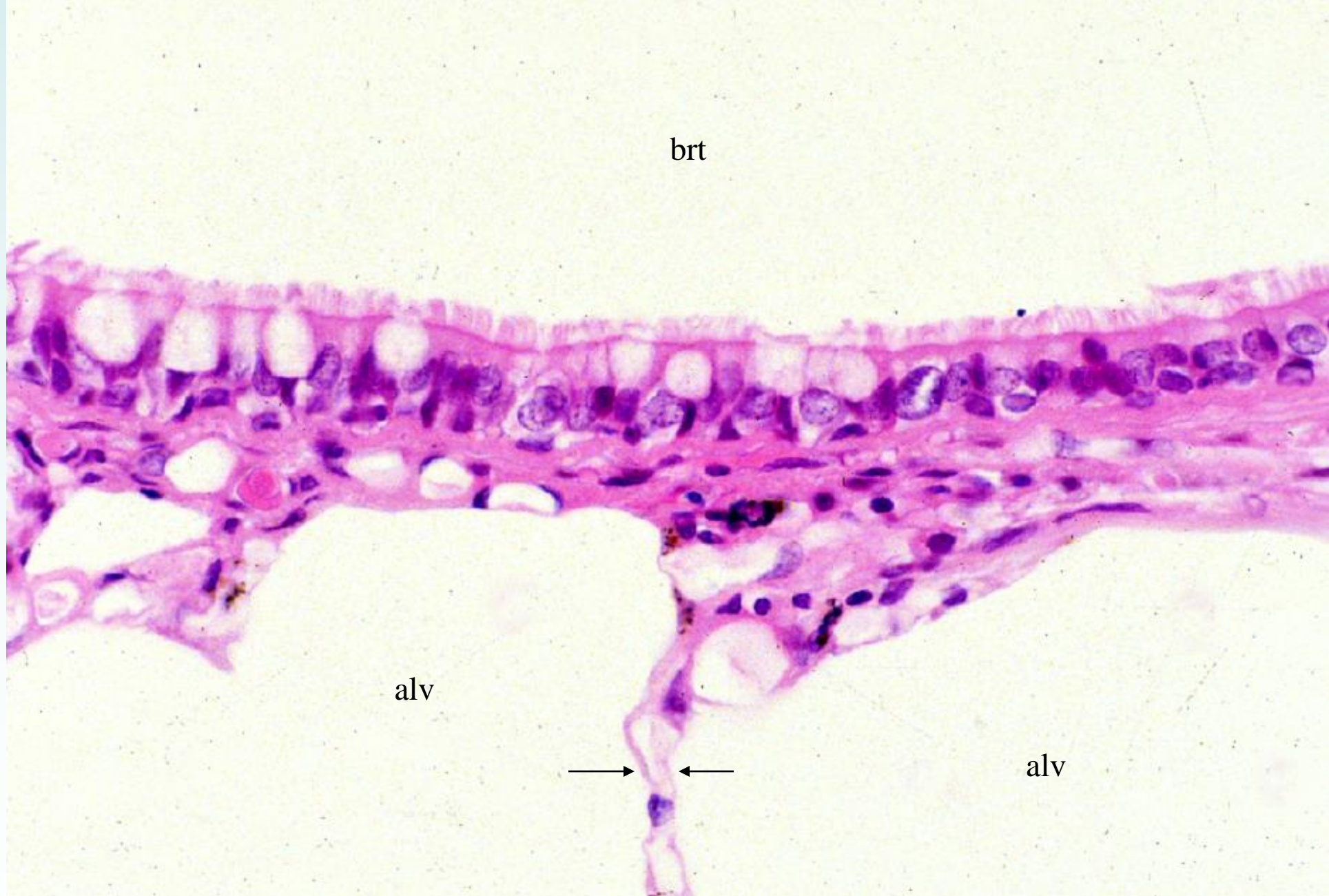
14-32 Human lung, 4. General view. H-E stain, x 10.



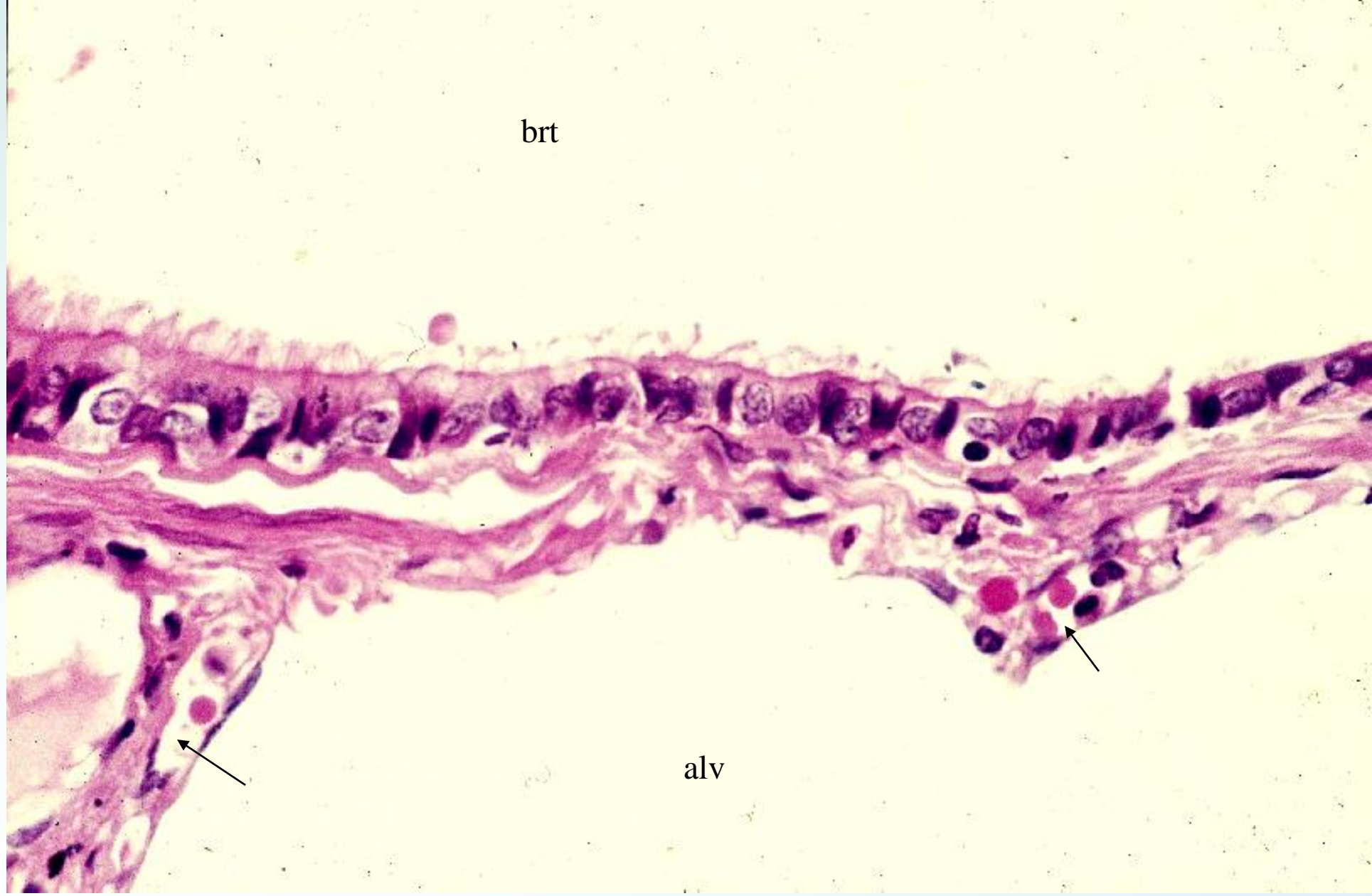14-33 Human lung, 5. Terminal bronchiole and respiratory bronchiole. H-E stain, x 25.



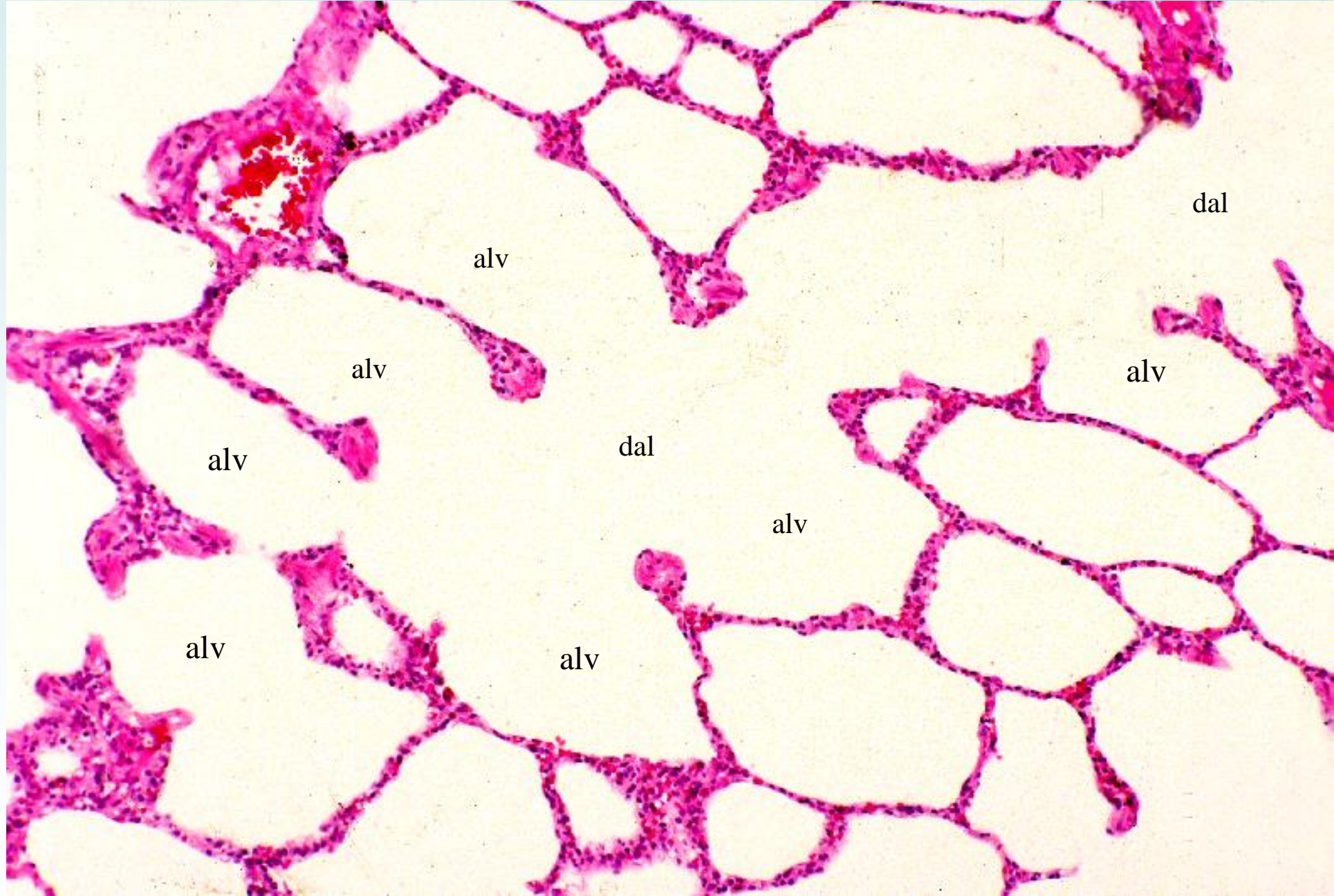
14-34 Human lung, 6. Respiratory bronchiole and alveoli. H-E stain, x64.



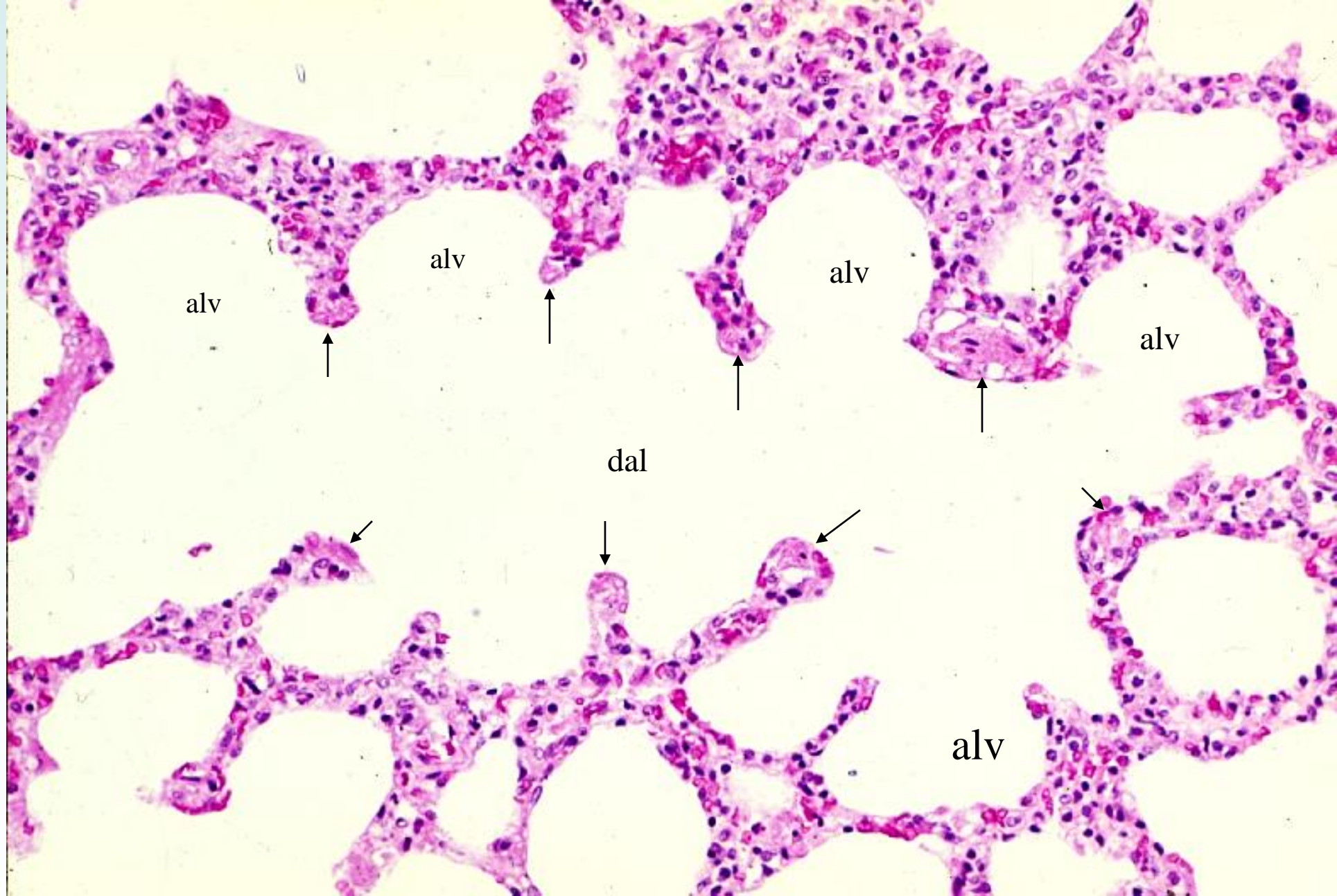
14-35 Human lung, 7. Terminal bronchiole and alveoli, 1. H-E stain, x 160.



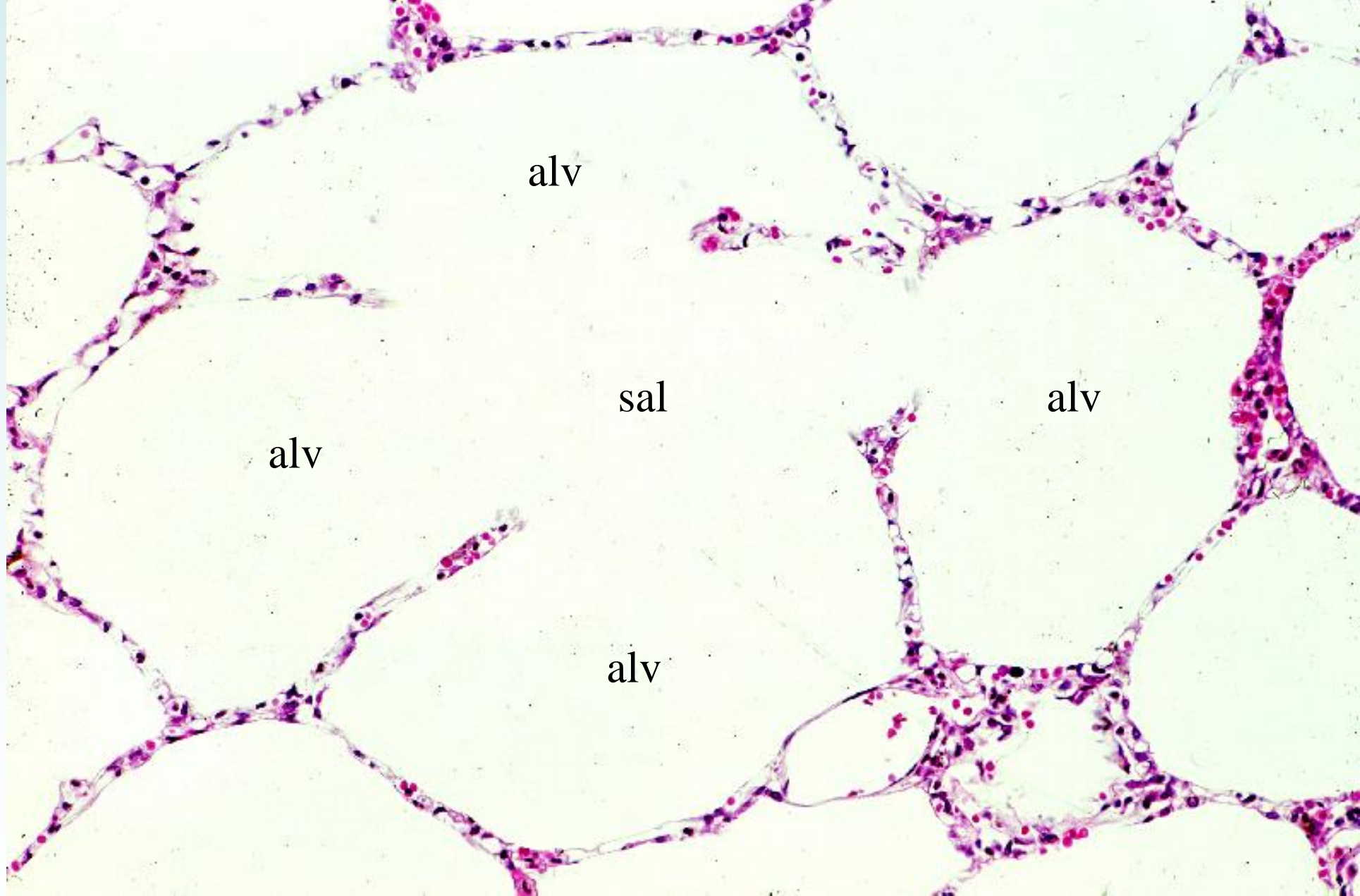
14-36 Human lung, 8. Terminal bronchiole and alveoli, 2. H-E stain, x 160.



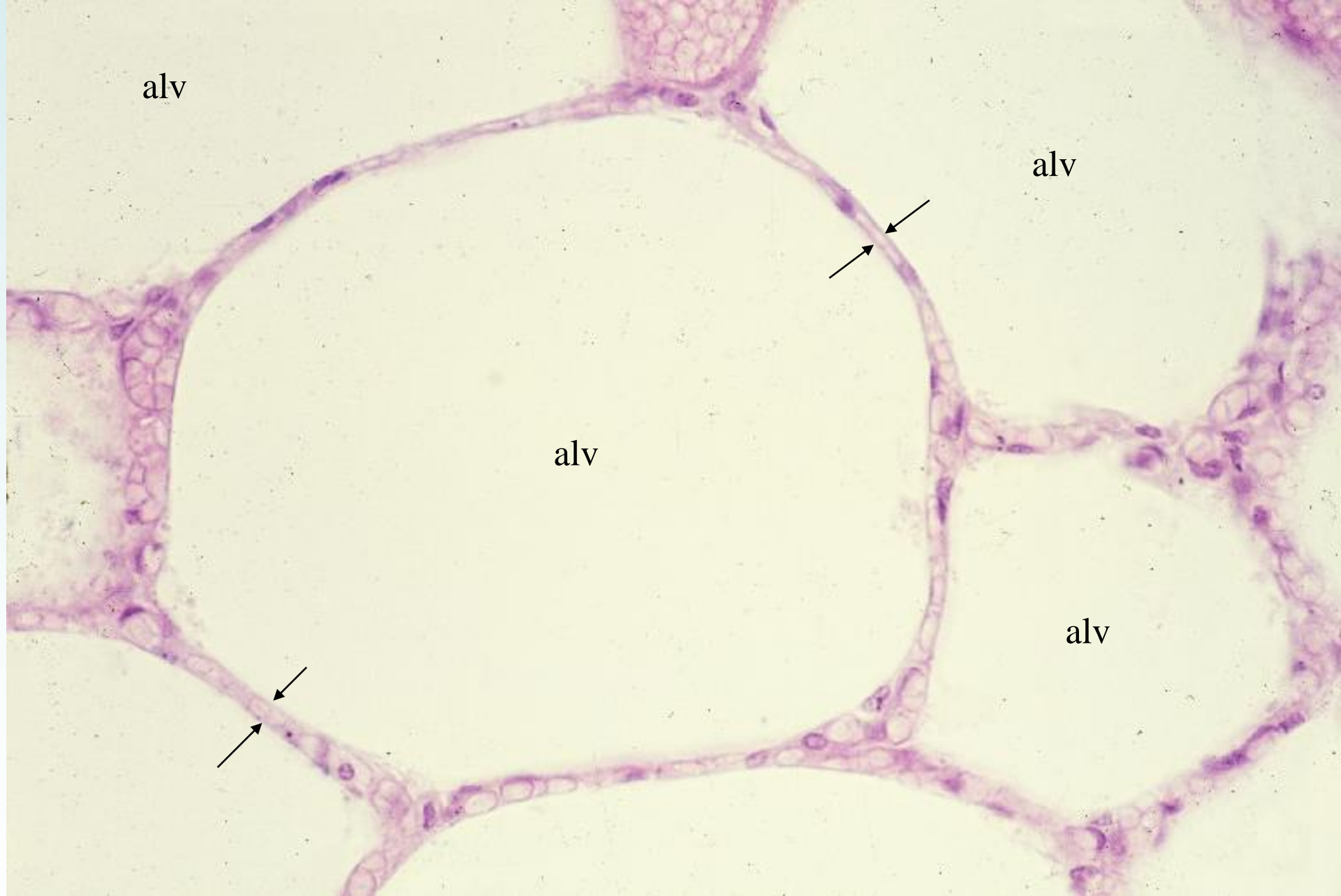
14-37 Human lung, 9. Alveolar duct and alveoli, 1. H-E stain, x 33.



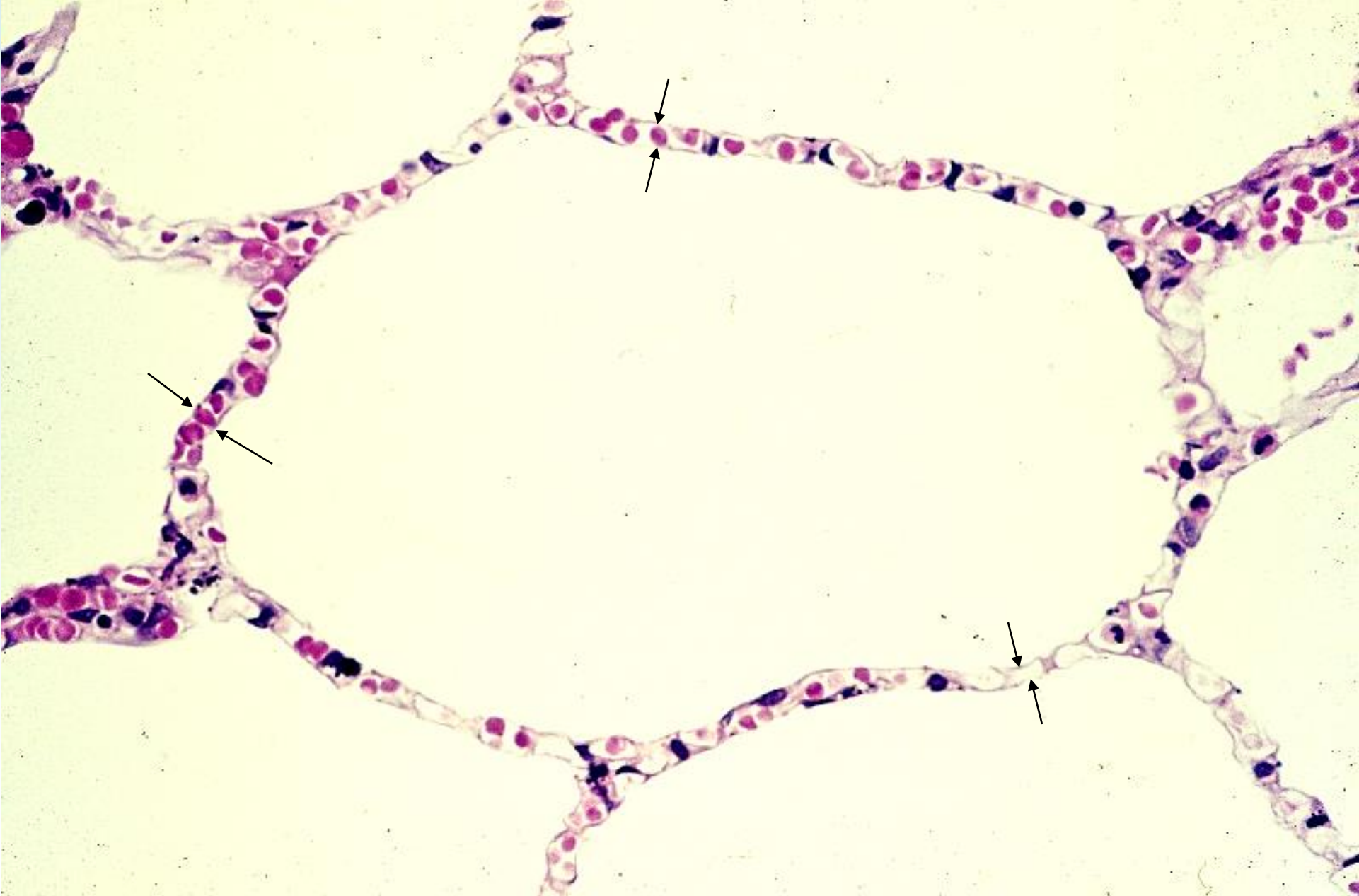
14-38 Human lung, 10. Alveolar duct and alveoli, 2. H-E stain, x 64.



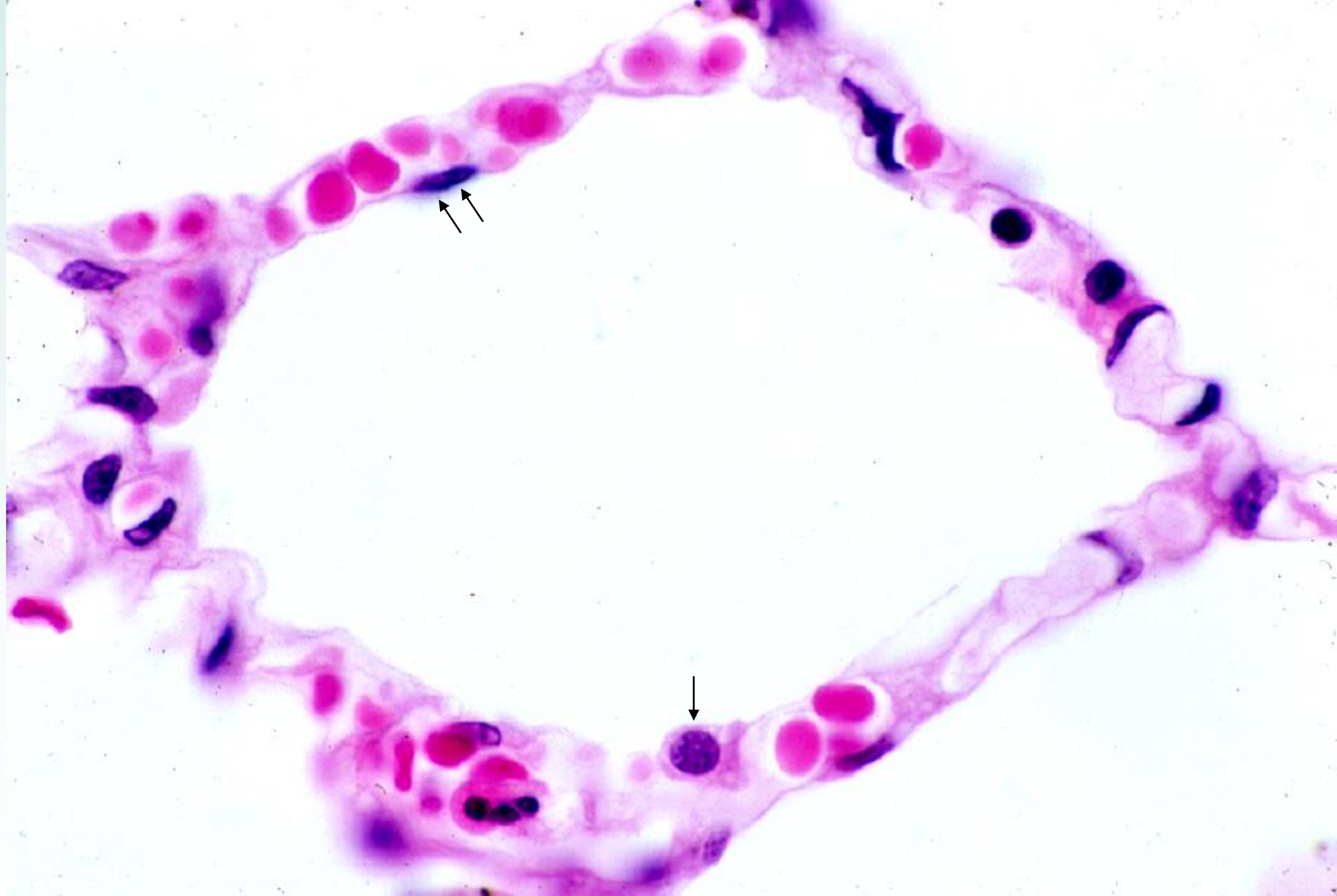
14-39 Human lung, 11. Alveolar sac and alveoli. H-E stain, x 25.



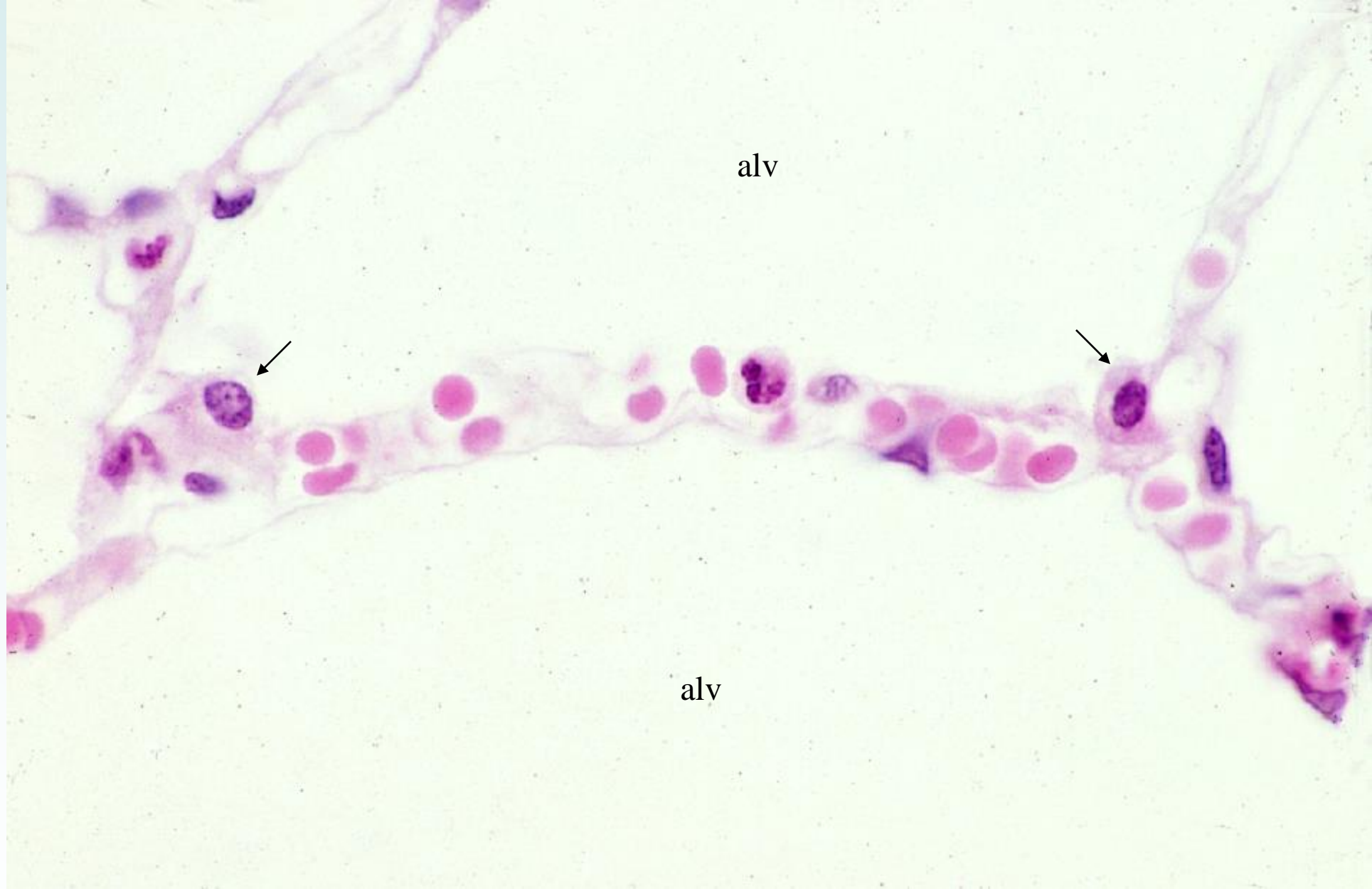14-40 Alveoli, 1. Human, H-E stain, x 100.



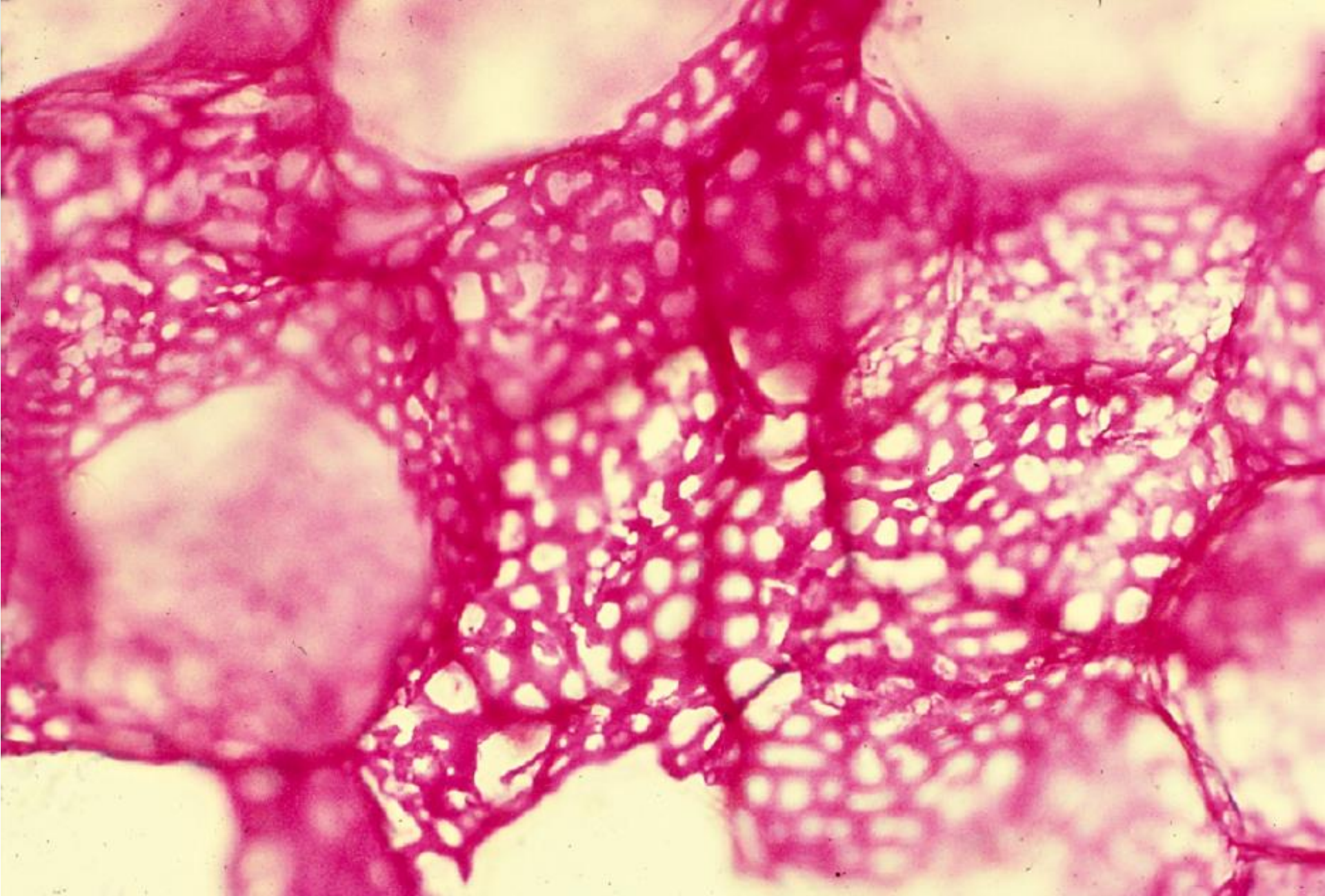
14-41 Alveoli, 2. Human, H-E stain, x 100.



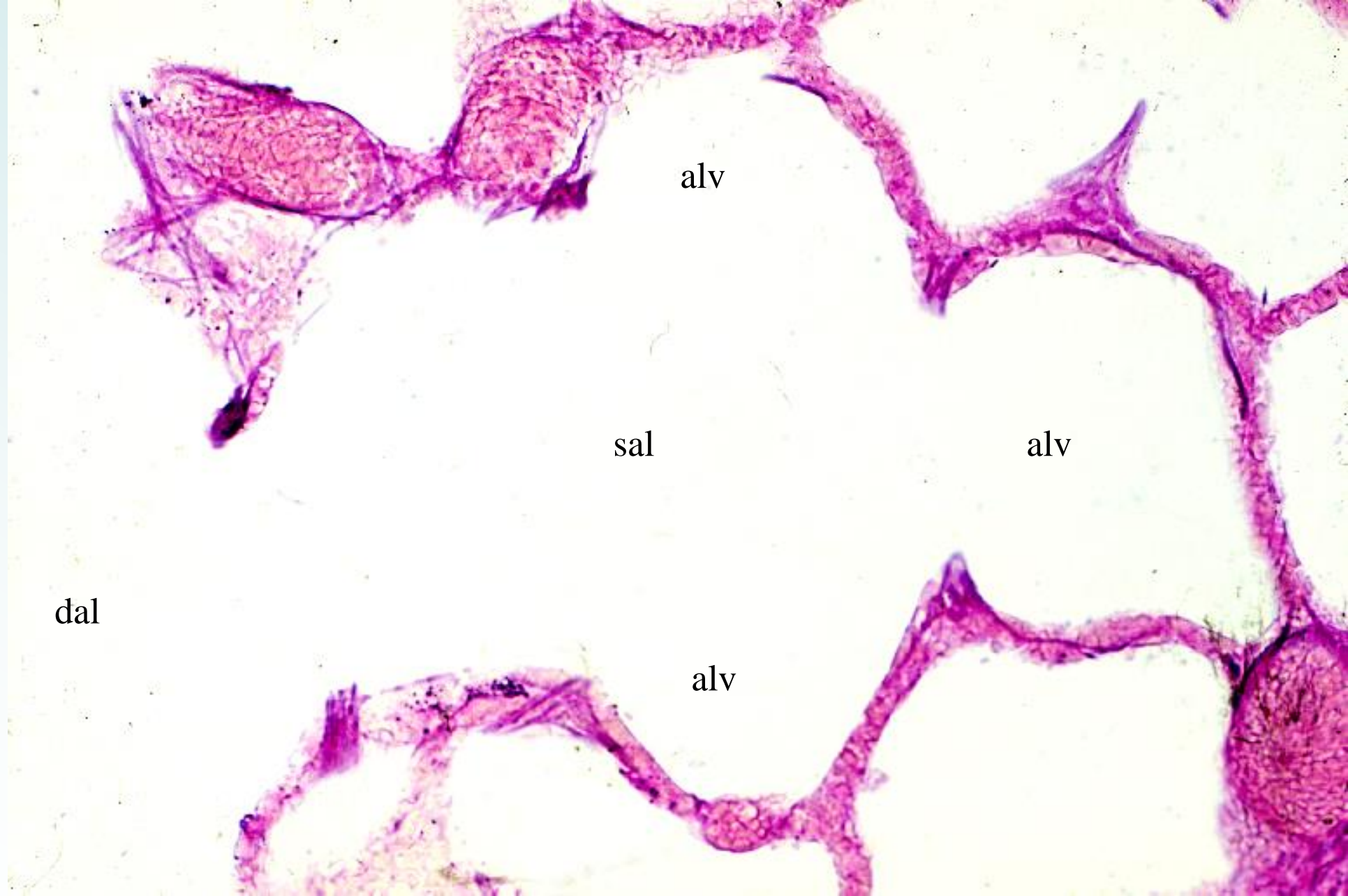
14-42 Alveoli, 3. Human, H-E stain, x 250.



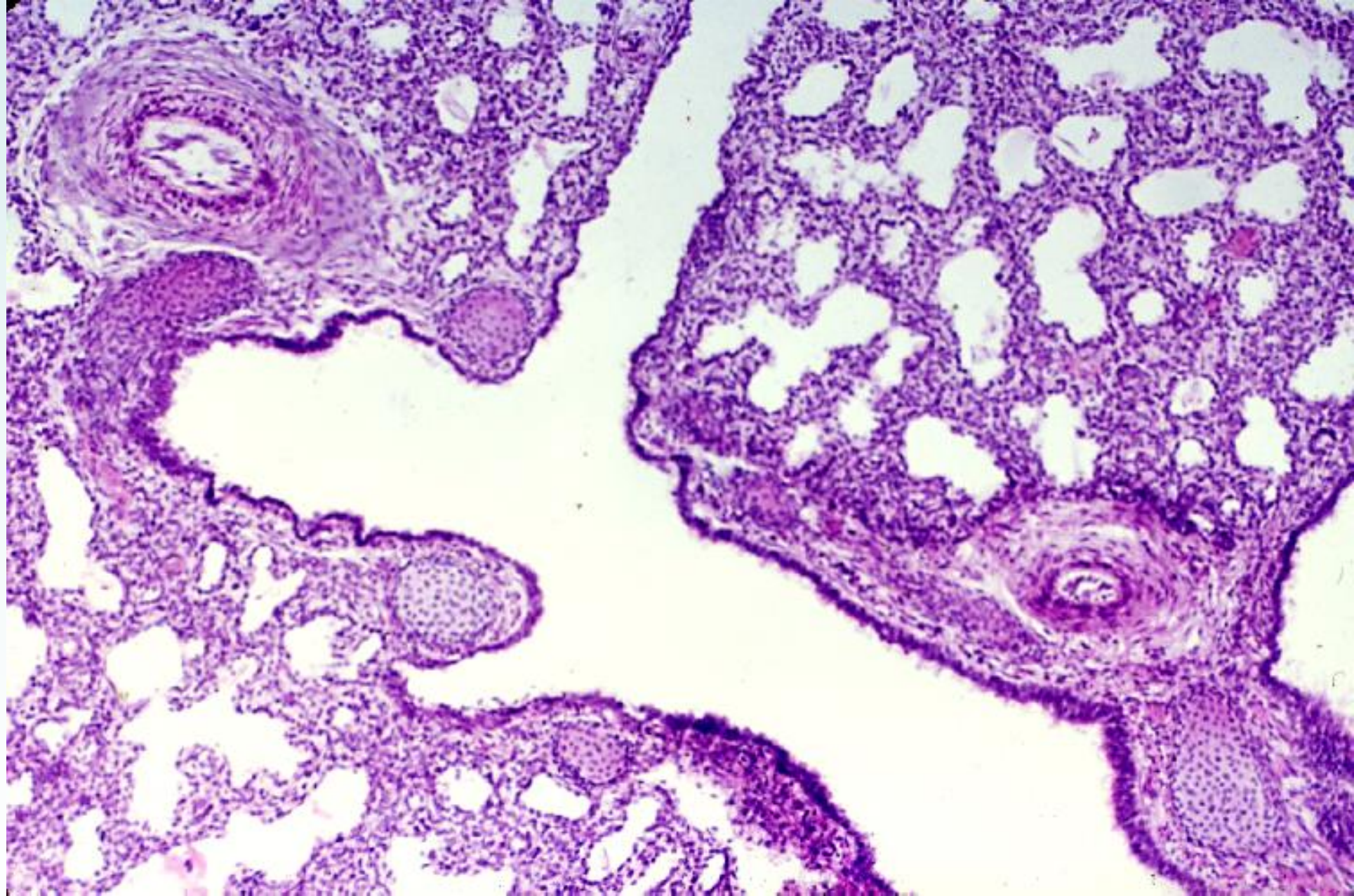
14-43 Alveoli, 4. Human, H-E stain, x 250.



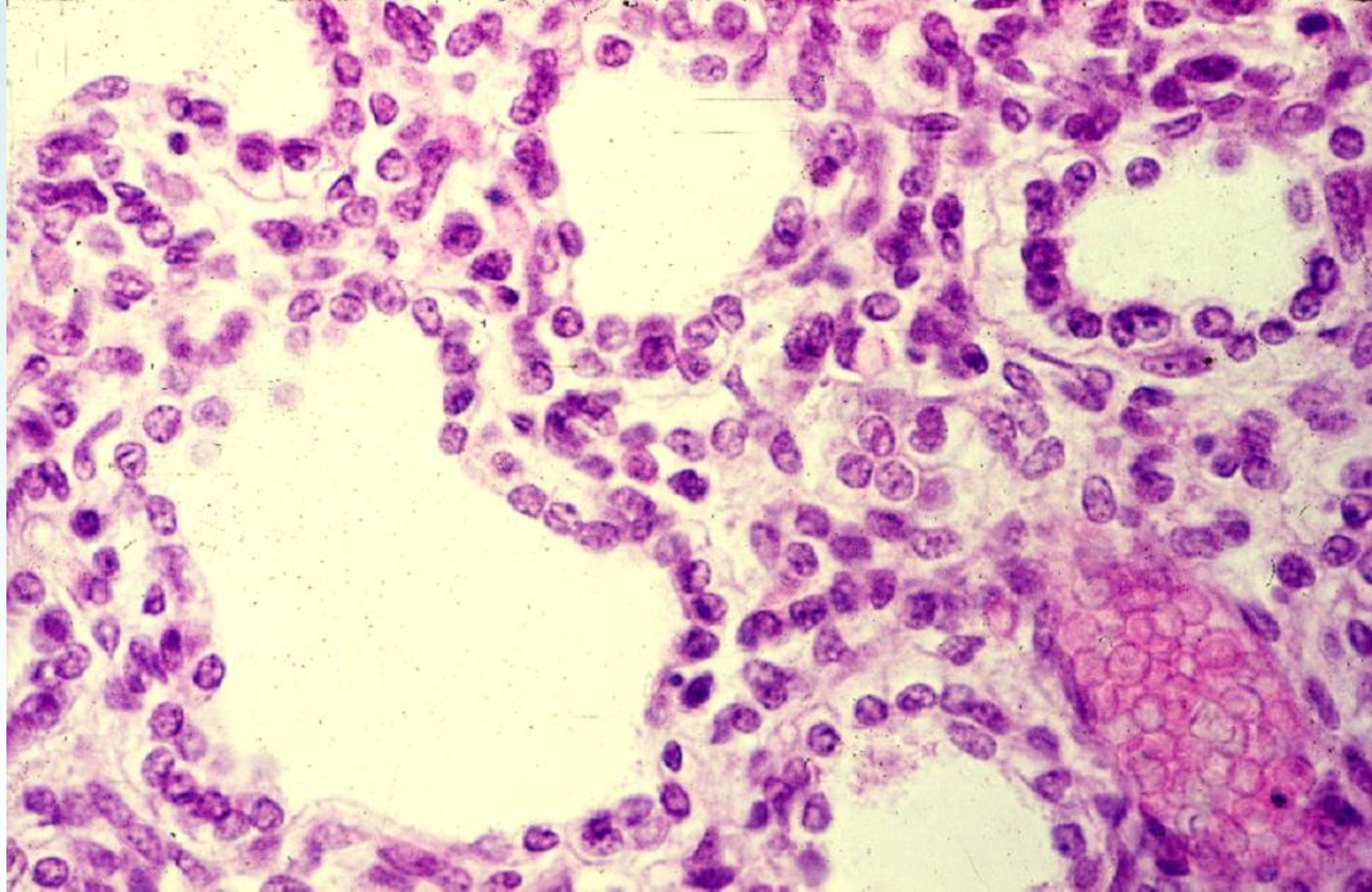
14-44 Capillary network in the alveolar wall. Human, infusion with cinnabar. x 64.



14-45 Elastic fibers in the alveolar wall. Human, resorcin-fuchsin stain, x 64.



14-46 Lung of embryo, 1. Monkey, H-E stain, x 25.



14-47 Lung of embryo, 2. Monkey, H-E stain, x 160.

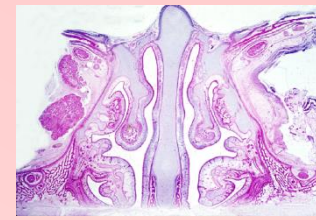14-00 Respiratory System

- The respiratory system consists of the air conducting ducts and respiratory portion. The former comprises the air conducting tubes that connect the exterior of the body with that portion of the lungs where the exchange of gases between blood and the air takes place.

14-001 Nasal Cavity

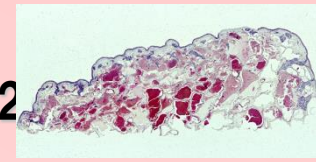
- The nasal cavity is divided into right and left nasal cavities by a median nasal septum. The nasal cavities open anteriorly at the nares and posteriorly into the pharynx. Their surface area is increased by three thin plow-like projections from the lateral walls, called the superior, middle and inferior conchae. The interior of the nose is lined by four types of epithelium. The stratified squamous epithelium of the skin continues through the nares into the vestibulum, where a few large stiff hairs project into the airway. A few millimeters into the vestibulum, stratified squamous epithelium gives way to a narrow transitional band of nonciliated cuboidal or columnar epithelium. This is continuous with ciliated pseudostratified columnar epithelium that lines the remainder of the nasal cavity, and a small area in the dorsal wall is lined by the sensory olfactory epithelium.

14-01 Nasal cavity, frontal section. Human newborn, H-E stain, x 1.3.



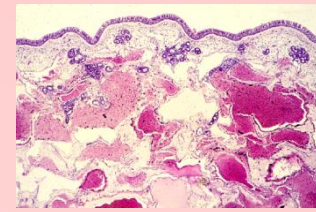
- This is a frontal section of the nasal cavities of human newborn. In the middle stands the nasal septum, dividing the right and left nasal cavities. The upper (A) and the lower (C) nasal conchae are well developed, whereas the middle (B) is not fully developed. The spaces between the nasal septum and the lateral walls are nasal cavities. The area between the septum and upper nasal concha is the meatus nasi superior, upper half of which is the olfactory area being lined by the olfactory epithelium. The remaining areas are the respiratory areas lined by respiratory epithelium. The border of the olfactory area to the respiratory area is indicated by arrows.

14-02 Concha nasalis media, transverse section. Human, H-E stain, x 2



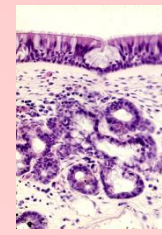
- The surface of the concha is lined by the respiratory epithelium, consistin. Beneath the epithelium there is a thick lamina propria containing submucous glands made up of both mucous and serous cells. Under mucous membrane there are extensive venous plexuses, .

14-03 Mucous membrane of nasal concha, 1. Human, H-E stain, x 10.



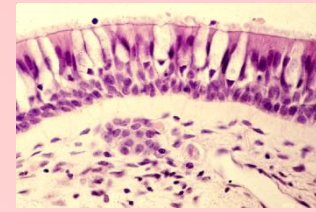
- The surface, the upper edge of this figure, is lined by respiratory epithelium, underlain by a conspicuous thick basement membrane. Beneath it there are connective tissues of lamina propria and tela submucosa, in which small mixed glands are scattered. The lower two thirds of this figure are occupied by venous plexuses; some of their lumens are filled by blood and some others empty.

14-04 Mucous membrane of nasal concha, 2. Human, H-E stain, x 64.



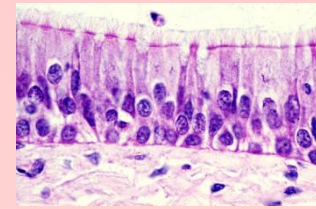
- The epithelium is the pseudostratified ciliated columnar epithelium mixed with goblet cells. The epithelium is underlain by a thick and conspicuous basement membrane. At the center of the epithelium there is an intraepithelial multicellular mucous gland. Beneath it in the connective tissue there is a mixed gland.

14-05 Epithelium of concha nasalis media. Human, H-E stain, x 160.



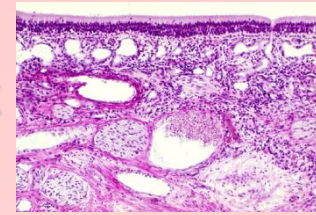
- The epithelium is typical pseudostratified ciliated columnar epithelium, intermingled with numerous goblet cells. At the surface of the ciliated epithelial cells the terminal bar and cilia are evident. Beneath the epithelium is the very thick and conspicuous basement membrane; this is characteristic of respiratory epithelium. Lower to the basement membrane is the loose connective tissue of the lamina propria.

14-06 Epithelium of the respiratory portion. Human, H-E stain, x 250.



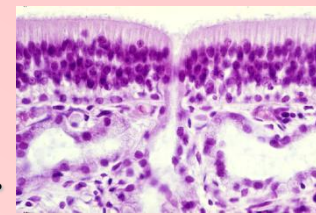
- This specimen is adequately fixed and thin sectioned, so that the structural details are well recognized. The epithelium is the pseudostratified columnar epithelium underlain by a conspicuous basement membrane. The free surface of the tall columnar cells is provided with a distinct terminal bar and numerous long cilia. The basal portion of these cells are slender and attaches to the basement membrane. Among these cells intermingle the goblet cells which contain mucous substance only in the uppermost portion of the cell body. The epithelial cells with nucleus locating near the basement membrane send their thin thread-like cytoplasm to the surface. Beneath the basement membrane is the loose connective tissue.

14-07 Mucous membrane of the olfactory area, 1. Human, H-E stain, x



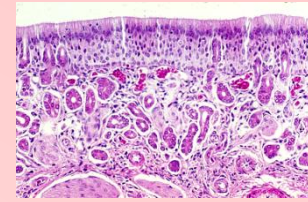
- The olfactory area extends from the middle of the roof of the nasal cavity about 10mm downward on each side of the septum and on the surface of the upper nasal conchae (see 14-01). In fresh condition it is yellowish brown in contrast to the surrounding pink mucous membrane of the area respiratoria. The olfactory epithelium is a tall pseudo- stratified epithelium about $60 \mu\text{m}$ thick. The basement membrane is very thin and in the underlying connective tissue there are special serous glands, Bowman' s gland. Further downward there are numerous nerve fiber bundles, olfactory fibers, and blood vessels. The arrow indicates the opening of the olfactory gland.

14-08 Olfactory epithelium and olfactory glands, 1. Human, H-E stain, x 160.



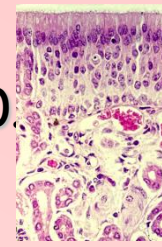
- Higher magnification of 14-07. The olfactory epithelium is a tall pseudostratified columnar epithelium, whose nuclei are arranged roughly in three layers, i.e. the upper-most layer consists of densely packed long elliptic nuclei of supporting cells; the middle layer consists of round nuclei of olfactory cells; and the undermost layer consists of loosely arranged round nuclei of basal cells.
- The supporting cells are tall slender cells extending from the basement membrane to the free surface. Immediately beneath the free surface they unite with one another and with olfactory cells forming a distinct terminal plate and fix the head portion of the olfactory cells.
- The basal cells form a single layer of small conical elements with dark nuclei between the bases of the supporting cells
- The olfactory cells, evenly distributed between the supporting cells, are bipolar nerve cells. Their round nuclei occupy a zone between the nuclei of the supporting cells and that of the basal cells. The apical portion of the cell extends as a cylindrical process from the nucleus to the surface of the epithelium and ends with a bulbous head, which is fixed with terminal complexes with the neighboring supporting cells and projects six to eight olfactory cilia. These olfactory cilia are for the most part nonmotile and extremely long. The proximal portion of the olfactory cells tapers into a thin smooth filament about 1 μ m thick. This is an axon, i.e. a fiber of the olfactory nerve. It passes into the connective tissue and with similar fibers forms small nerve bundles. These are collected into about 20 macroscopically visible fila olfactoria.
- The underlying basement membrane is very thin and underlain with the dense capillary network. In the lamina propria there are the branched, tubuloalveolar olfactory glands of Bowman. The secretory portions (og) are mainly distributed parallel to the surface, whereas the ducts assume a perpendicular course, penetrate the epithelium and open on the surface (arrow).

14-09 Mucous membrane of the olfactory area, 2. Monkey, H-E stain, x 64.



- This specimen is fixed with Zenker-formalin and embedded in paraffin. The fixation was good but the shrinkage of the tissue took place.
- The general features are about the same as 14-07, but the nuclear arrangement in the epithelium is more conspicuous. The lumen of the olfactory glands is less widened than in the 17-07.

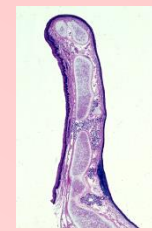14-10 Olfactory epithelium and olfactory glands, 2. Monkey, H-E stain, x 160



- The arrangement of the nuclei in the epithelium is evident. The nuclei of the supporting cells are long elliptic in form and arranged densely perpendicular. These of the olfactory cells, thick spindle in shape, are arranged relatively loose in the wide area and those of basal cells locate on the very thin basement membrane. Beneath the epithelium the lamina propria contains a rich plexus of blood vessels. At upper left corner a duct of the olfactory gland penetrates the epithelium. N indicates the olfactory nerve.

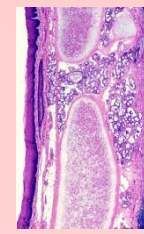
14-002 Larynx

**14-11 Epiglottis, sagittal section, 1, general view. Human,
H-E section, x 2.5.**



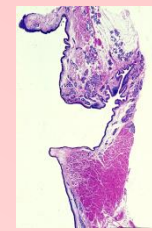
- This is a sagittal section of a human epiglottis; the left side is ventral (oral) and the right side is dorsal. The epiglottis consists of elastic cartilage, the core, covering mucous membrane and connective tissue which fills up the space between the cartilage and mucous membrane. In this figure the axial portion consists of elastic cartilage with several perforations. The epithelium of mucous membrane is, on both oral and dorsal side, stratified squamous. At proximal end of the dorsal surface begins the ciliated pseudostratified columnar epithelium. In the submucous connective tissue small mixed glands are scattered. At the lower right portion there is a small infiltration of lymphocytes.

14-12 Epiglottis, sagittal section, 2 Human, H-E stain, x 9.0.



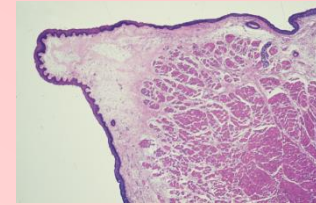
- Higher magnification of the central portion of 14-11. The stratified squamous epithelium is thicker on the oral surface than on the dorsal surface. The core is the typical elastic cartilage. The small mixed glands fills up the perforation of the cartilage.

14-13 Larynx, frontal section. General view. Human, H-E stain, x 2.5.



- This is the frontal section of the human larynx, the right side. At center the hollow toward right is the ventriculus laryngis. The thickset fold upper to this ventricle is the plica ventricularis and the sharp triangular fold down to the ventricle is the vocal fold, in which a large mass of transversely sectioned striated muscle fibers is conspicuous, that is the vocal muscle. In the ventricular fold small mixed gland are scattered in the submucous connective tissue but not in the vocal fold.

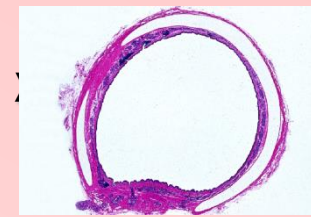
14-14 Plica vocalis, frontal section. Human, H-E stain, x 10.



- This is the frontal section of the vocal cord (higher magnification of 14-13). The sharp tip toward left is vibrated always by air at the vocation, so this portion is covered by stratified squamous epithelium; leaving some distance form this tip the epithelium changes into the pseudostratified ciliated columnar epithelium. Beneath the epithelium there are colorless fiber bundles; they are elastic fibers constituting the vocal ligament.
- Right side of these bundles there is a large mass of transversely sectioned muscle fibers, that is the vocal muscle.

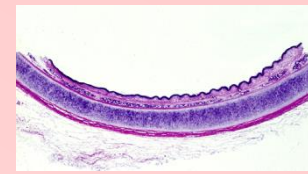14-003 Trachea

14-15 Trachea. transverse section. General view. Human, H-E section, 1.2.



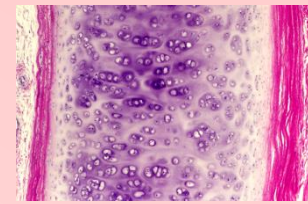
- This is a general view of a human trachea. The trachea is the air conducting tube from the larynx to the lung, and vice versa, and runs perpendicular before the esophagus. The trachea (and bronchus) contains in the wall hyaline cartilage of C-form, opening backward, at an constant interval and the inner surface is covered by mucous membrane. The epithelium is the pseudostratified ciliated columnar and subepithelial connective tissue contains small mixed glands, they are numerous in the posterior wall.
- The core of the posterior wall is the smooth muscle fiber bundles, instead of the cartilage. Outside of the cartilage and smooth muscle fiber bundles encloses the loose connective tissue, i.e. the adventitia.

14-16 Wall of the trachea. General view. Human, H-E stain, x 3.0.



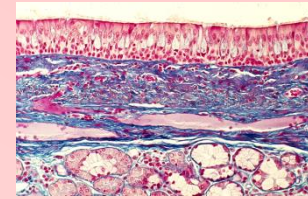
- This is a part of the trachea, sectioned transversely. The upper edge of this figure is the mucous membrane. Beneath it follow submucous connective tissue containing the glands and the thick tracheal cartilage staining deep blue-violet and the adventitia.

14-17 Cartilage of the trachea. Human, H-E stain, x 64.



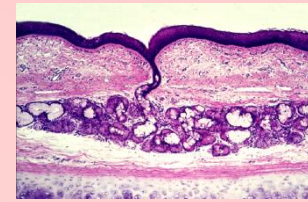
- The tracheal cartilage has the perichondrium on both inner (left) and outer (right) surfaces, but that of outer side is much thicker. The tracheal cartilage is the hyaline cartilage. Gradual change from the fibroblasts into the cartilage cells is on both sides observed. In the central portion of the cartilage the metachromasia of the cartilage matrix is conspicuous.

14-18 Mucous membrane of the trachea. Human, M-G stain, x 50.



- The epithelium is the pseudostratified ciliated columnar epithelium, intermingled with numerous goblet cells. The basement membrane is conspicuous. The lamina propria sifts into the subcutaneous connective tissue without any boundary. At the bottom of this figure there is a mixed gland, tracheal gland.

14-19 Tracheal gland. Human, H-E stain, x 25.

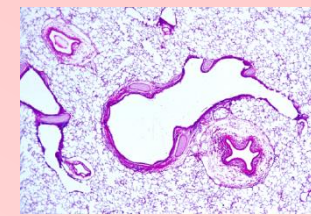


- At center there is a tracheal gland with an excretory duct which opens onto the surface of the epithelium. The lowermost portion of this figure occupies the tracheal cartilage with the perichondrium. As this specimen is thick so that the histological details are not sharply observed.

14-004 Lung

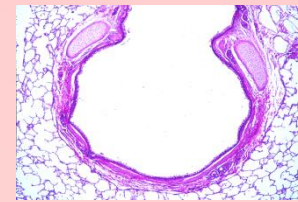
- The lung is the organ in which the intake of oxygen in the inspired air and the elimination of carbon dioxide produced by metabolism of cells throughout the body takes place. Carbon dioxide is carried to the lungs and oxygen is carried from them to the tissues by the circulatory system.

14-20 Lung, 1. General view. Monkey, H-E stain, x 4.0.



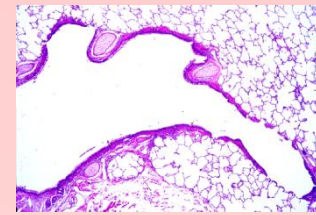
- Because the human lungs are very large organs, it is difficult to imagine the structure of the lungs from the specimen of 10 mm². To facilitate the understanding of the structure of the lungs, this specimen was prepared as follows: ① perfused 10 % formalin from the right ventricle of a monkey; ② taken out the lungs with trachea and put them in toto in 10 % formalin and gently pressed the lungs repeatedly to drive out the air; ③ infused 10 % formalin from the trachea into the lungs gently until the lungs regain the original largeness; ④ put them in toto again in 10 % formalin for a week; ⑤ dehydrated and embedded in celloidin and thin sectioned a whole pulmonary lobe. Thus this specimen is 24 x 36 mm wide, in which the fundamental elements, from the bronchus until the alveoli, are all well recognized. Figures from 14-20 to 14-26 are selected in this specimen.
- This (14-20) is a general view of the lung. At center from the bronchus lobaris to the bronchulus respiratorius are continuously seen, lower right to that is the pulmonary artery. They are surrounded by the alveolar ducts, alveolar sacs and alveoli, that assume the spongy appearance. Br: ramus bronchialis, brt: bronculus terminalis, brr: bronchulus respiratorius; Ap: pulmonary artery, Vp: pulmonary vein.

14-21 Lung, 2. Intrapulmonary bronchus. Monkey, H-E stain, x 10.



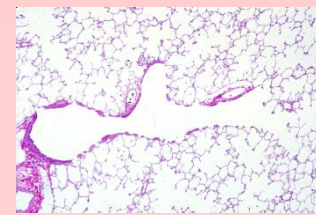
- This is a branch of the bronchus (bronchus lobaris, Br), the wall of which consists of mucous membrane, circular smooth muscle fibers and connective tissue. At the upper- most part it contains the small cartilages outside of smooth muscle. In the submuscular connective tissue small glands are scattered.

14-22 Lung, 3. Terminal bronchiole. Monkey, H-E stain, x 10.



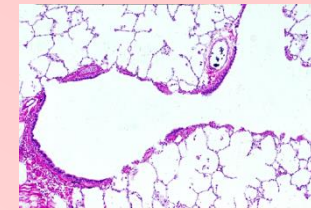
- In the middle, from bronchus lobaris, bronchulus terminalis and bronchulus respire- torius are continuously seen. In the wall of the bronchus lobaris and bronchulus terminalis small masses of cartilage are still observed. In the bronchulus respiratorius the mucous membrane is here and there breaks off and open the alveoli (arrows).

**14-23 Lung, 4. Respiratory bronchiole and alveoli, 1. Monkey,
H-E stain, x 12.5.**



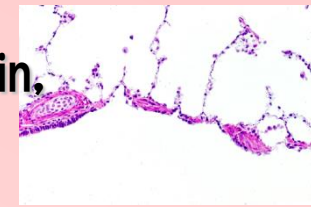
- In the middle traverses a respiratory tree from the terminal bronchiole (brt) and respiratory bronchiole (brr) until the alveolar duct (dal). Around this is filled by the alveolar ducts (dal), alveolar sacs (sal) and alveoli. Arrows indicate the alveolar openings from the wall of the respiratory bronchiole. At center on the left side of a respiratory bronchiole (brr), the mucous membrane is underlain by a branch of the pulmonary artery (Ap), and on the opposite side open the alveoli (arrow heads). The same condition is recognized at more right side of this figure (brr and Ap).

**14-24 Lung, 5. Respiratory bronchiole and alveoli, 2. Monkey,
H-E stain, x 25.**



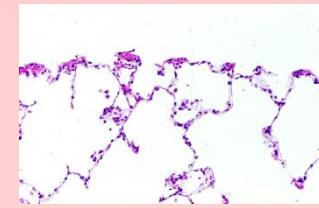
- Higher magnification of 14-23. At the left edge there is the semicircular wall of the terminal bronchiole (brt) consisting of the mucous membrane and submucous connective tissue in which smooth muscle fiber bundle is evident. At the upper left corner and lower right corner of this open the alveoli (arrows) and from here begins the respiratory bronchiole (brr). More rightly there is the mucous membrane (brrx) and a branch of the pulmonary artery (Ap). This portion is the respiratory bronchiole. On the opposite side open the alveoli (arrow heads). Around this respiratory tree is filled by the alveoli.

14-25 Lung, 6. Respiratory bronchiole and alveoli, 3. Monkey, H-E stain, x 64.



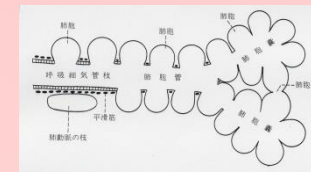
- Higher magnification of 14-24. The lower one third of this figure is the lumen of the respiratory bronchiole. Upper limit of this lumen is the wall of the respiratory bronchiole. At its left end the wall consists of a simple columnar epithelial cells and underlying connective tissue, in which a small mass of hyaline cartilage is seen. Following rightward the wall is interrupted at intervals and each time open the alveolus (arrows). The remaining wall is covered by a few epithelial cells underlain by smooth muscle fibers. Upper to this wall is filled by alveoli (alv) and alveolar sacs (als).

14-26 Lung, 7. Alveolar duct and alveoli, 1. Monkey, H-E stain, x 64.



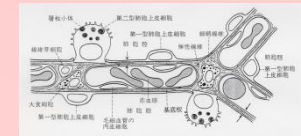
- Higher magnification of 14-23. The upper one third of this figure is the lumen of the alveolar duct (dal). The lower limit of this lumen is the wall of the alveolar duct which is interrupted at about the same interval and there open the alveolus (arrows). The wall itself consists of a few epithelial cells and underlying smooth muscle fibers. Lower to this wall is filled by alveoli (alv) and alveolar sacs (sal).

14-27 Scheme showing the branching of the respiratory tree.



- The bronchus divides at pulmonary hilus into the lobal branches which enter the pulmonary lobe. They repeat branching and become thinner until attaining the lobular branches of about 1.0 mm in diameter and enter the pulmonary lobule. They branch further and become the terminal bronchioles, until which they are all air conducting ducts. They are accompanied by the branches of the pulmonary artery and bronchial artery, lymphatics and nerves. One terminal bronchiole divides usually into two or three respiratory bronchioles.
- Each respiratory bronchiole is accompanied by a branch of the pulmonary artery on one side of the wall which consists of the mucous membrane and underlying connective tissue containing the smooth muscle fibers. On the opposite side of the wall begin the alveoli, that are the excretory portions. The respiratory bronchioles divide at their distal end into several alveolar ducts and each divides into several alveolar sacs, whose wall is composed exclusively by the alveoli. At the distal end of the respiratory bronchiole, the concomitant arteries empty into the capillary networks in the wall of the alveoli. In the wall of the respiratory bronchioles and in that of the alveolar ducts smooth muscle fibers encircle the beginning of the alveoli but in the alveolar ducts such smooth muscle fibers do not exist.
- Observing specimens of the human lung we encounter only a few sections of the duct systems and otherwise the whole field is filled by alveoli of spongy appearance. So it is difficult especially for the beginners to imagine such a general structure of the lung. Each alveolus comes to contact with neighboring one and their walls unite one another forming a common wall, so that the spaces between alveoli do not exist.

14-28 Scheme showing the ultra fine structure of the alveolar epithelium.



- This is to show the ultrastructure of the alveolar wall based on the electronmicroscopy. The alveolar wall, often called alveolar septum, is composed of the alveolar capillary networks, as the core, and alveolar epithelium which covers on both sides of this core. There are two kinds of epithelial cells, i.e. the type I and the type II.
- The alveolar epithelium of type I is the quite flat cell, only whose flat nucleus is perceived on the inner surface of the alveolus. The cytoplasm of the type I cells is very thin so that it is not perceived by the light microscopy. This very thin cytoplasm covers the inner surface of the alveolus, and is opposed to the capillary endothelium with a very narrow interspace, containing the basal lamina, which is common to both cells. The distance from the inner surface of the type I cells to the inner surface of the capillary endothelial cells is estimated only about $0.5\ \mu\text{m}$ (indicated with opposite two arrows). In the meshes of the capillary network there are a few reticular fibers, elastic fibers and fibroblasts as well as macrophages
- The alveolar epithelium of type II is thickset cuboidal cell standing on the basal lamina and protruding into the alveolar cavity. It provides numerous short microvilli on the apical free surface and contains small lamellar bodies, which are blackened by osmic acid, in the apical portion of the cytoplasm. They are discharged into the alveolar cavity in the same manner as eccrine secretion and spread upon the surface of the epithelium, lower surface tension and tend to stabilize alveolar diameter. They are thought as a kind of surfactant.



Menu

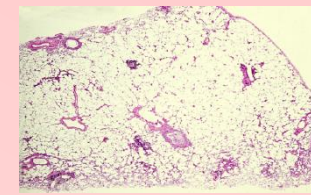


Back



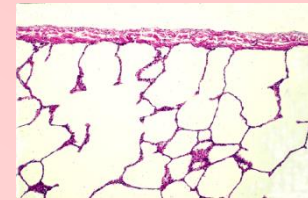
Next

14-29 Human lung, 1. General view. H-E stain, x 1.3.



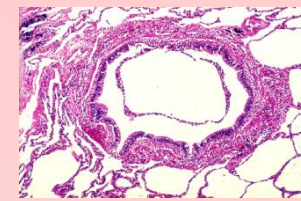
- This is a human lung specimen, prepared without any special treatment. The right edge is the surface of the lung covered by pulmonary pleura; The upper and lower edges are the cut surface of the lung and in the neighboring portion to them alveoli are collapsed. At the upper left corner of this figure there is a transverse section of the terminal bronchulus and below it is a section of the pulmonary vein. At center there are sections of a terminal bronchulus and a concomitant branch of pulmonary artery.

14-30 Human lung, 2. Pleura and alveoli. H-E stain, x 25.



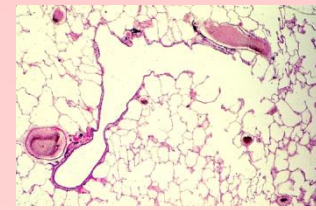
- Higher magnification of 14-29. The upper edge is the pleura and underlying connective tissue. Beneath it the space is filled by alveoli (alv). The alveolar duct (dal) and alveolar sac (sal) are also encountered. The fine structure of the alveolar wall is not observed at this magnification.

14-31 Human lung, 3. Terminal bronchulus and alveoli. H-E stain, x 25.



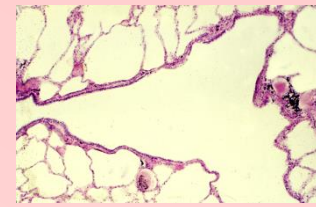
- This is transverse section of a terminal bronchulus observed in 14-29. The wall of this terminal bronchulus consists of mucous membrane and submucous connective tissue, in which thin smooth muscle fiber bundles encircling the lumen are observed, but no cartilages. The epithelium is the pseudostratified ciliated columnar epithelium intermingled by goblet cells. Around this bronchulus alveoli are collapsed.

14-32 Human lung, 4. General view. H-E stain, x 10.



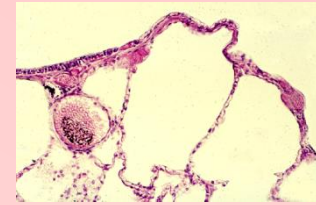
- This is another specimen, which was fixed by perfusion of 10% formalin into the femoral artery. The lung was taken out thereafter so that the form and fine structure of the lung are well preserved.
- At lower left corner there is a terminal bronchiole (brt) being concomitant with a branch of the pulmonary artery (Ap). This goes upward and divides into two respiratory bronchioles (brr). The right one proceeds right ward and divides into two alveolar ducts (dal). At upper right corner there is a branch of the pulmonary artery concomitant with a respiratory bronchiole. Excepting these are all alveoli.

**14-33 Human lung, 5. Terminal bronchiole and respiratory bronchiole.
H-E stain, x 25.**



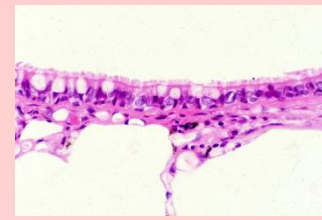
- Higher magnification of 14-32. In the middle the terminal bronchiole goes rightward and shifts into the respiratory bronchiole (arrows), which divides into two (brr).

**14-34 Human lung, 6. Respiratory bronchiole and alveoli.
H-E stain, x64.**



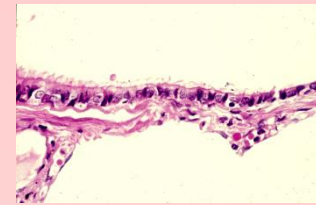
- Higher magnification of 14-33. The uppermost space is the lumen of a respiratory bronchiole (brr). At upper left corner wall of this respiratory bronchiole is lined by simple ciliated columnar epithelium but at the point of an arrow the epithelium interrupts suddenly and begins the alveolus. Alv:alveolus, Ap:branch of pulmonary artery.

**14-35 Human lung, 7. Terminal bronchiole and alveoli, 1.
H-E stain, x 160.**



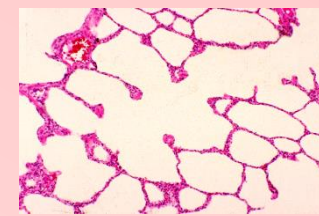
- The uppermost space is the lumen of a terminal bronchiole, whose wall is lined by a pseudostratified ciliated columnar epithelium intermingled by numerous goblet cells. On the left side the columnar epithelial cells are tall and intermingled by goblet cells. As going to right the height of the epithelial cells becomes lower, their arrangement becomes simple and the goblet cells disappear. Beneath the epithelium underlies the connective tissue. Lower to this wall there are two alveoli separated by a thin alveolar septum (indicated by two opposite arrows).

**14-36 Human lung, 8. Terminal bronchiole and alveoli, 2.
H-E stain, x 160.**



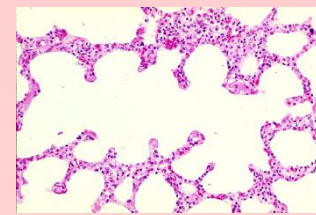
- This is a further distal portion than 14-35. The epithelium of the respiratory bronchiole on the left side is pseudostratified ciliated columnar epithelium intermingled by goblet cells but on the right side it becomes simple cuboidal cells without cilia. The lower half of this figure occupies a single alveolus whose wall is composed with capillary network (arrows).

14-37 Human lung, 9. Alveolar duct and alveoli, 1. H-E stain, x 33.



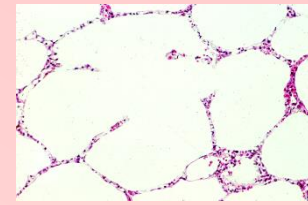
- The air conducting duct, whose wall is composed exclusively of alveoli, is the alveolar duct (dal). From the wall of the alveolar duct alveoli open and bulge out at regular interval. At each opening a thin smooth muscle fiber bundle encircles the opening (arrows).

14-38 Human lung, 10. Alveolar duct and alveoli, 2. H-E stain, x 64.



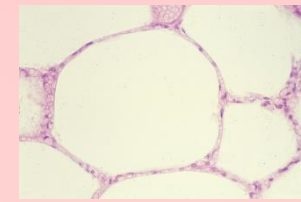
- This is also an alveolar duct (dal), from which numerous alveoli bulge out. At each opening thin smooth muscle fiber bundle encircles (arrows).

14-39 Human lung, 11. Alveolar sac and alveoli. H-E stain, x 25.



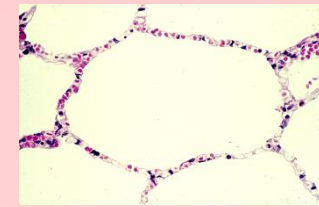
- This is an alveolar sac, from which four alveoli bulge out. At their opening no smooth muscle fiber bundle is seen.

14-40 Alveoli, 1. Human, H-E stain, x 100.



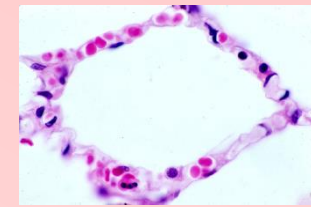
- This specimen was prepared from a cadaver which was fixed by perfusion of 10% formalin. Because of this, the form of the alveoli is well preserved but blood in the capillary network was derived out causing the capillary lumen almost empty.
- The wall of alveolus (often called alveolar septum, indicated with two opposite arrows) is composed of capillary net, as a core, and extremely flattened thin epithelial cells covering the capillary net on both sides. This is the alveolar epithelial cells of type I. The thickness of the type I cells is beyond the visibility with the light microscope (less than $0.2 \mu\text{m}$). The alveolar epithelial cells of type II is not perceived in this field.

14-41 Alveoli, 2. Human, H-E stain, x 100.



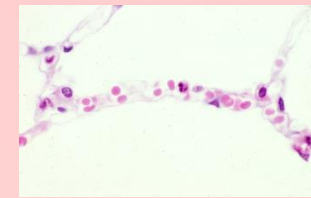- In this specimen driving of blood from the capillaries was not complete and a few erythrocytes remained; This condition makes favorable to understand the structure of the alveolar septum. The alveolar septum, indicated with two opposite arrows, consists of capillary net and very thin cytoplasm of the alveolar epithelial cells of type I, covering both side of the capillary net. The alveolar epithelial cells of type II are not identified in this figure.

14-42 Alveoli, 3. Human, H-E stain, x 250.



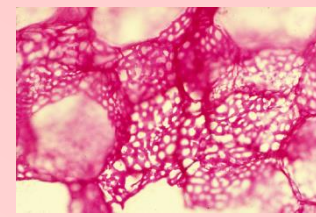
- High power magnification of the alveolar septum. The alveolar septum consists of capillary net, as core, and very thin cytoplasm of alveolar epithelium covering both sides of capillary net. The thickness of the alveolar septum is thus practically equal to that of capillary. In this figure an alveolar epithelial cells of type II is recognized in the lower middle portion (single arrow). This is a round or cuboidal cell, protruding into the alveolar lumen, with a large round nucleus and plenty basophilic cytoplasm. A flat nucleus indicated with double arrows has a possibility to be the nucleus of the type I cell but there is no sound criterion for identification. Alv: cavity of the alveoli

14-43 Alveoli, 4. Human, H-E stain, x 250.



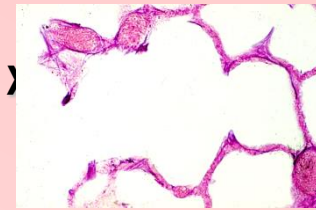
- In the middle traverses an alveolar septum between alv 1 and alv 2, whose structure is quite the same as 14-42. At the right and left end of this septum, on the upper side, there are each one type II cell (arrows). They locate at the junction of two septa. Their plenty basophilic cuboidal cytoplasm protrudes into the alveolar lumen and contains a large and round nucleus.

14-44 Capillary network in the alveolar wall. Human, infusion with cinnabar. x 64.



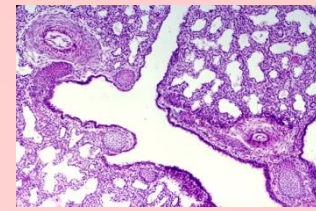
- A thin solution of glue suspended with cinnabar is infused gently into the right ventricle. After the glue was hardened the lung was sectioned at about $100\ \mu\text{m}$ thickness. Thus the dense capillary network in the alveolar wall was visualized. At the left end of the field one alveolus shows a perspective figure.

14-45 Elastic fibers in the alveolar wall. Human, resorcin-fuchsin stain, x64.



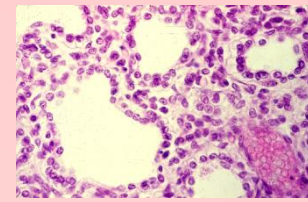
- In the alveolar wall there are a few elastic fibers, which make return the alveolar volume after expiration. Deep violet stained elastic fibers run loosely in the wall of the alveoli. alv is alveolus, dal: alveolar duct; sal: alveolar sac.

14-46 Lung of embryo, 1. Monkey, H-E stain, x 25.



- This is the lung of a monkey embryo near the terminal. During the embryonic period, the lung is small and does not act the respiratory function. Its structure is quite different from the after birth condition and somewhat similar to that of excretory glands. The lung consists of innumerable irregular lumina lined by cuboidal epithelial cells and a lot of interstitial cells. This figure shows the general view of the embryonic lung. A: branch of bronchulus (rbr) and a terminal bronchiole (brt) are seen. In their wall cartilage masses and branch of pulmonary artery are encountered.

14-47 Lung of embryo, 2. Monkey, H-E stain, x 160.



- Higher magnification of 14-47. Five large lumina lined by cuboidal epithelial cells and innumerable interstitial cells filling among them are seen. At lower right corner there is a branch of blood vessel. After birth these cuboidal cells are extended extremely to become the alveolar epithelial cells. The interstitial cells are also extended and become interstitial elements of the lung.