

# 09-00

# Digestive System

# 1

# 09 Digestive System 1

## Menu 1/2

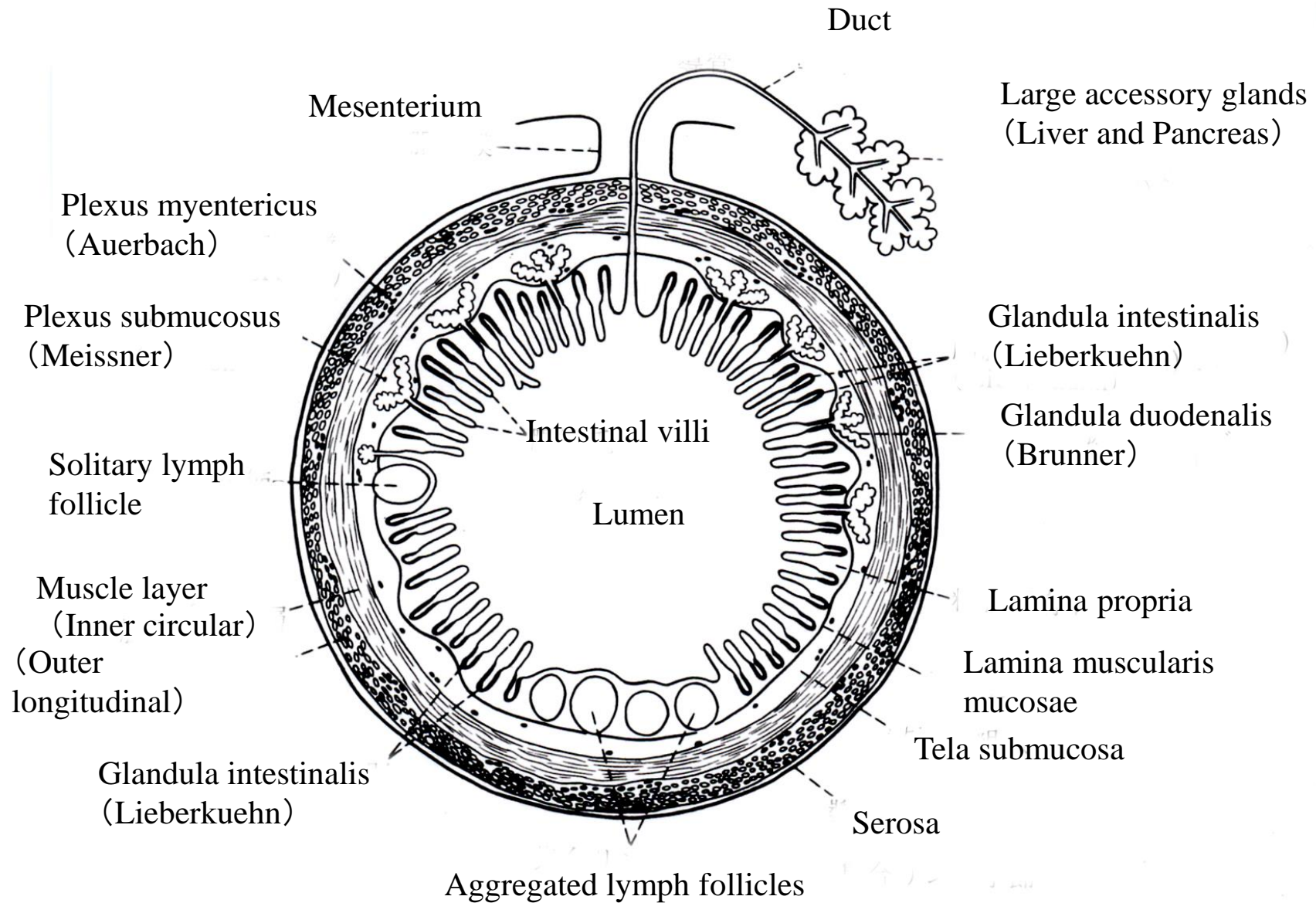
- [09-00.](#) Digestive System 1
- [09-01.](#) General structure of the digestive system ( Scheme )
- [09-001.](#) Oral Cavity
- [09-02.](#) Lip, sagittal section, Human, H-E stain, x 1.2.
- [09-03.](#) Apex linguae, sagittal section. Human, H-E stain, x 1.7.
- [09-04.](#) Corpus linguae, transverse section. Monkey, H-E stain, x 1.3.
- [09-05.](#) Papilla filiformis. Human, H-E stain, x 25.
- [09-06.](#) Papilla fungiformis. Human, H-E stain, x 25.
- [09-07.](#) Papilla vallata, 1. Human, H-E stain, x 4.0.
- [09-08.](#) Papilla vallata, 2. Human, H-E stain, x 3.0.
- [09-09.](#) Papillae foliatae. Human, H-E stain, x 3.0.
- [09-10.](#) Taste buds, 1. Monkey, H-E stain, x 64.
- [09-11.](#) Taste buds, 2. Monkey, H-E stain, x 160.
- [09-12.](#) Taste bud. Human, Suzuki's silver impregnation, x 200.
- [09-13.](#) Radix linguae, tonsilla lingualis. Human, H-E stain, x 2.0.
- [09-14.](#) Tonsilla palatine. Human, H-E stain, x 2.0.
- [09-002.](#) Salivary Glands
- [09-15.](#) Structure of three large salivary glands ( Scheme ).
- [09-0021.](#) Gl. Parotis
- [09-16.](#) Gl. parotis, 1. General view. Human, H-E stain, x 2.2.
- [09-17.](#) Gl. parotis, 2. Low power magnification. Human, H-E stain, x 25.

- [09-18.](#) Gl. Parotis, 3. Intercalated duct and striated duct. Human, H-E stain, x 160.
- [09-19.](#) Gl. parotis, 4. Intercalated duct. Human, H-E stain, x 160.
- [09-20.](#) Gl. parotis, 5. Intercalated duct, transverse section. Human, H-E stain, x 160.
- [09-21.](#) Gl. parotis, 6. Intercalated duct. Human, H-E stain, x 160.
- [09-22.](#) Gl. parotis, 7. General view of another parotid gland. Human, H-E stain, x 25.
- [09-23.](#) Gl. parotis, 8. Striated and intercalated duct. Human, H-E stain, x 100.
- [09-24.](#) Gl. parotis, 9. Striated duct and intercalated duct. Human, H-E stain, x 160.
- [09-25.](#) Gl. parotis, 10. Striated duct and intercalated duct. Human, H-E stain, x 100.
- [09-26.](#) Gl. parotis containing less fat cells. Human, H-E stain, x 2.2.
- [09-0022.](#) Gl. Submandibularis
- [09-27.](#) Gl. submandibularis, 1. Human, H-E stain, x 2.5.
- [09-28.](#) Gl. submandibularis, 2. Human, H-E stain, x 40.
- [09-29.](#) Gl. submandibularis, 3. Human, H-E stain, x 40.
- [09-30.](#) Gl. submandibularis, 4. Human, H-E stain, x 100.
- [09-31.](#) Gl. submandibularis, 5. Human, H-E stain, x 100.
- [09-32.](#) Gl. submandibularis, 6. Human, H-E stain, x 160.
- [09-33.](#) Gl. submandibularis, 7. Monkey, H-E stain, x 160.

# 09 Digestive System 1

## Menu 2/2

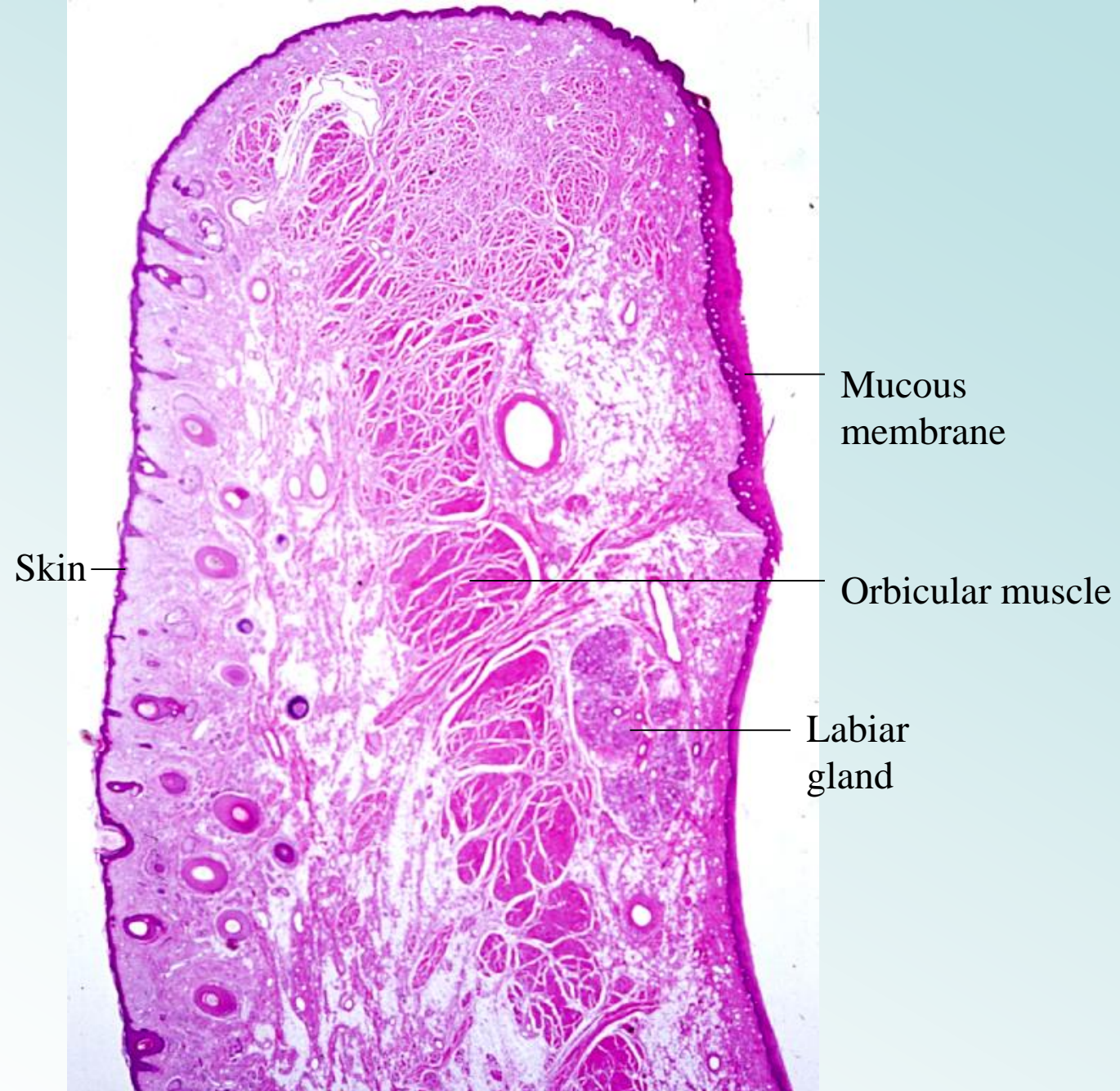
- [09-34.](#) Gl. submandibularis, 8. Secretion granules. Human, H-E stain, x 160.
- [09-35.](#) Gl. submandibularis, 9. Striated ducts. Human, H-E stain, x 160.
- [09-36.](#) Gl. submandibularis, 10. Human, H-E stain, x 160.
- [09-37.](#) Gl. submandibularis, 11. Intercellular secretory canaliculi. Human, H-E stain, x250.
- [09-0023.](#) Gl. Sublingualis
- [09-38.](#) Gl. sublingualis, 1. General view. Human, H-E stain, x 2.2.
- [09-39.](#) Gl. sublingualis, 2. Human, H-E stain, x 25.
- [09-40.](#) Gl. sublingualis, 3. Human, H-E stain, x 64.
- [09-41.](#) Gl. sublingualis, 4. Mucous acini and demilunes. Human, H-E stain, x 160.
- [09-42.](#) Gl. sublingualis, 5. Human, H-E stain, x 100.
- [09-43.](#) Gl. sublingualis, 6. Human, H-E stain, x 66.





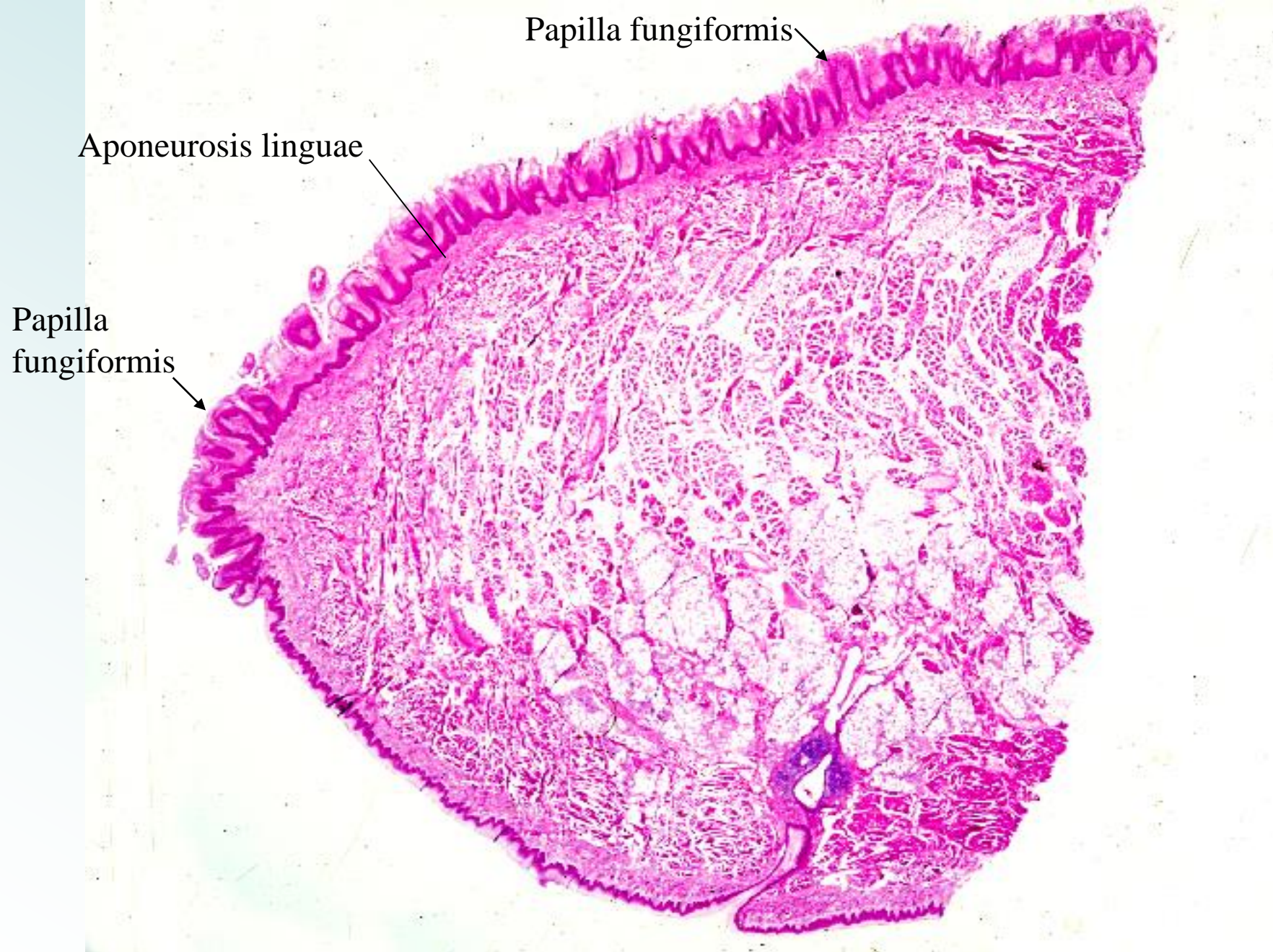
# 09-001

# Oral Cavity



09-02 Lip, sagittal section, Human, H-E stain, x 1.2.



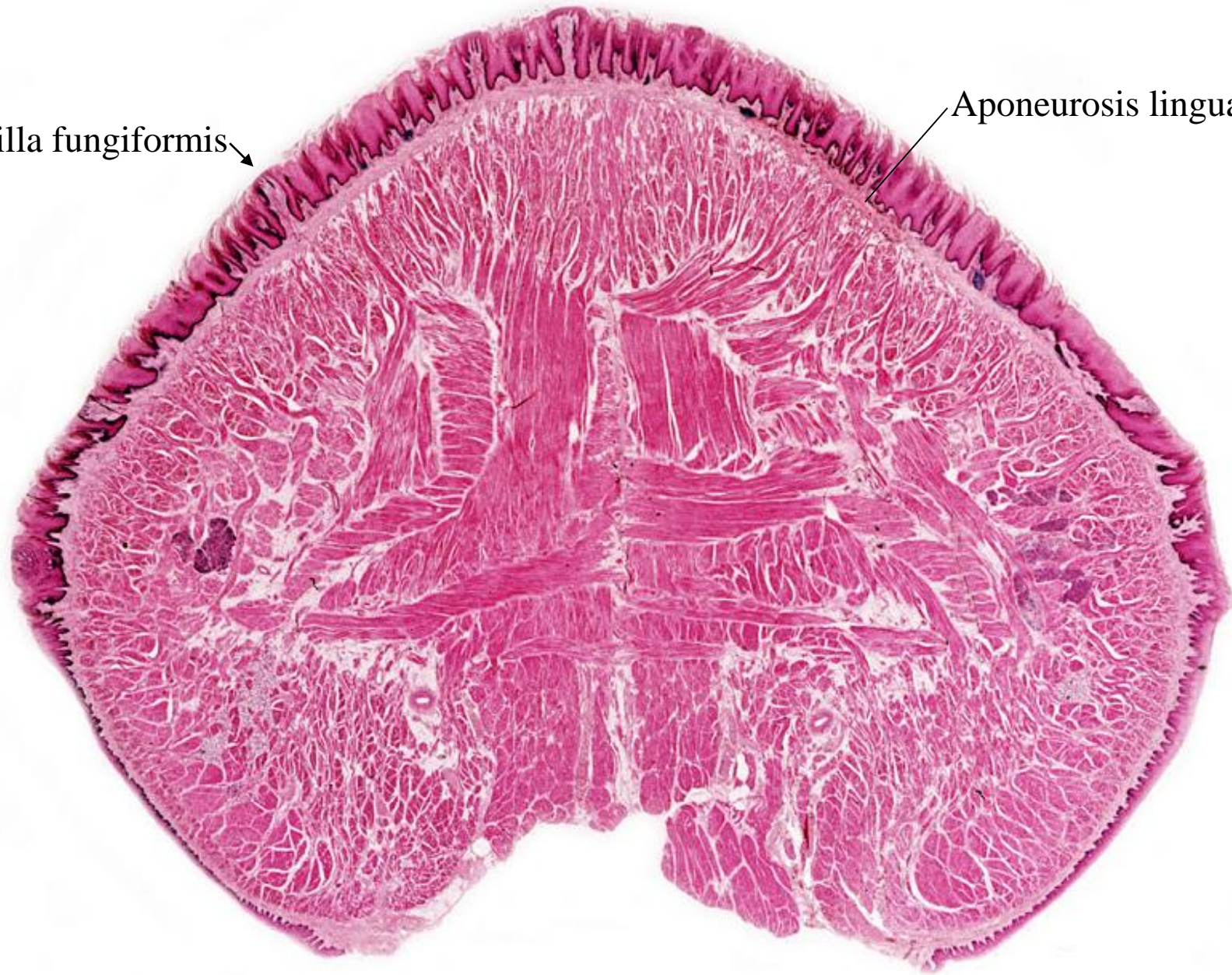


09-03 Apex linguae, sagittal section. Human, H-E stain, x 1.7.

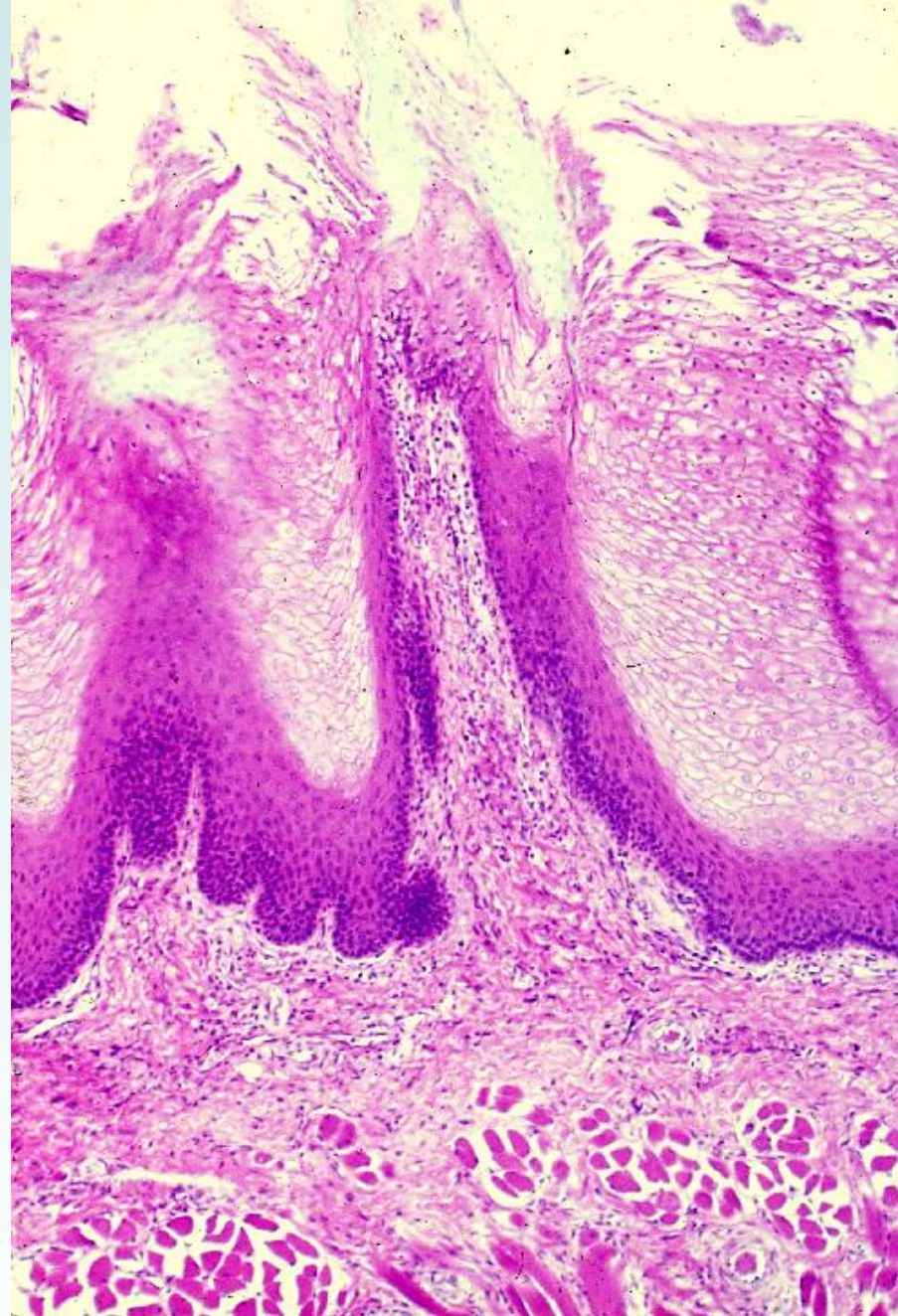


Papilla fungiformis

Aponeurosis linguae

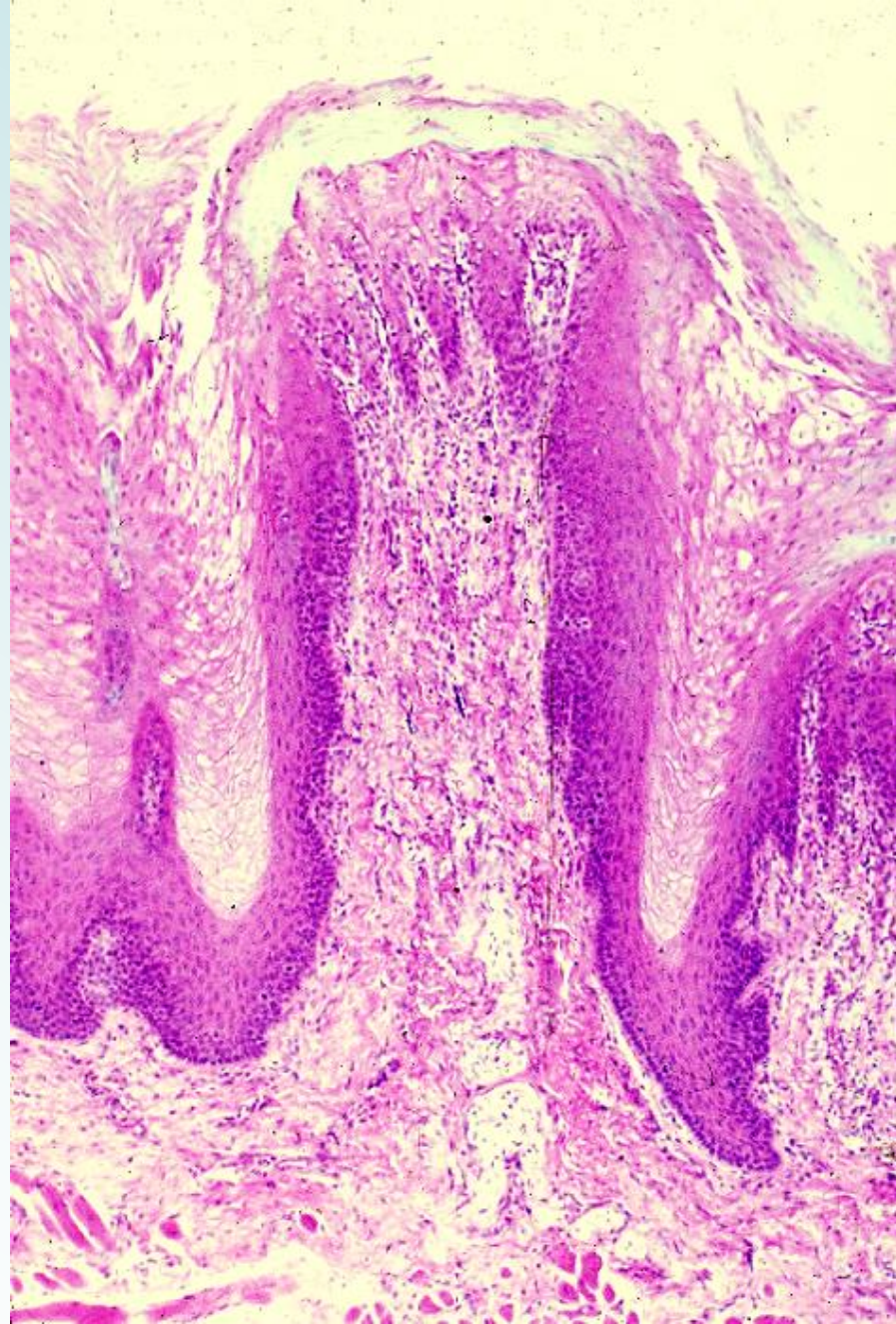






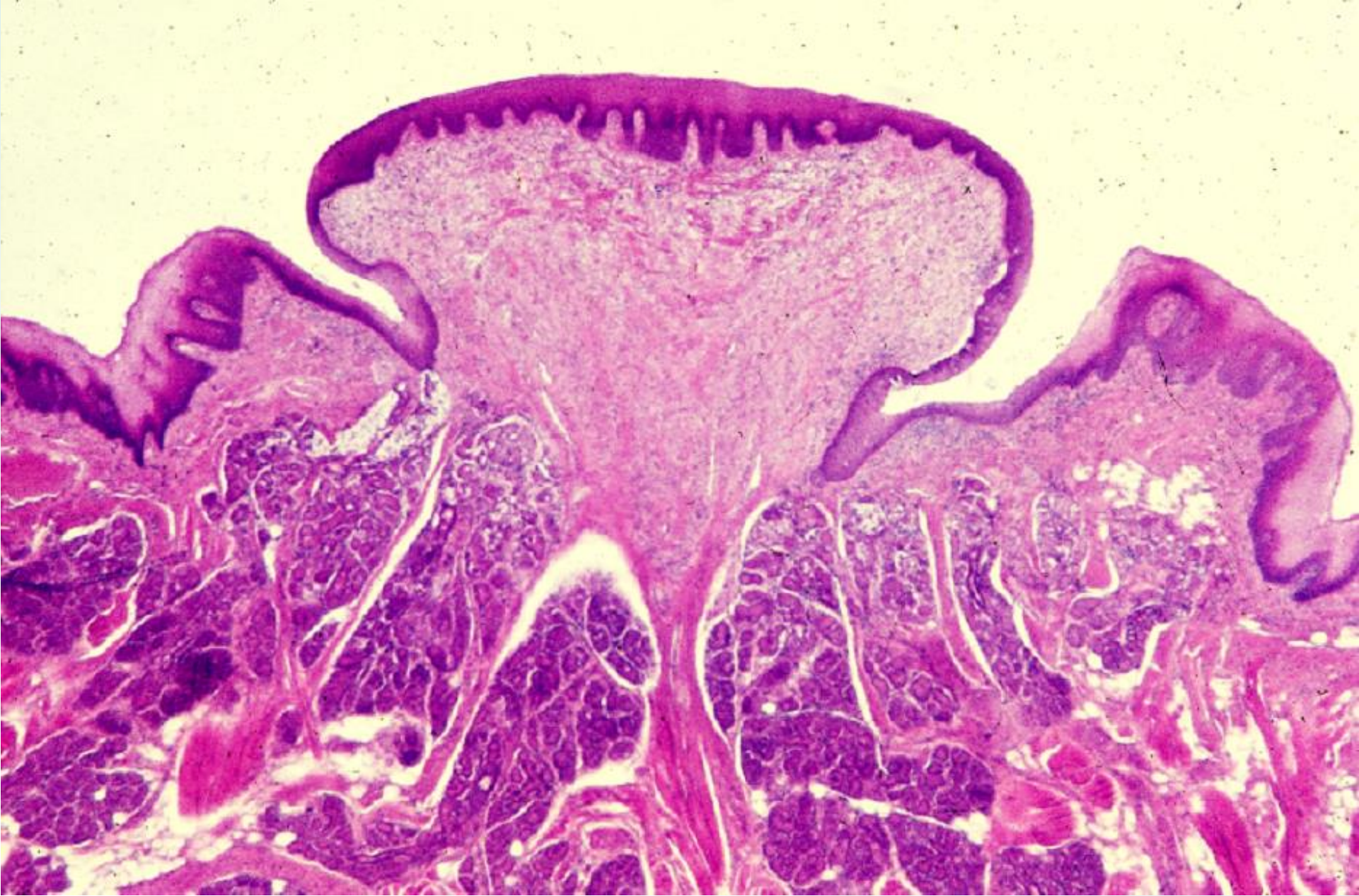
09-05 Papilla filiformis. Human, H-E stain, x 25.





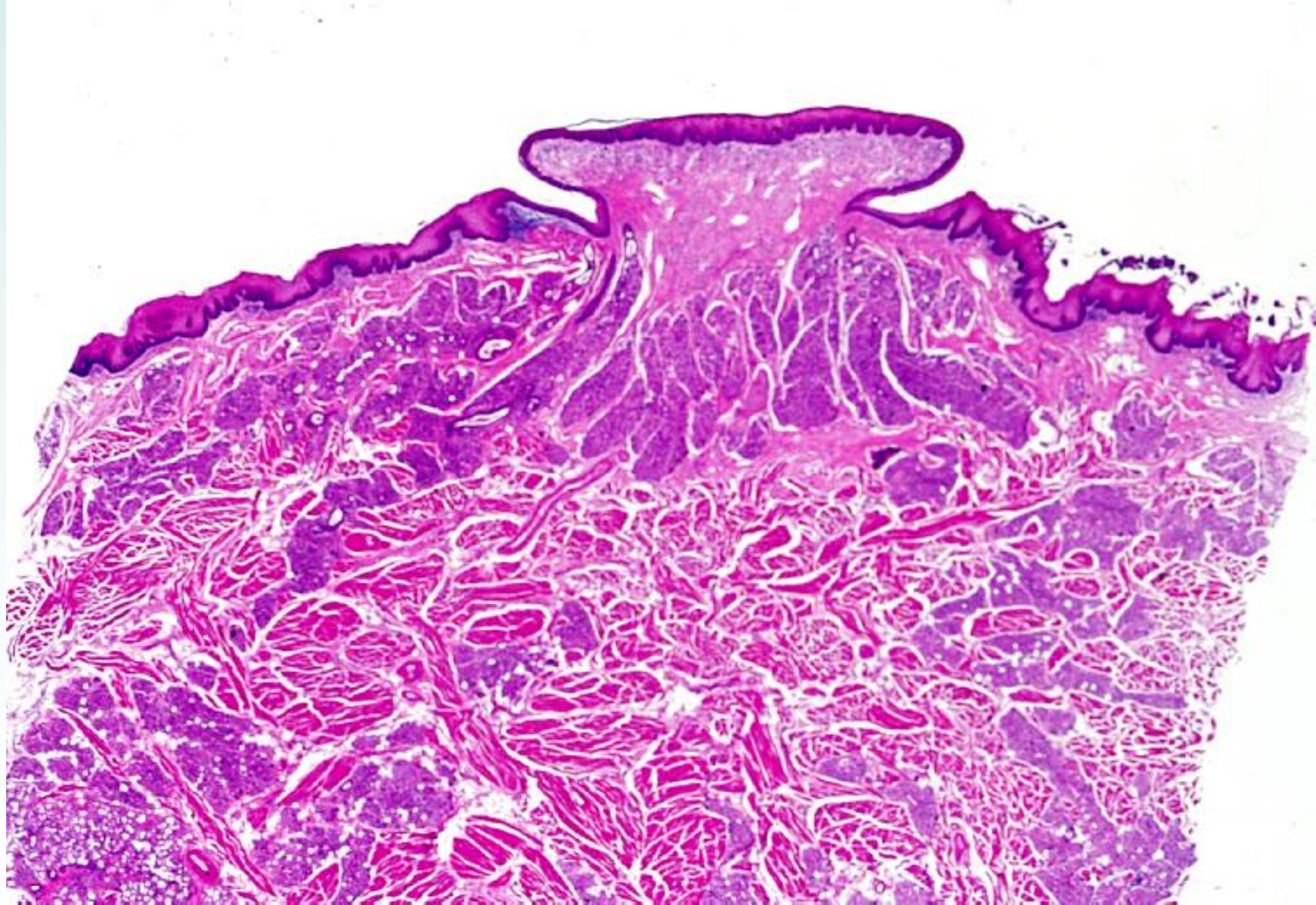
09-06 Papilla fungiformis. Human, H-E stain, x 25.





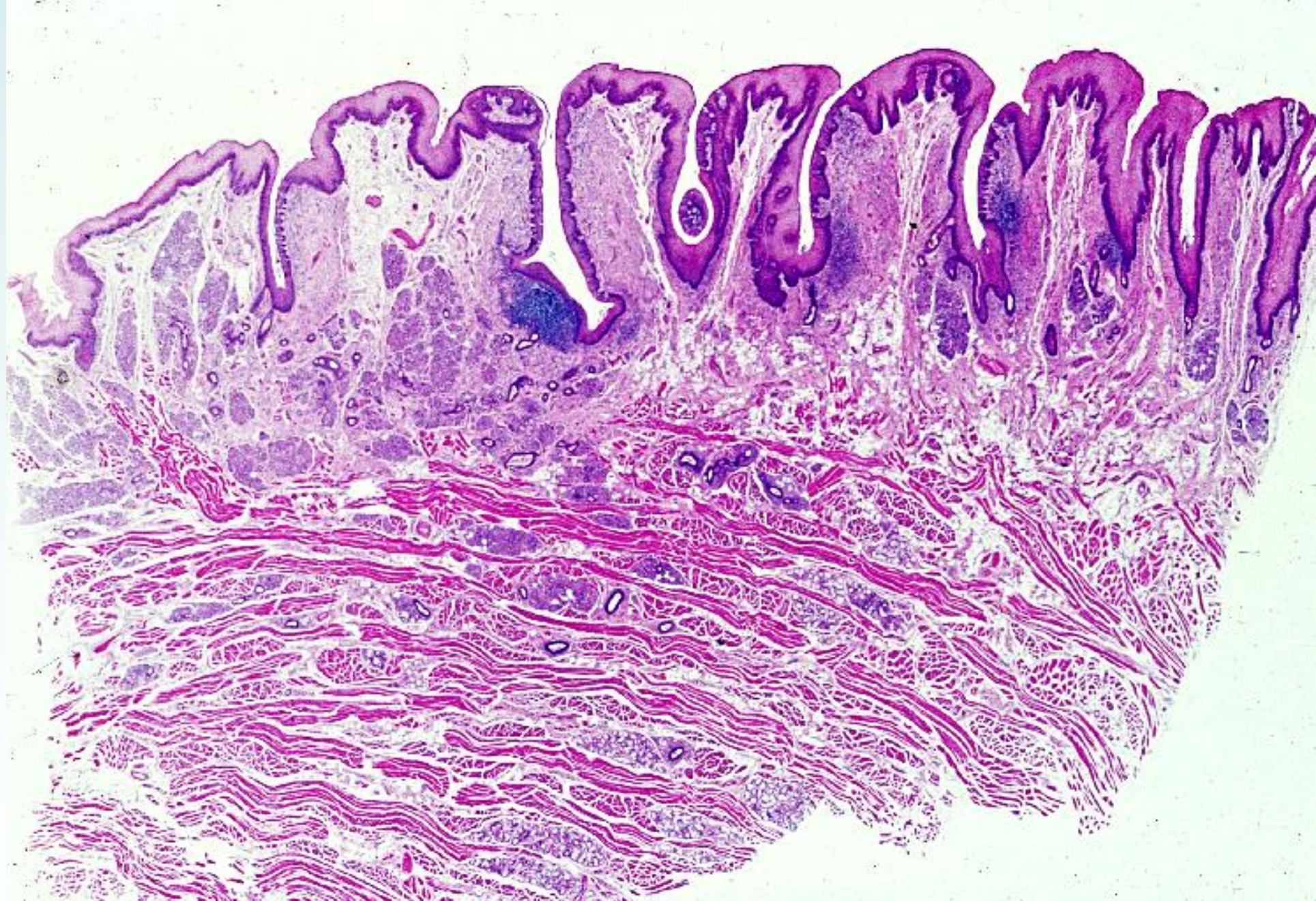
09-07 Papilla vallata, 1. Human, H-E stain, x 4.0.





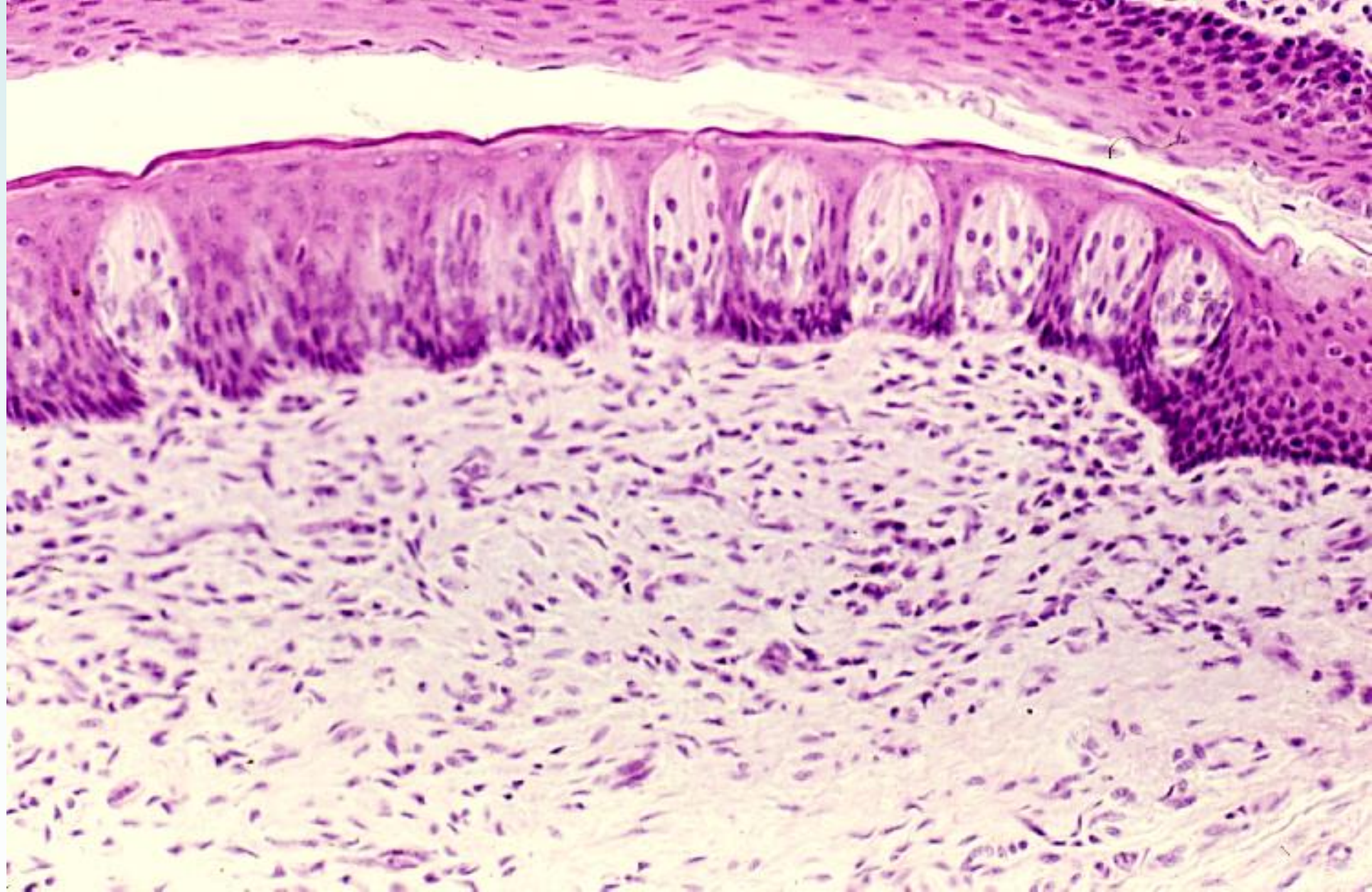
09-08 Papilla vallata, 2. Human, H-E stain, x 3.0.





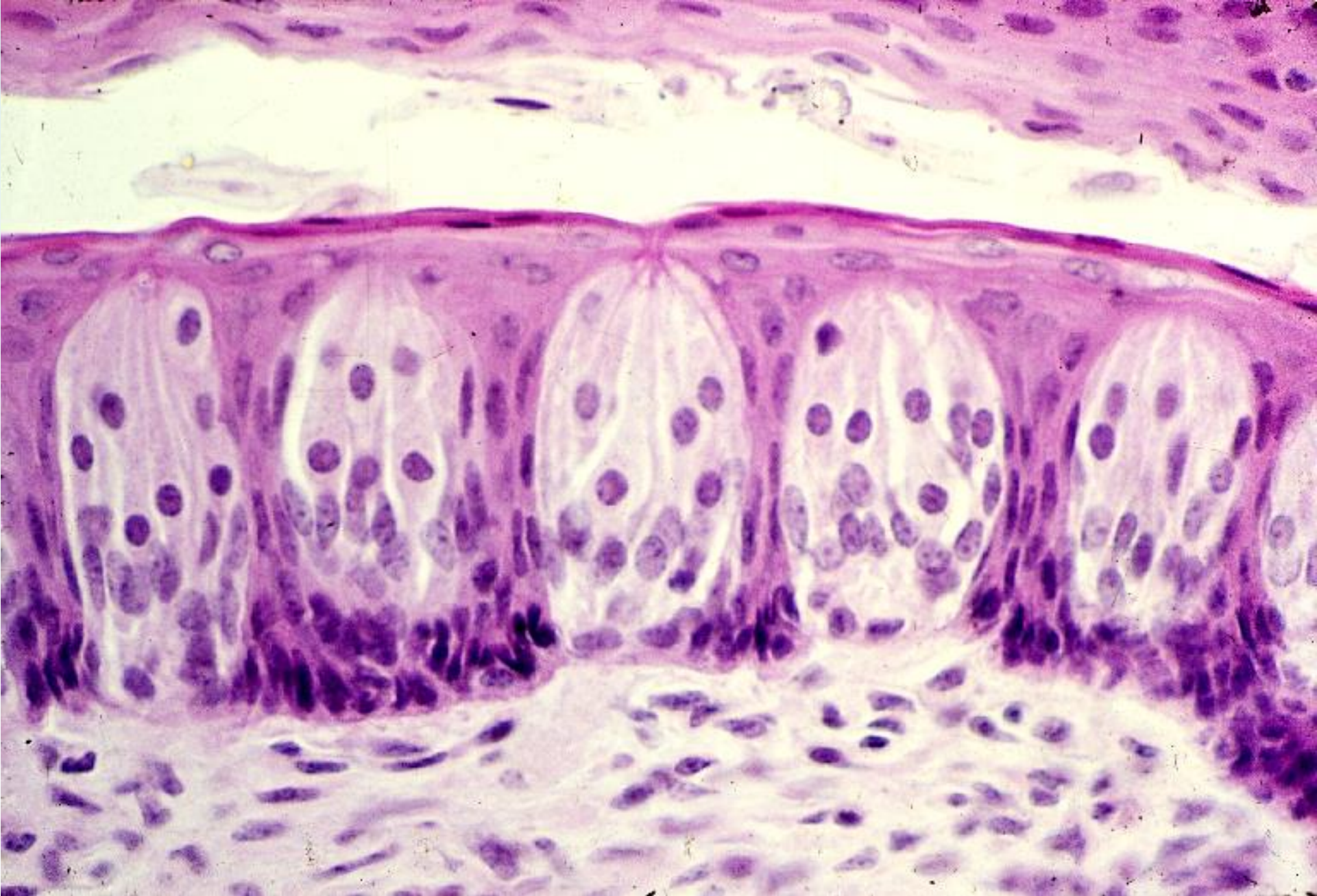
09-09 Papillae foliatae. Human, H-E stain, x 3.0.





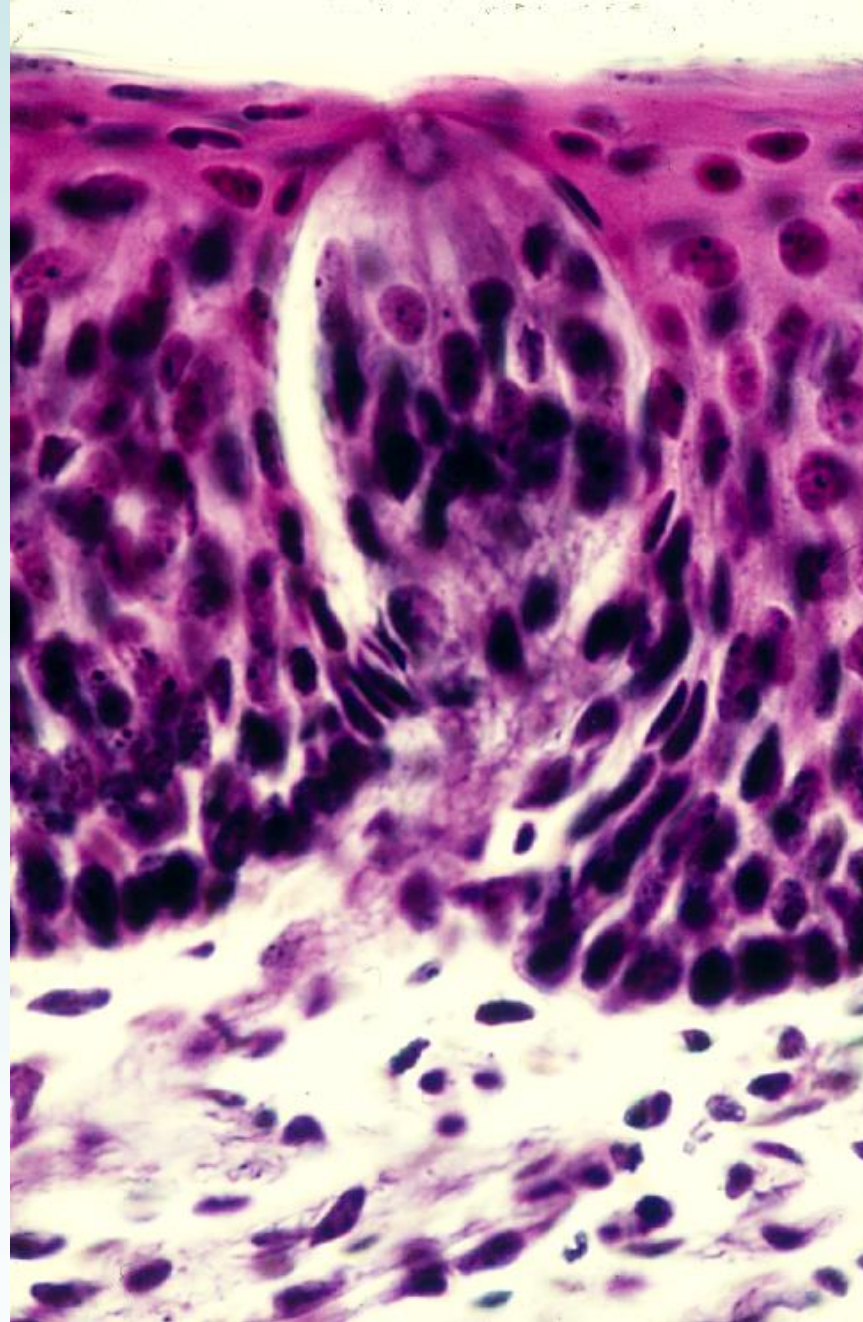
09-10 Taste buds, 1. Monkey, H-E stain, x 64.





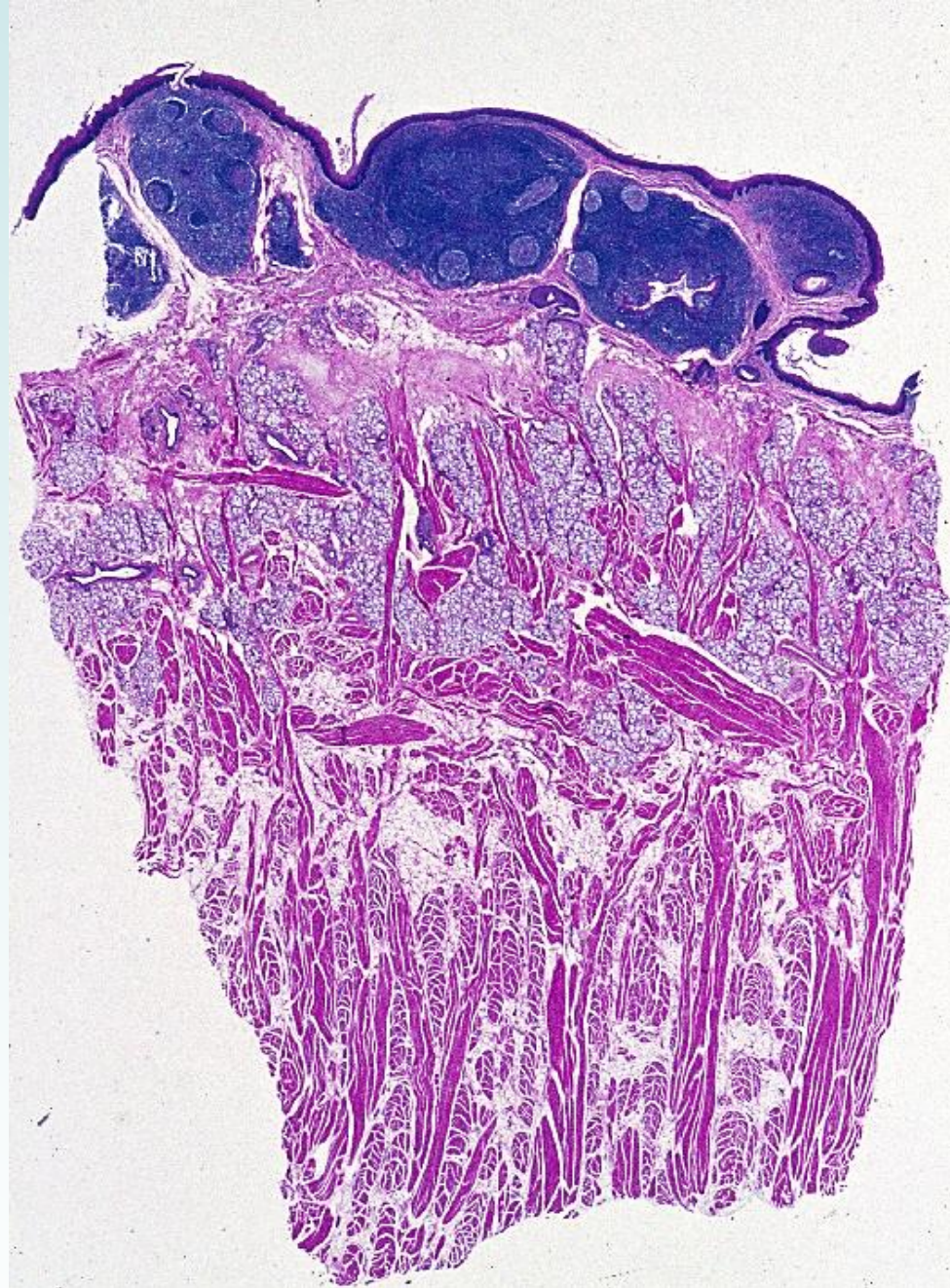09-11 Taste buds, 2. Monkey, H-E stain, x 160.





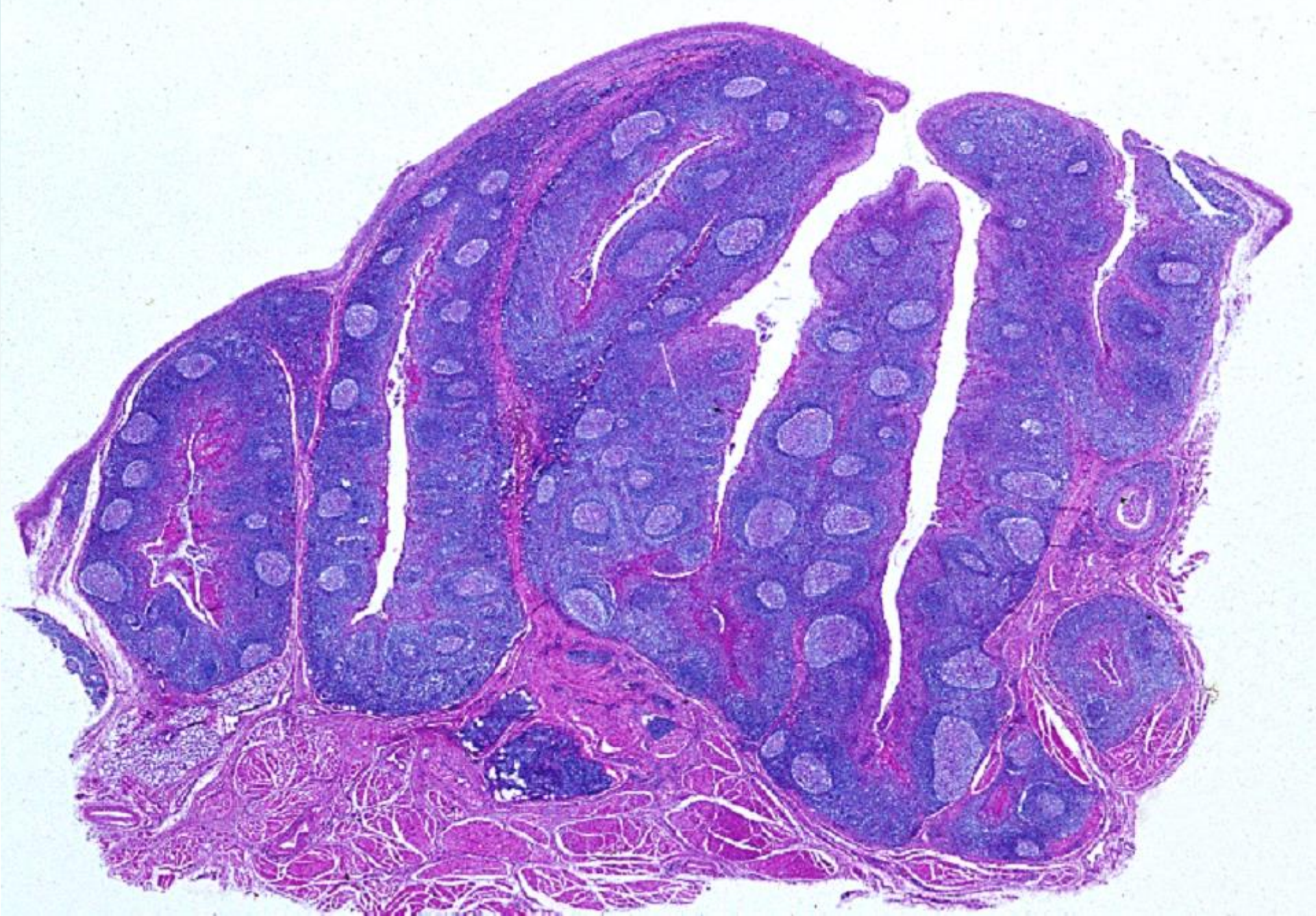
09-12 Taste bud. Human, Suzuki's silver impregnation, x 200.





09-13 Radix linguae, tonsilla lingualis. Human, H-E stain, x 2.0.





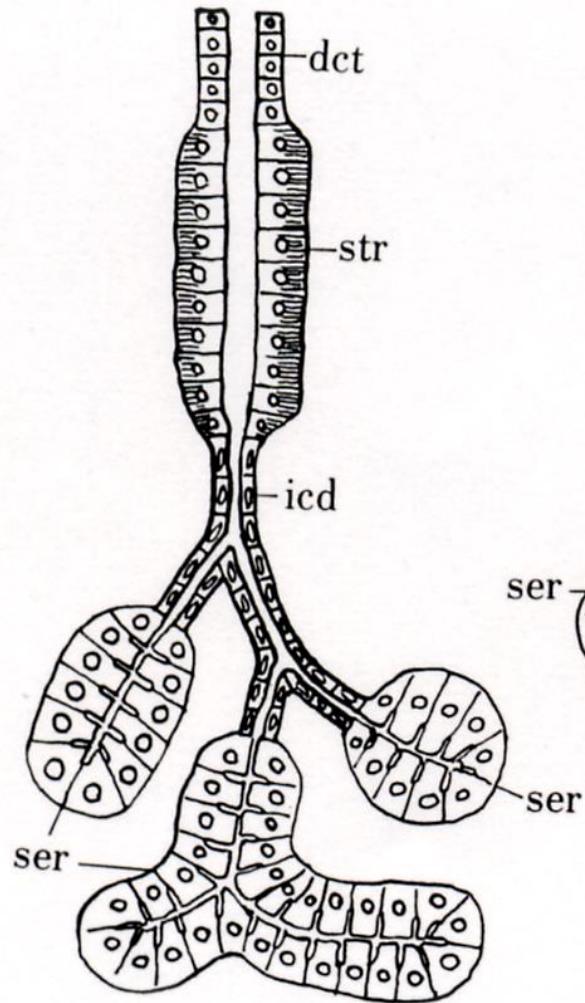
09-14 Tonsilla palatine. Human, H-E stain, x 2.0.

# 09-002

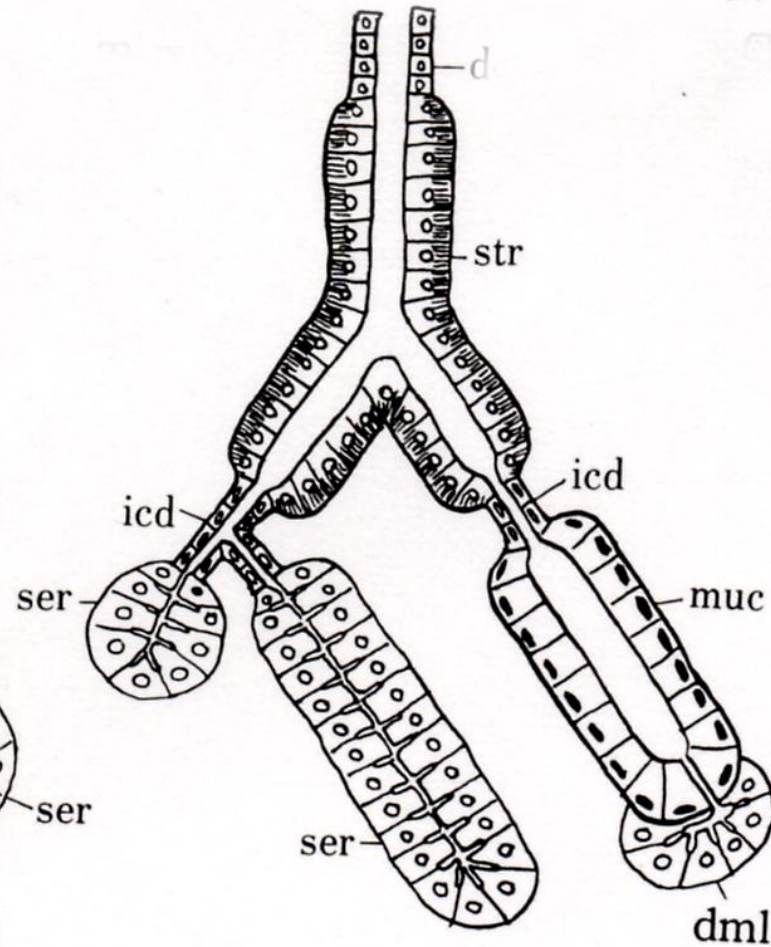
# Salivary Glands



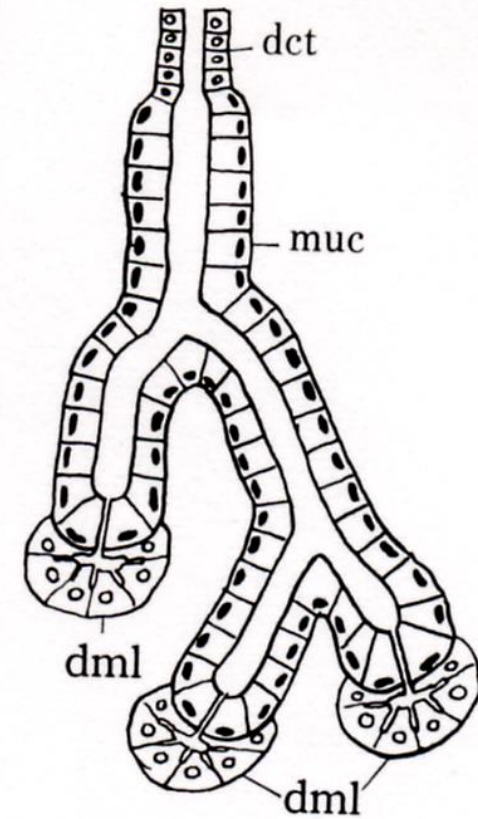
Gl. parotis



Gl. submandibularis



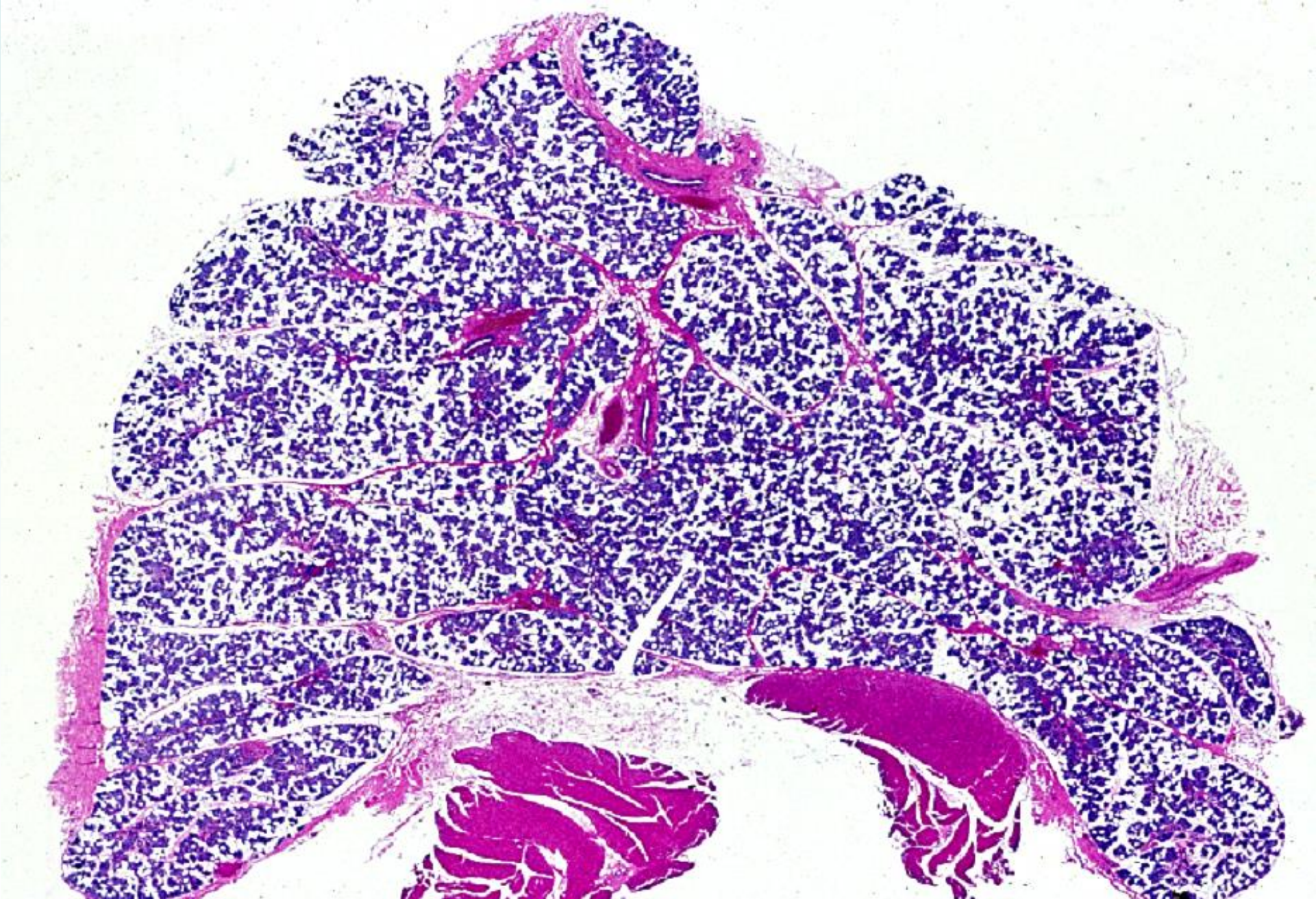
Gl. sublingualis



# 09-0021

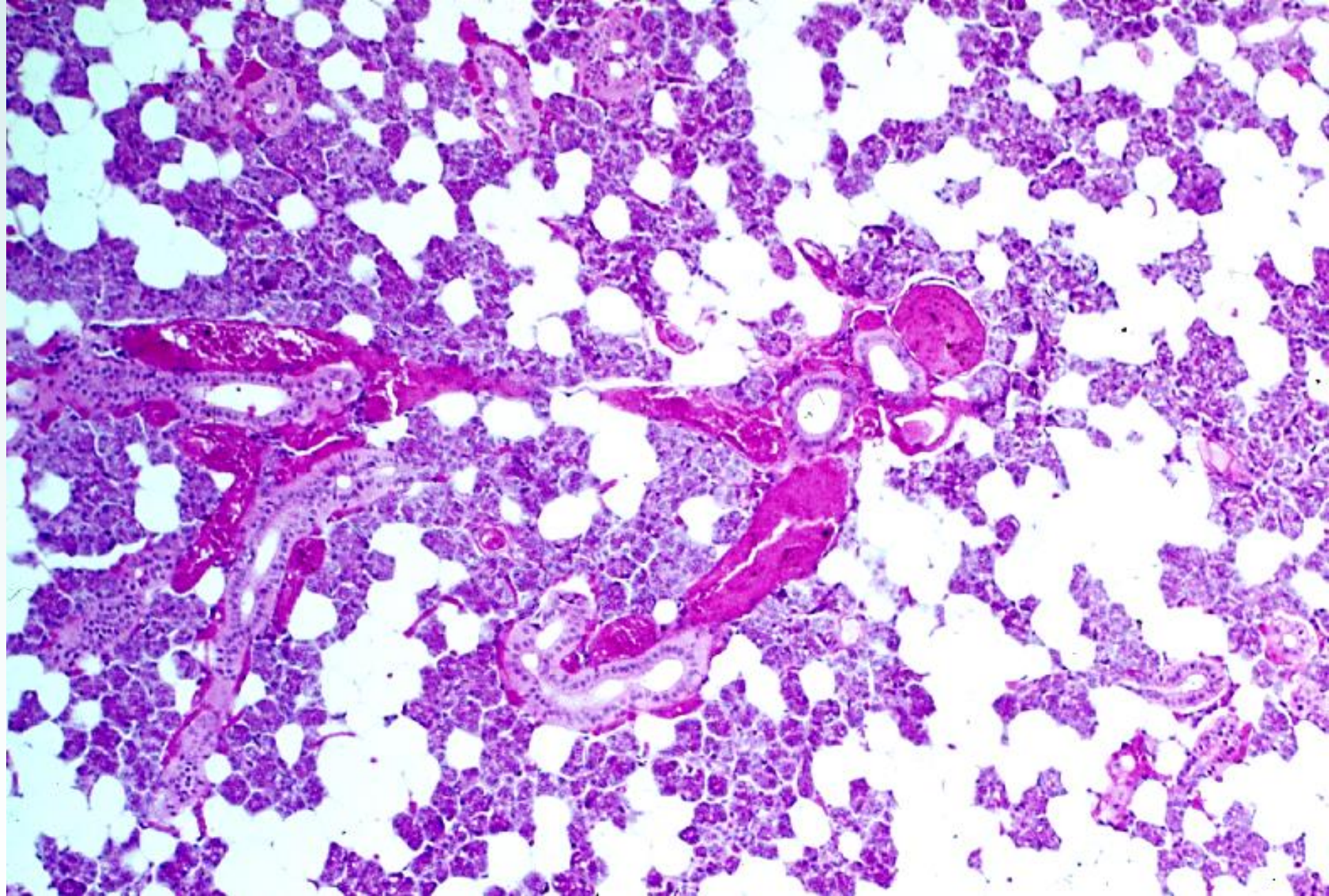
## Gl. parotis





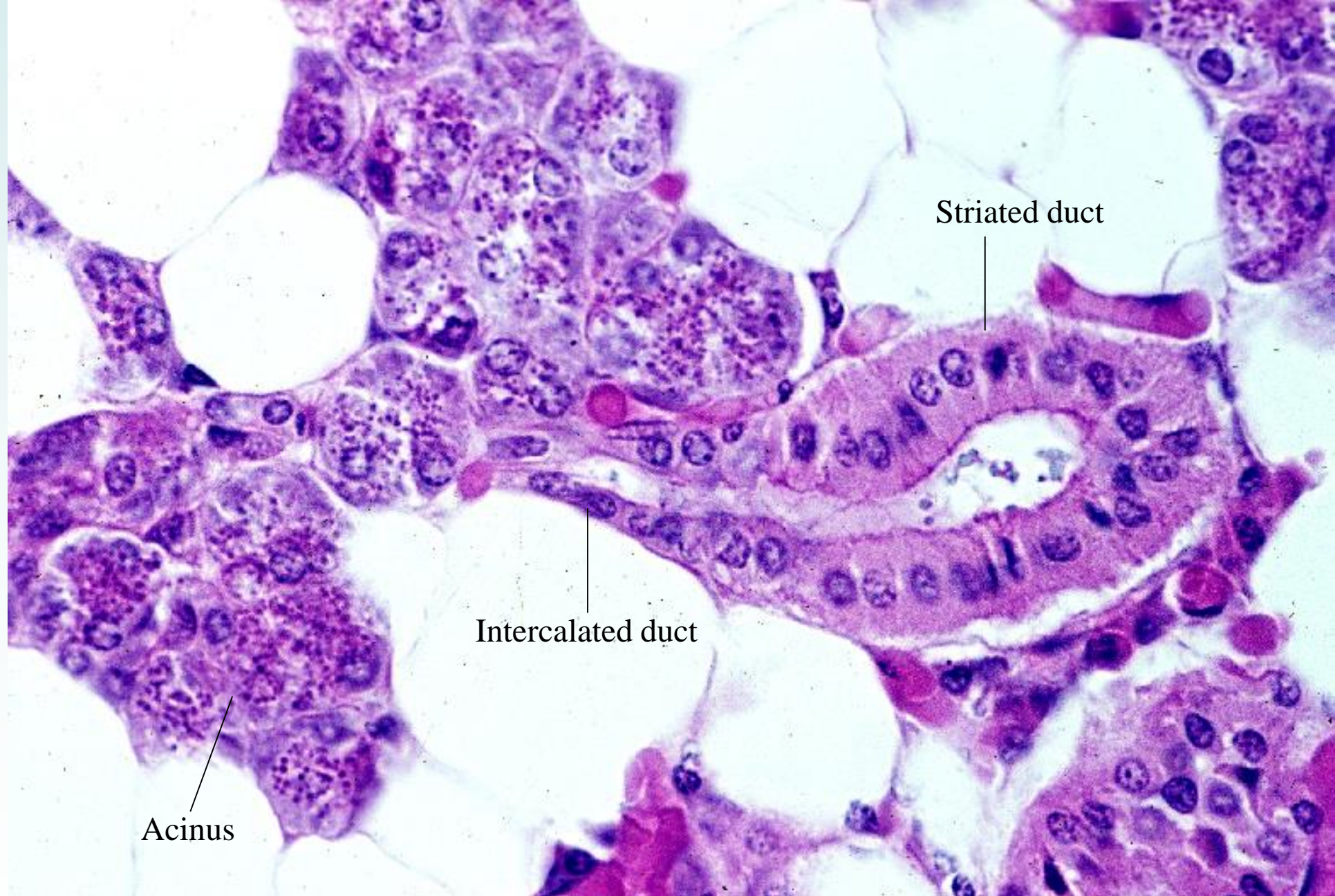
09-16 Gl. parotis, 1. General view. Human, H-E stain, x 2.2.





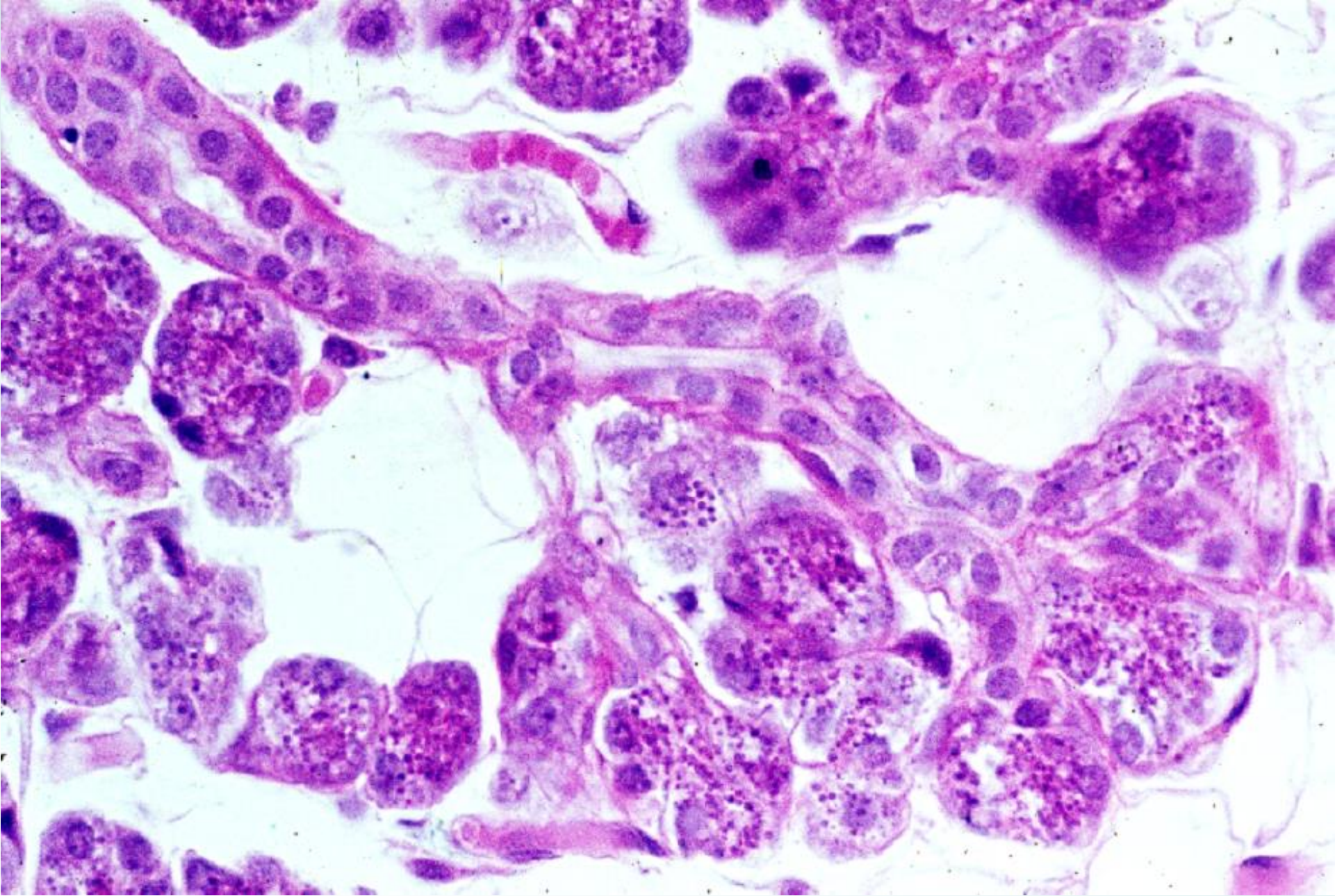
09-17 Gl. parotis, 2. Low power magnification. Human, H-E stain, x 25.





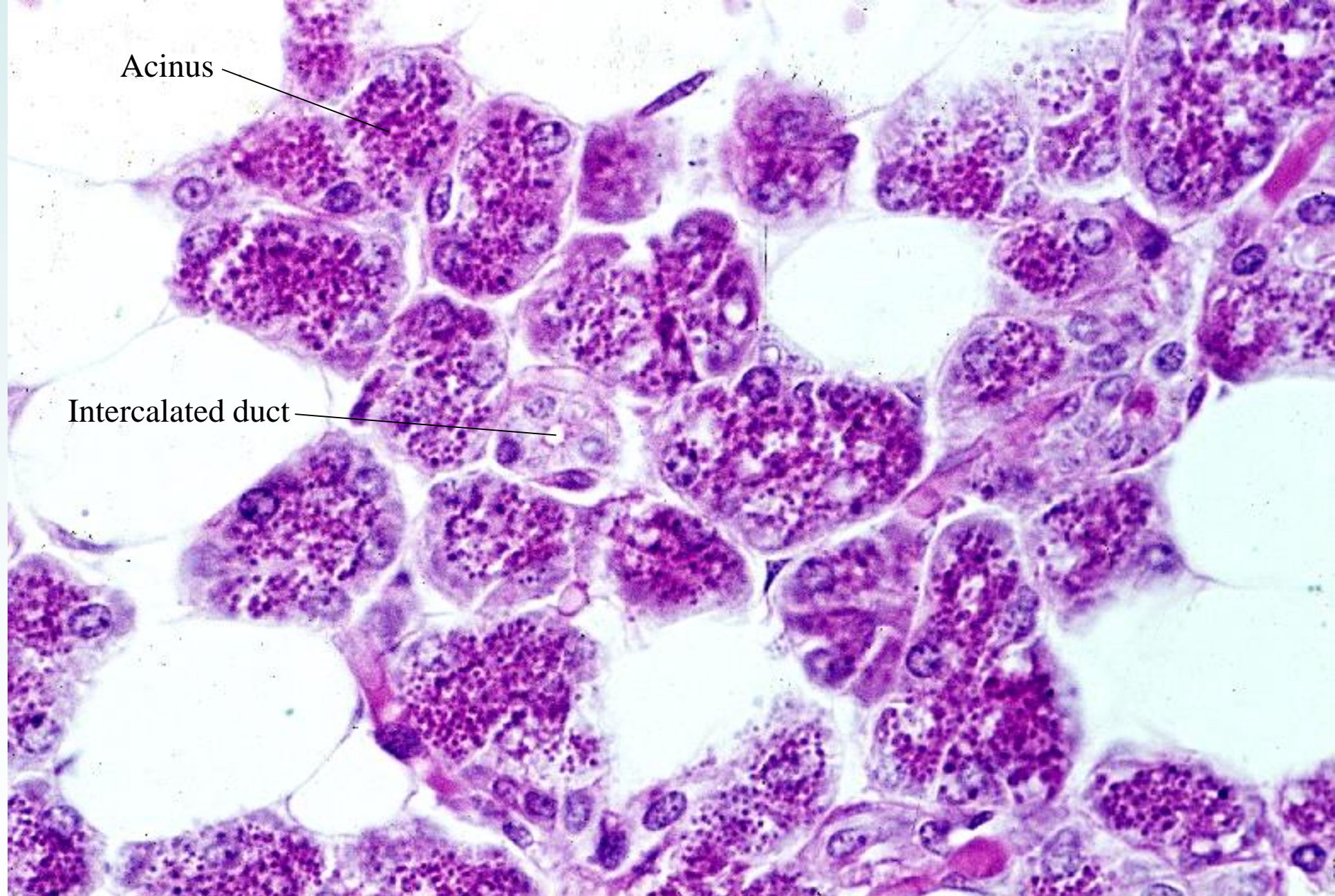
09-18 Gl. Parotis, 3. Intercalated duct and striated duct. Human, H-E stain, x 160.





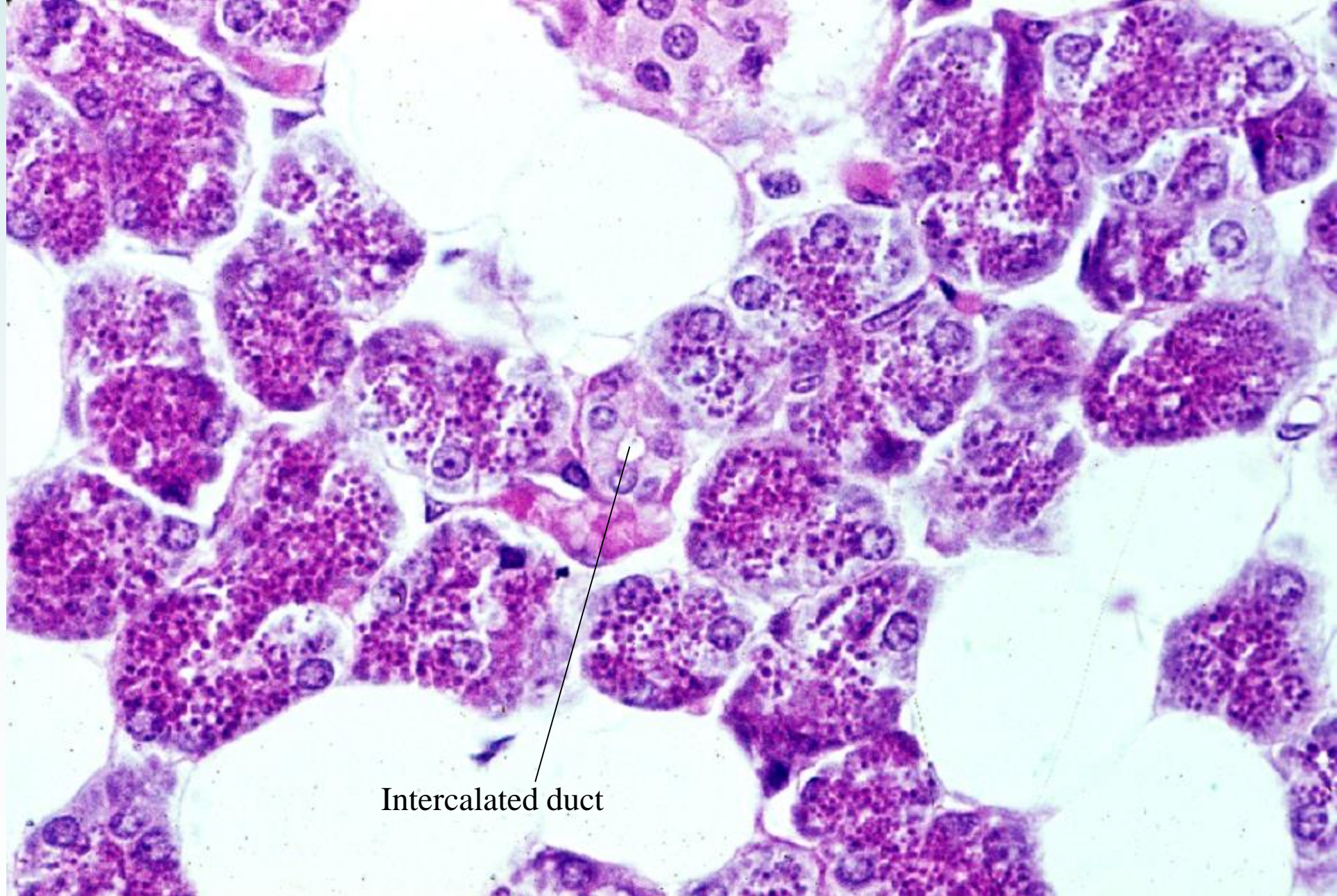
09-19 Gl. parotis, 4. Intercalated duct. Human, H-E stain, x 160.





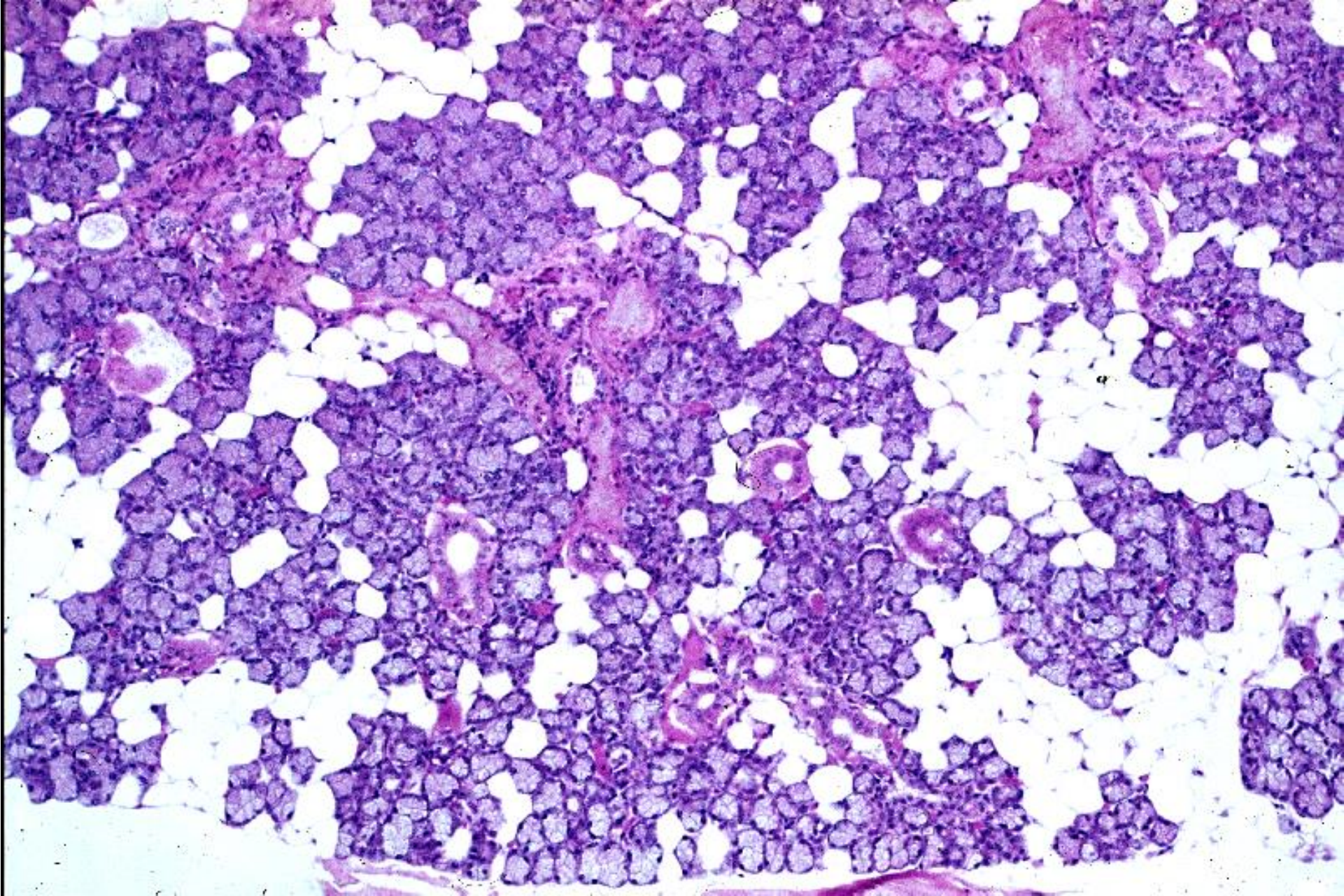
09-20 Gl. parotis, 5. Intercalated duct, transverse section. Human, H-E stain, x 160.





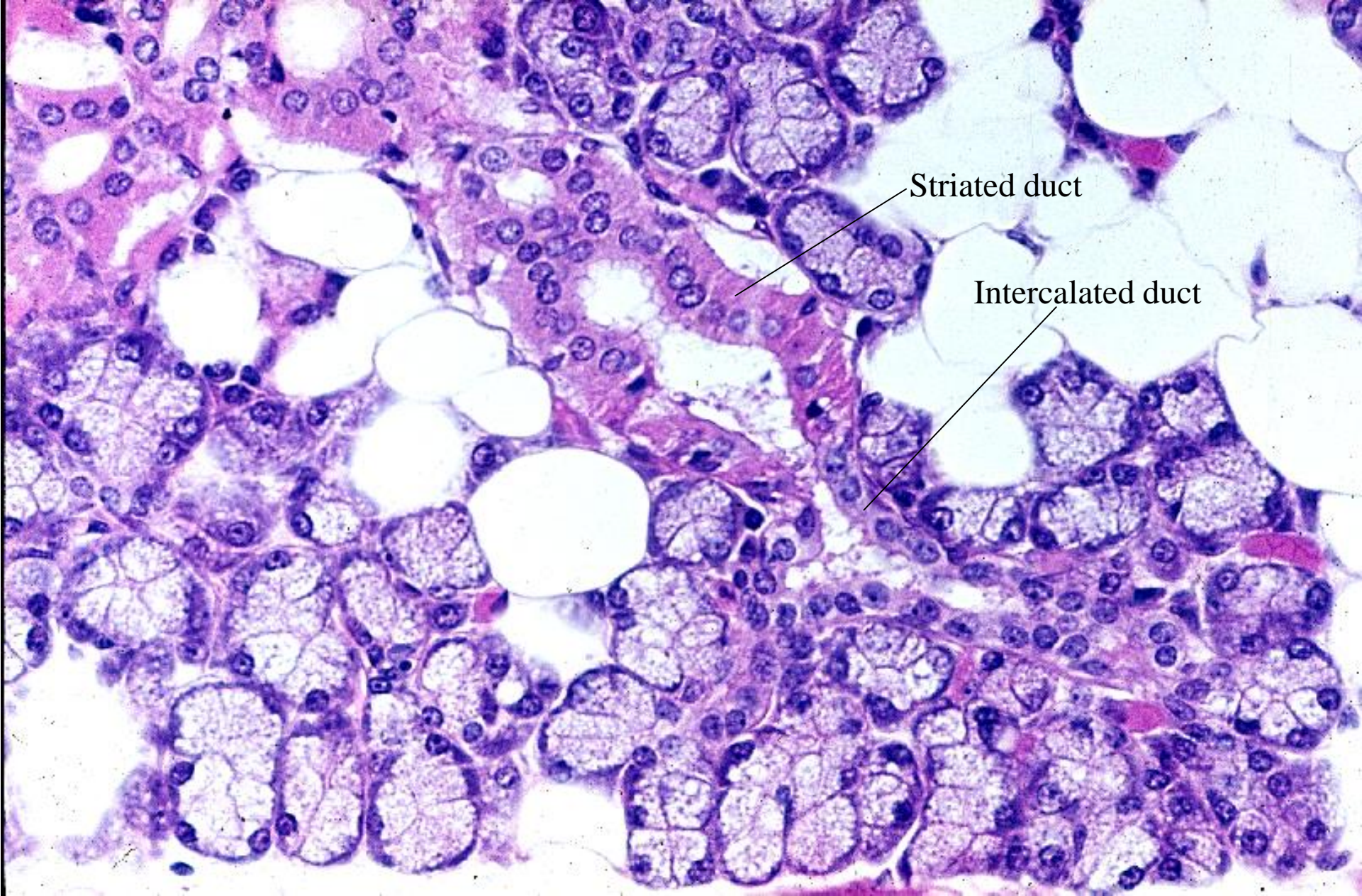
Intercalated duct





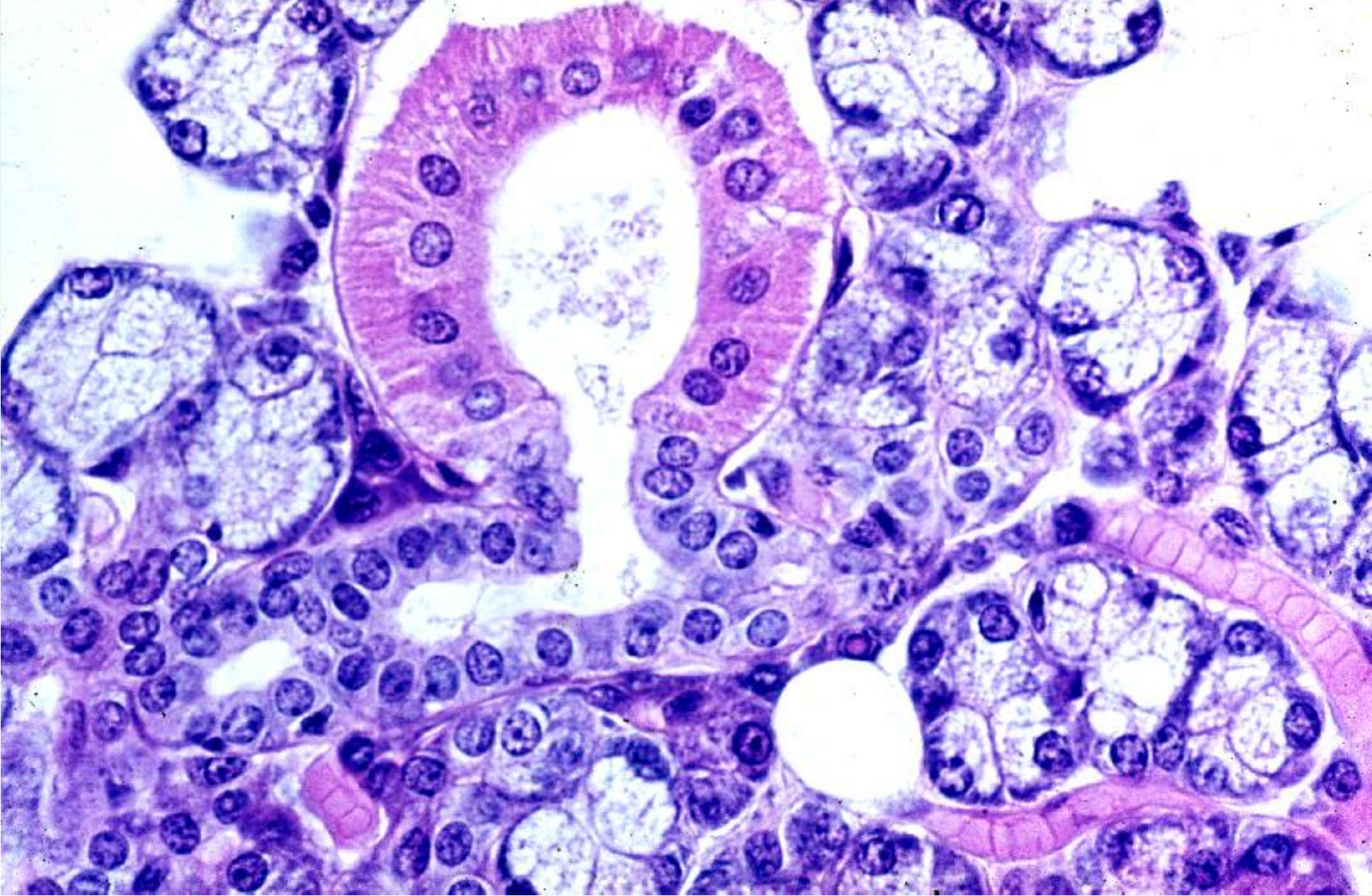
09-22 Gl. parotis, 7. General view of another parotid gland. Human, H-E stain, x 25.





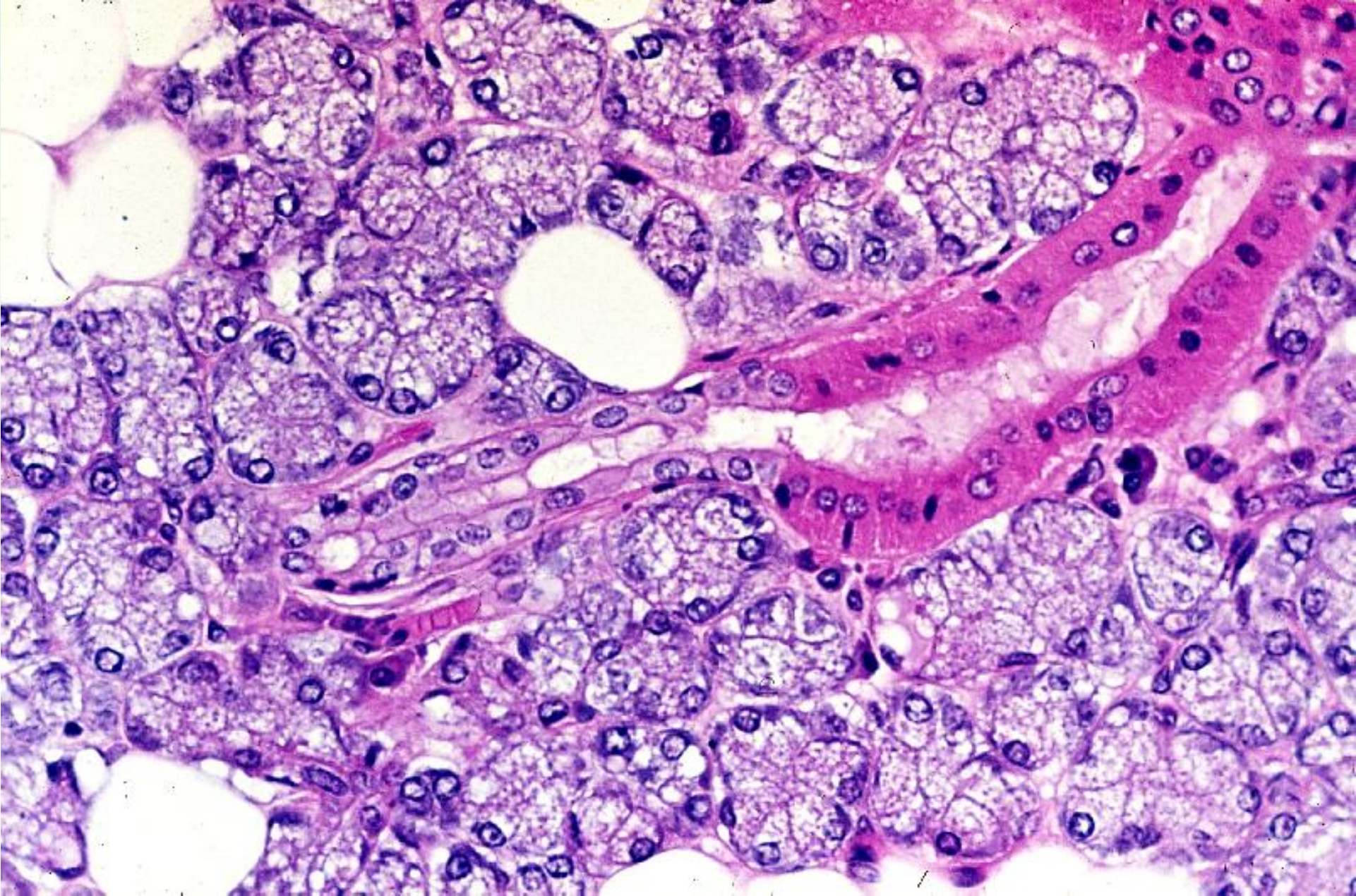
09-23 Gl. parotis, 8. Striated and intercalated duct. Human, H-E stain, x 100.





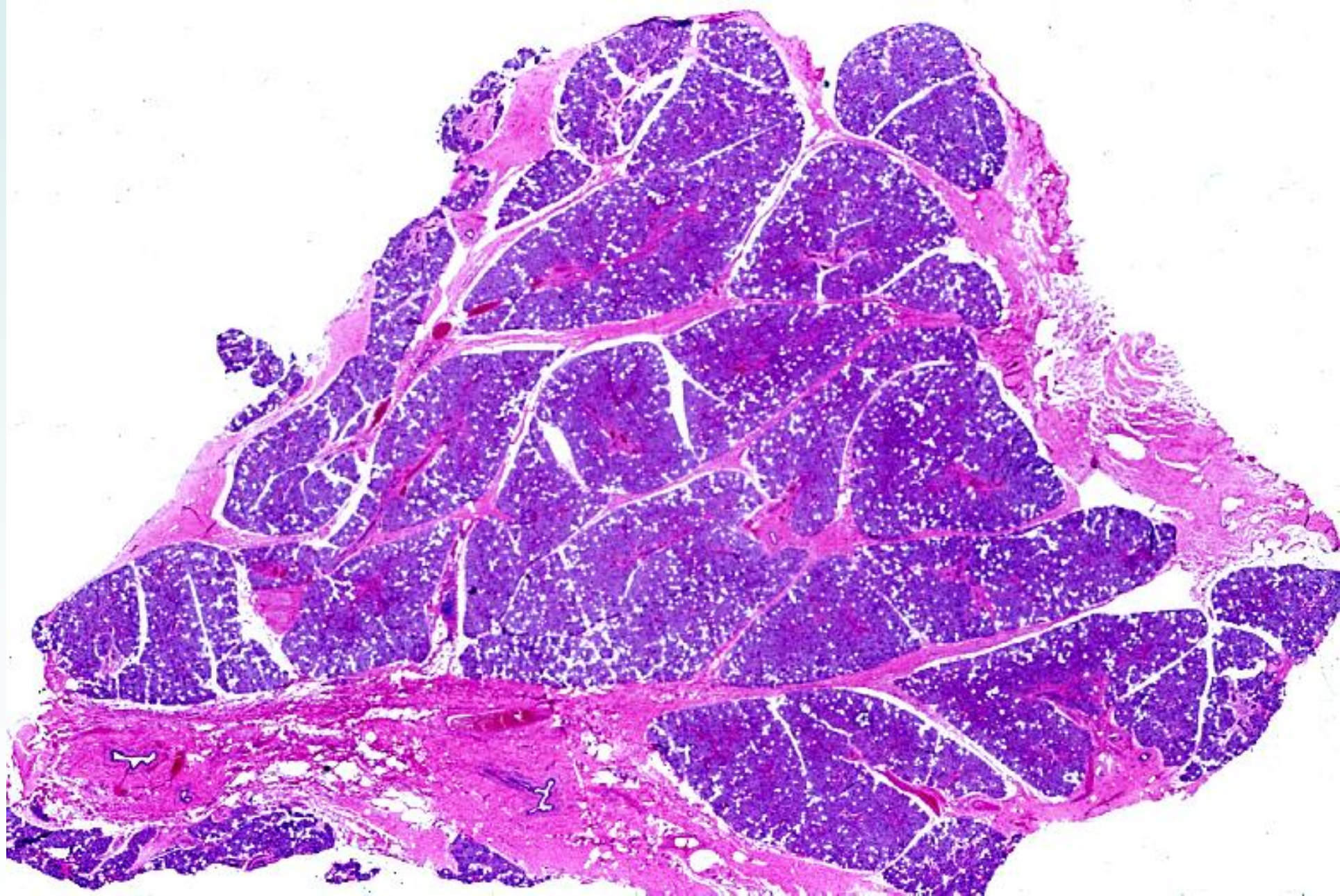
09-24 Gl. parotis, 9. Striated duct and intercalated duct. Human, H-E stain, x 160.





09-25 Gl. parotis, 10. Striated duct and intercalated duct. Human, H-E stain, x 100.





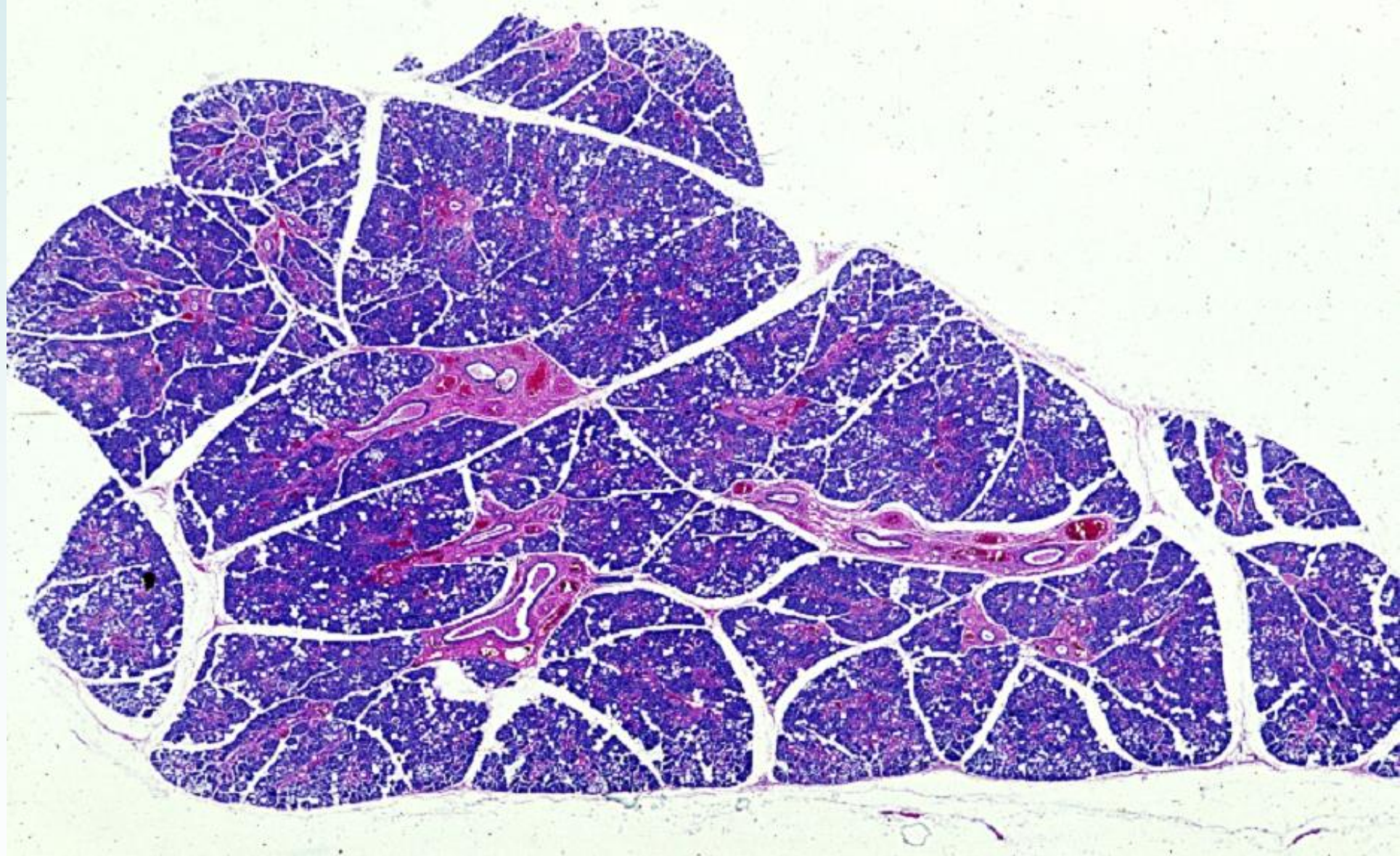
09-26 Gl. parotis containing less fat cells. Human, H-E stain, x 2.2.



09-0022

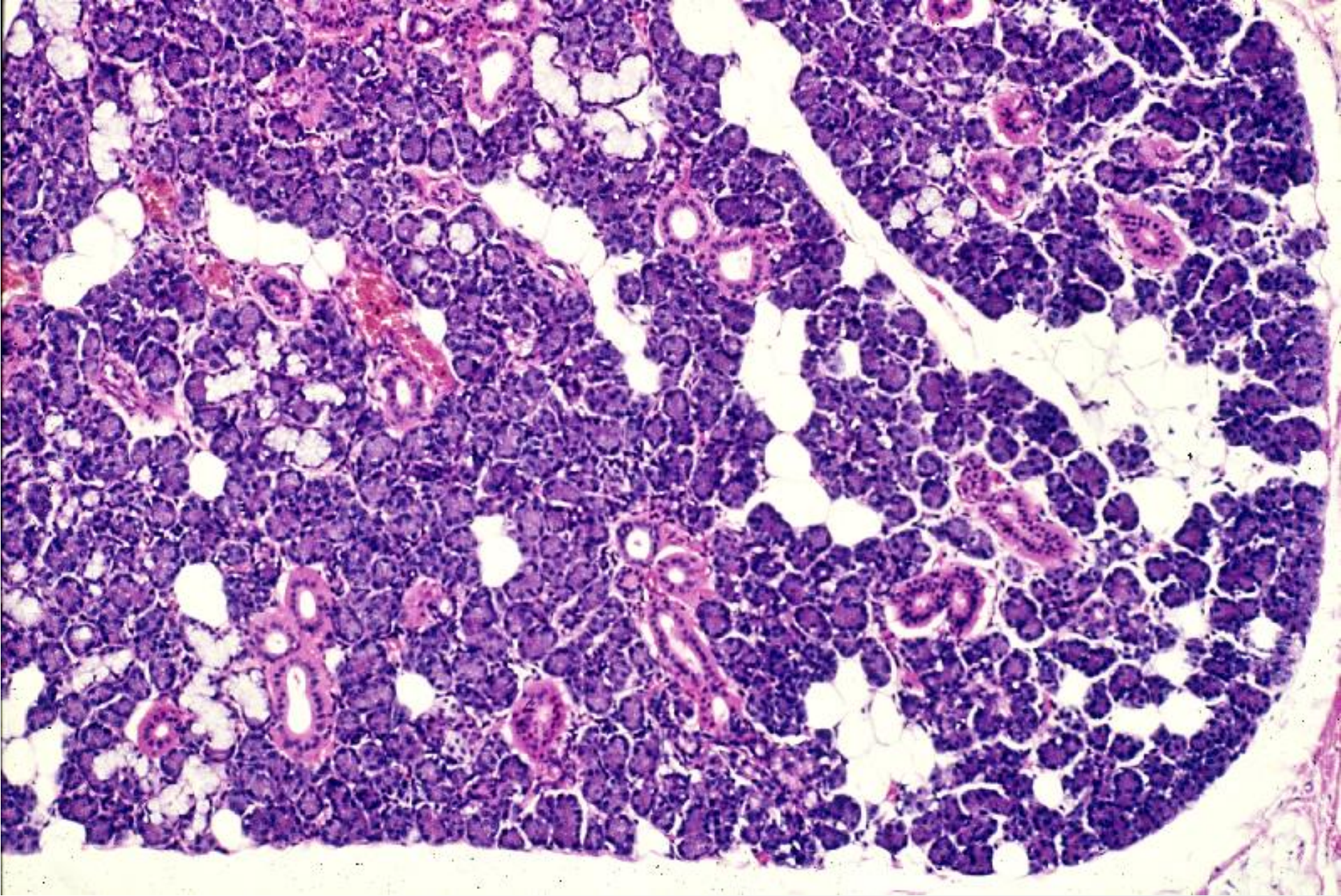
Gl. submandibularis





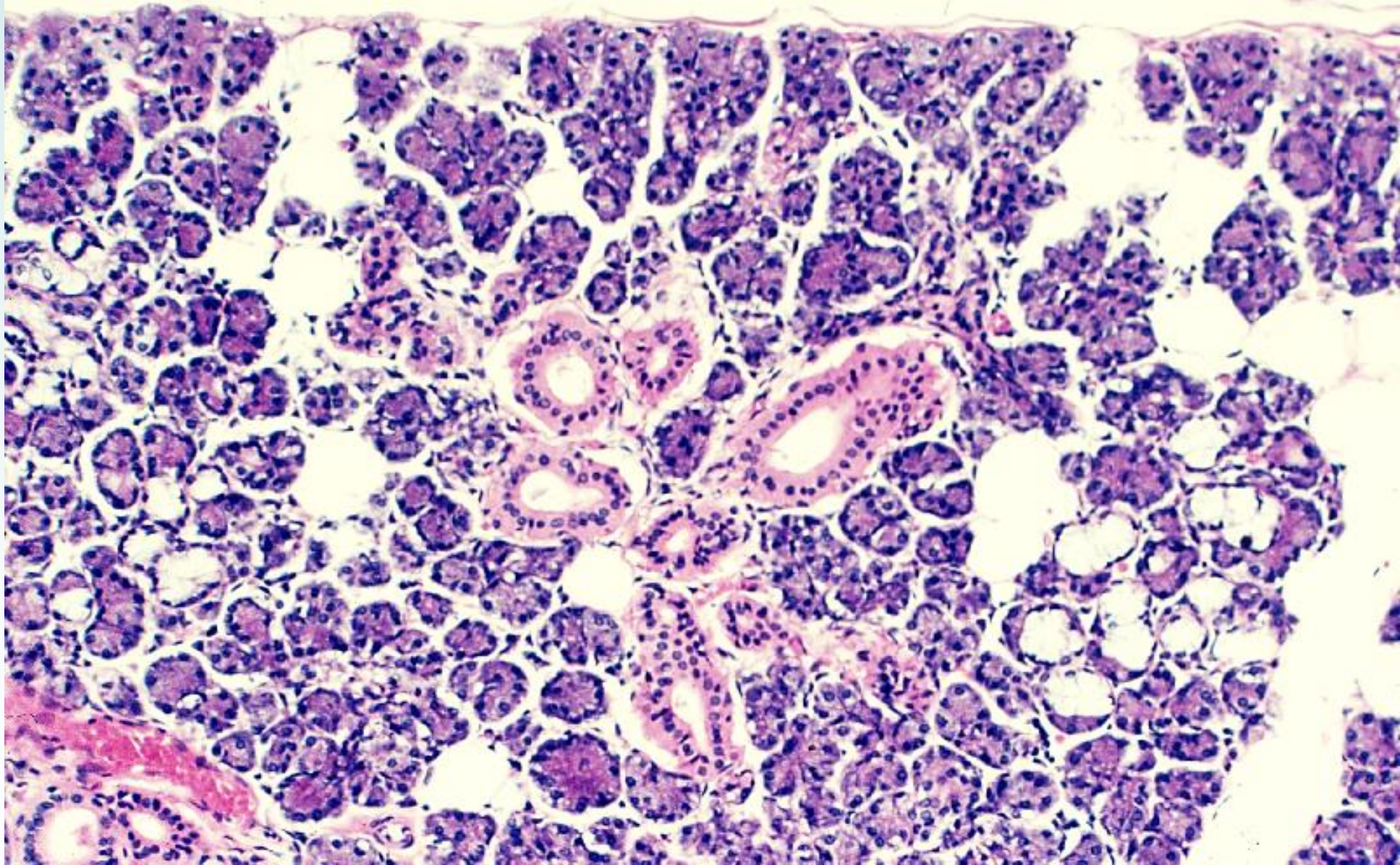
09-27 Gl. submandibularis, 1. Human, H-E stain, x 2.5.





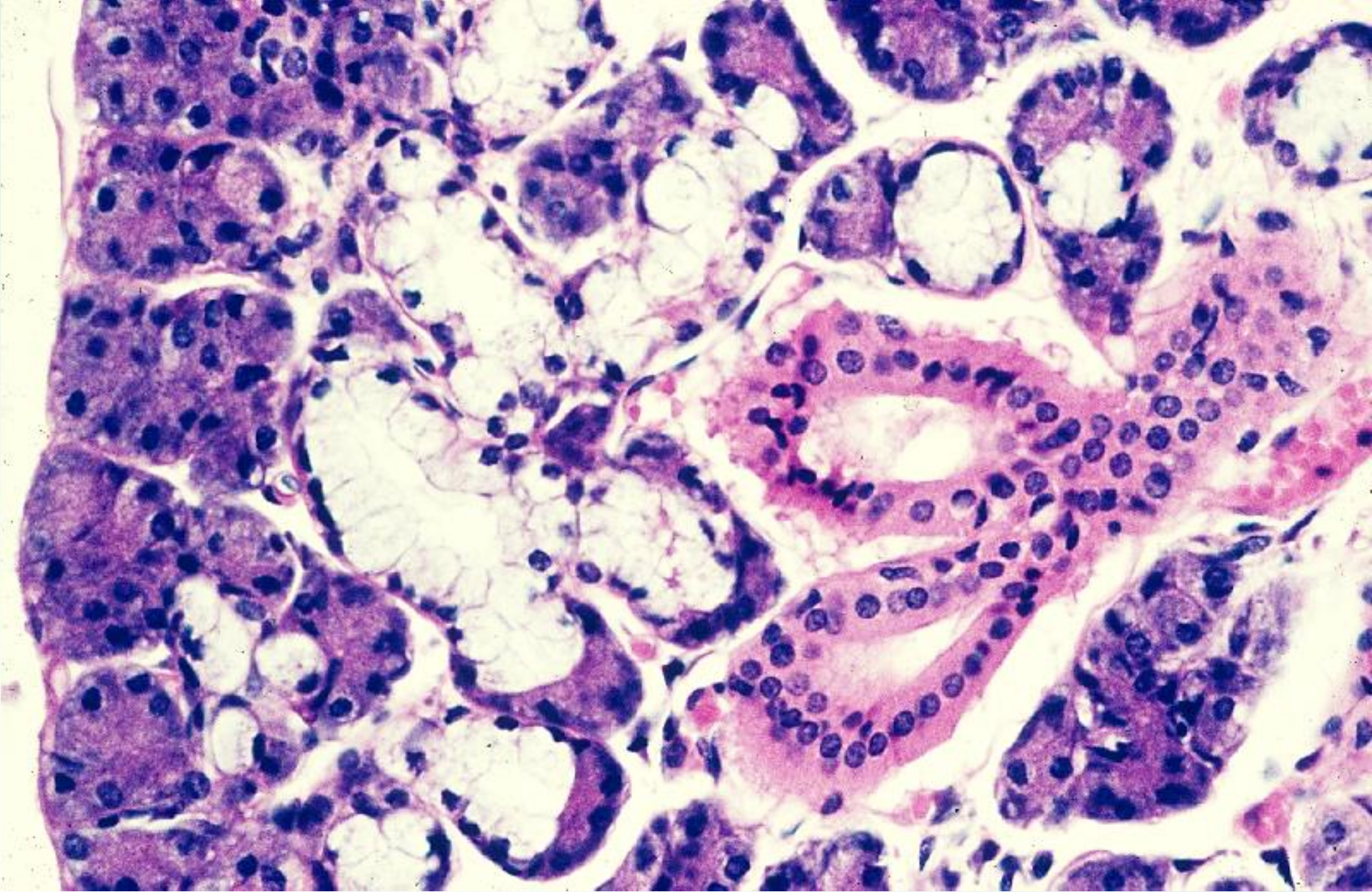
09-28 Gl. submandibularis, 2. Human, H-E stain, x 40.





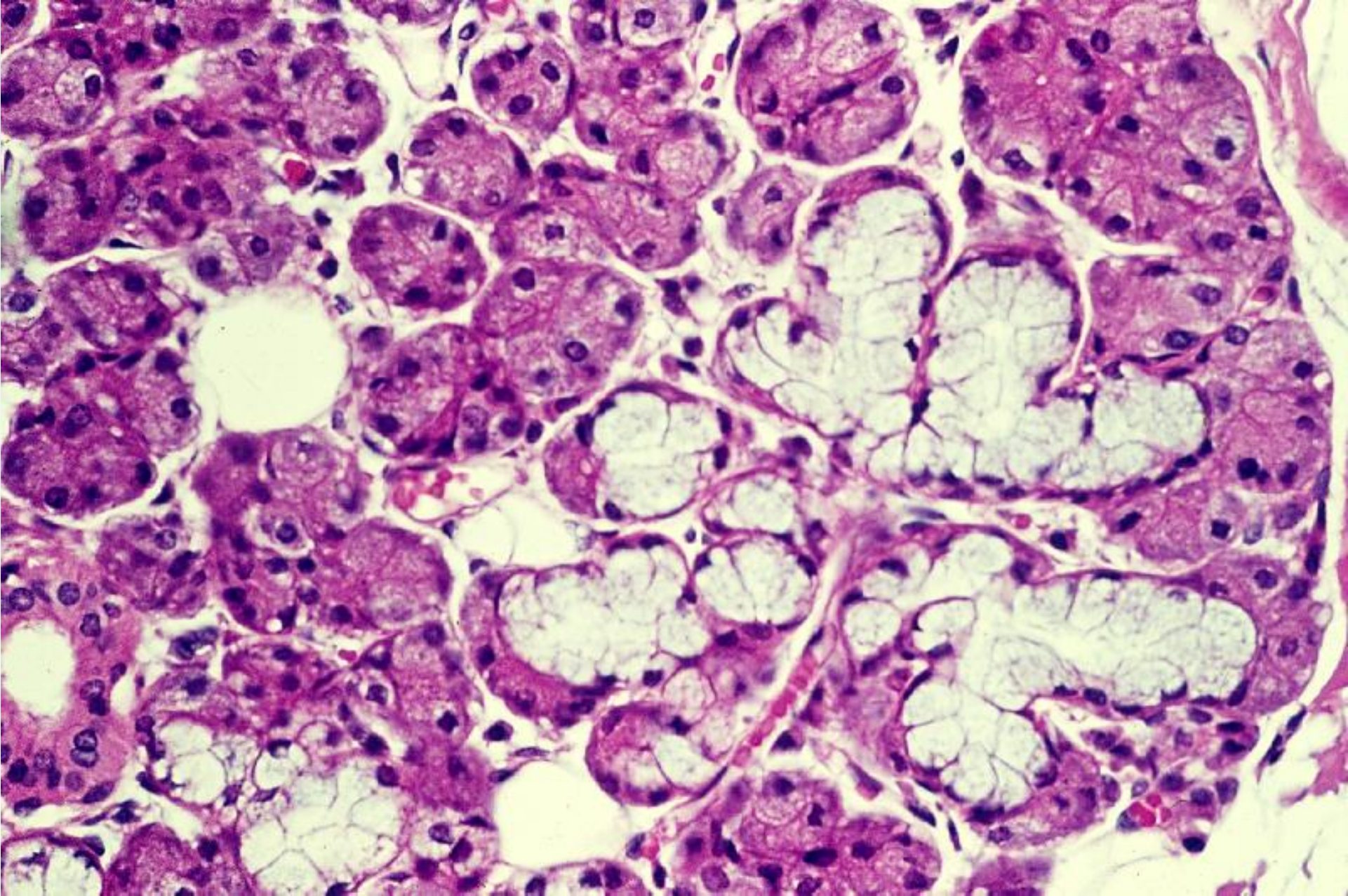
09-29 Gl. submandibularis, 3. Human, H-E stain, x 40.





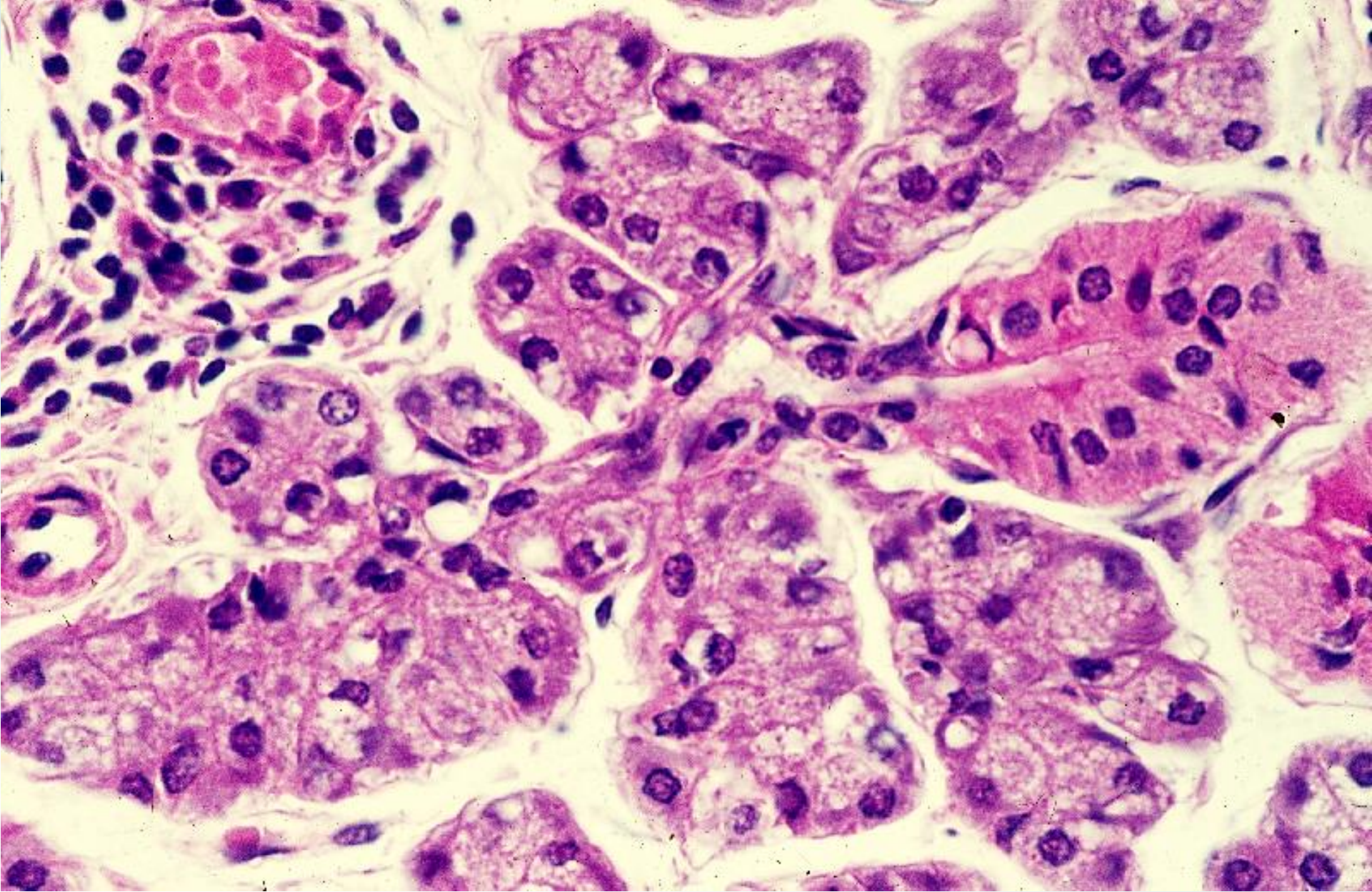
09-30 Gl. submandibularis, 4. Human, H-E stain, x 100.





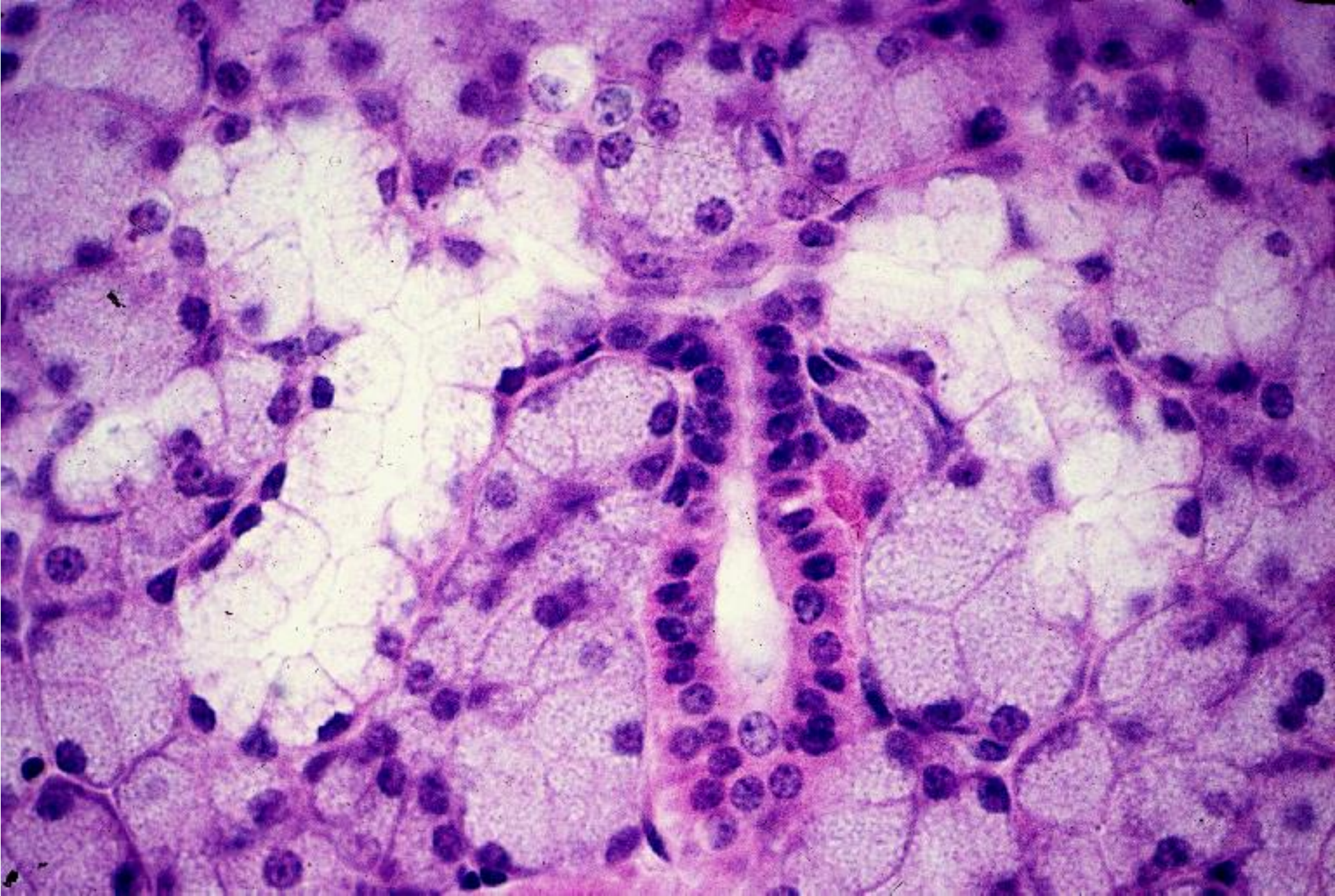09-31 Gl. submandibularis, 5. Human, H-E stain, x 100.





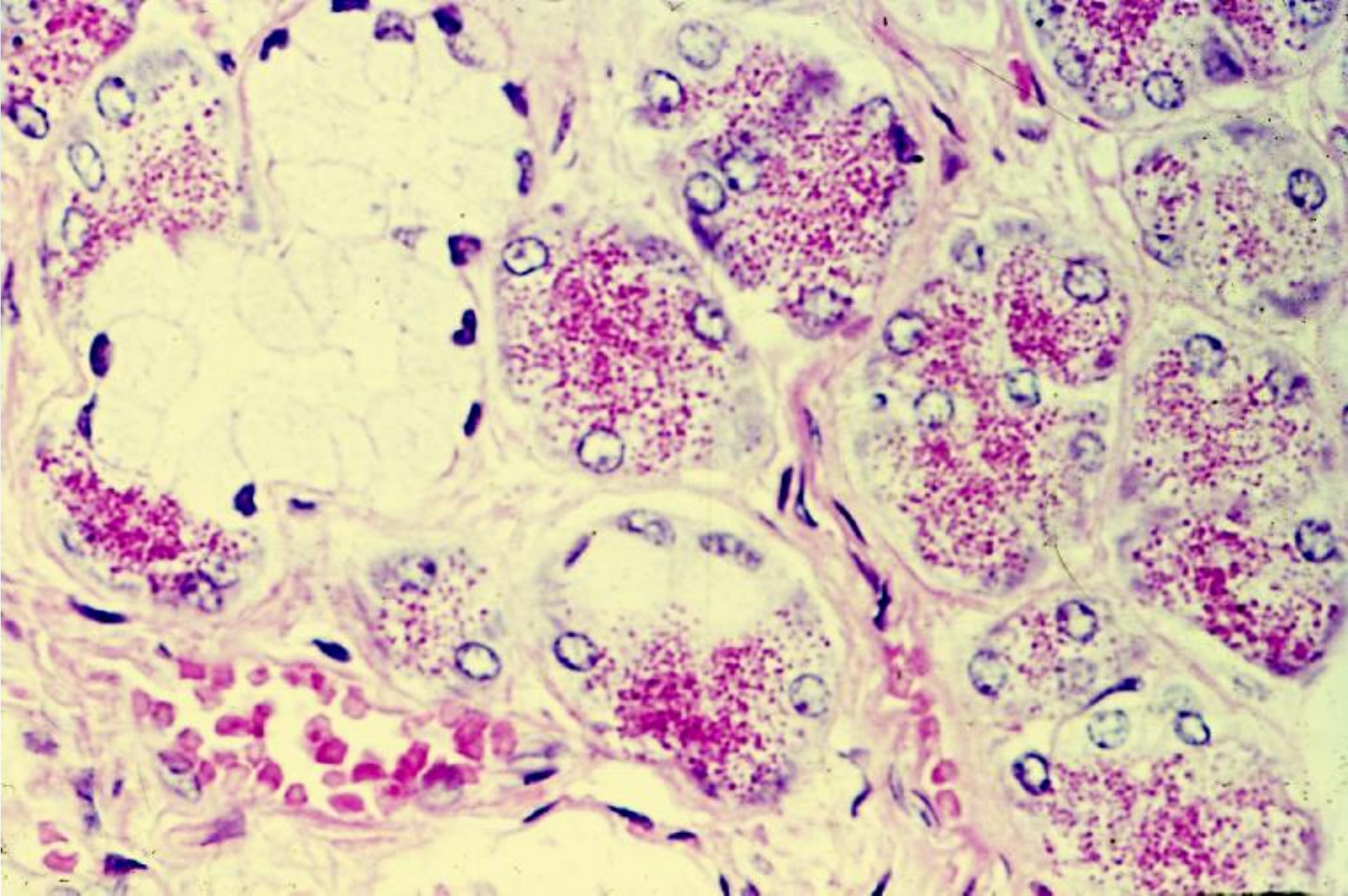
09-32 Gl. submandibularis, 6. Human, H-E stain, x 160.





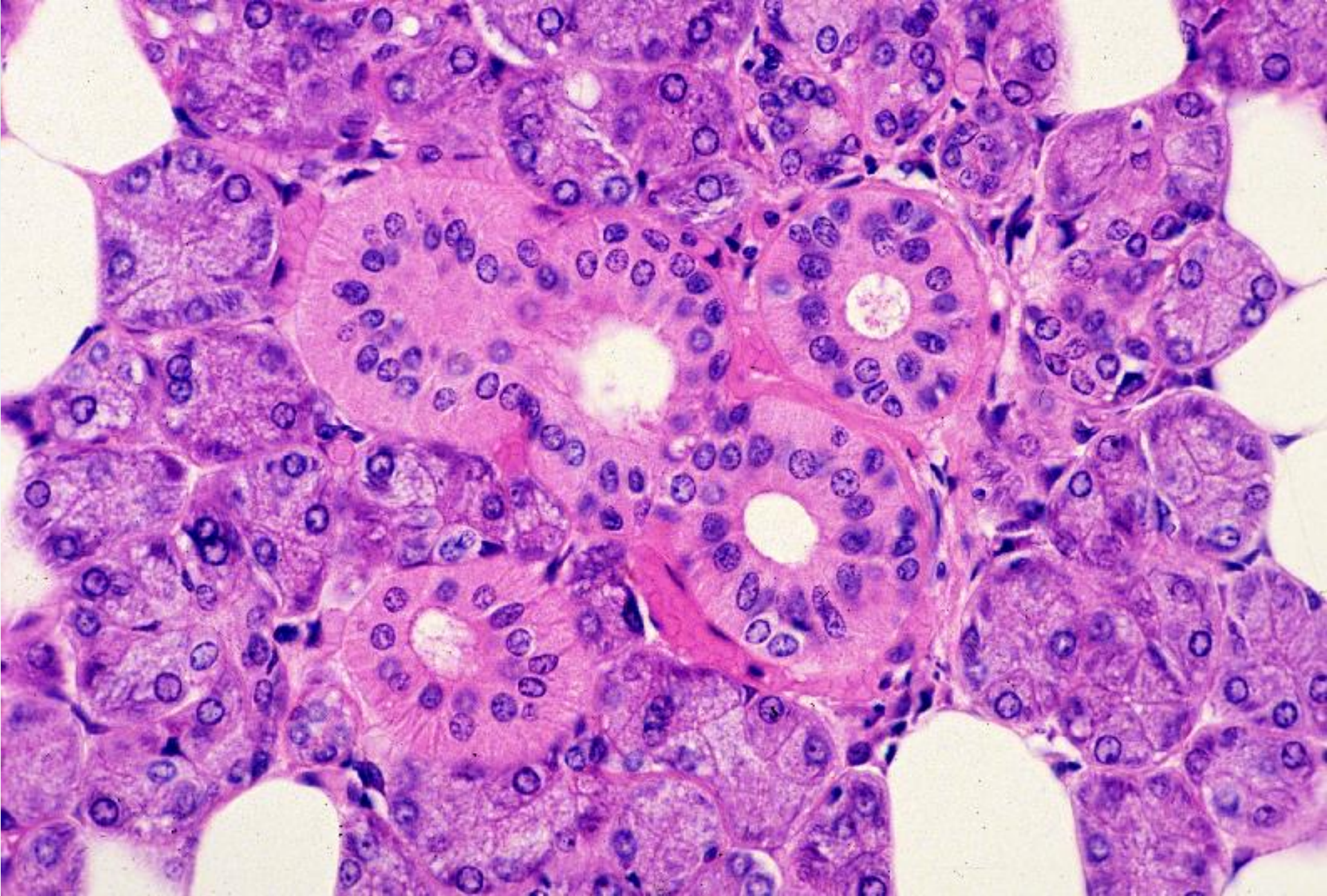
09-33 Gl. submandibularis, 7. Monkey, H-E stain, x 160.





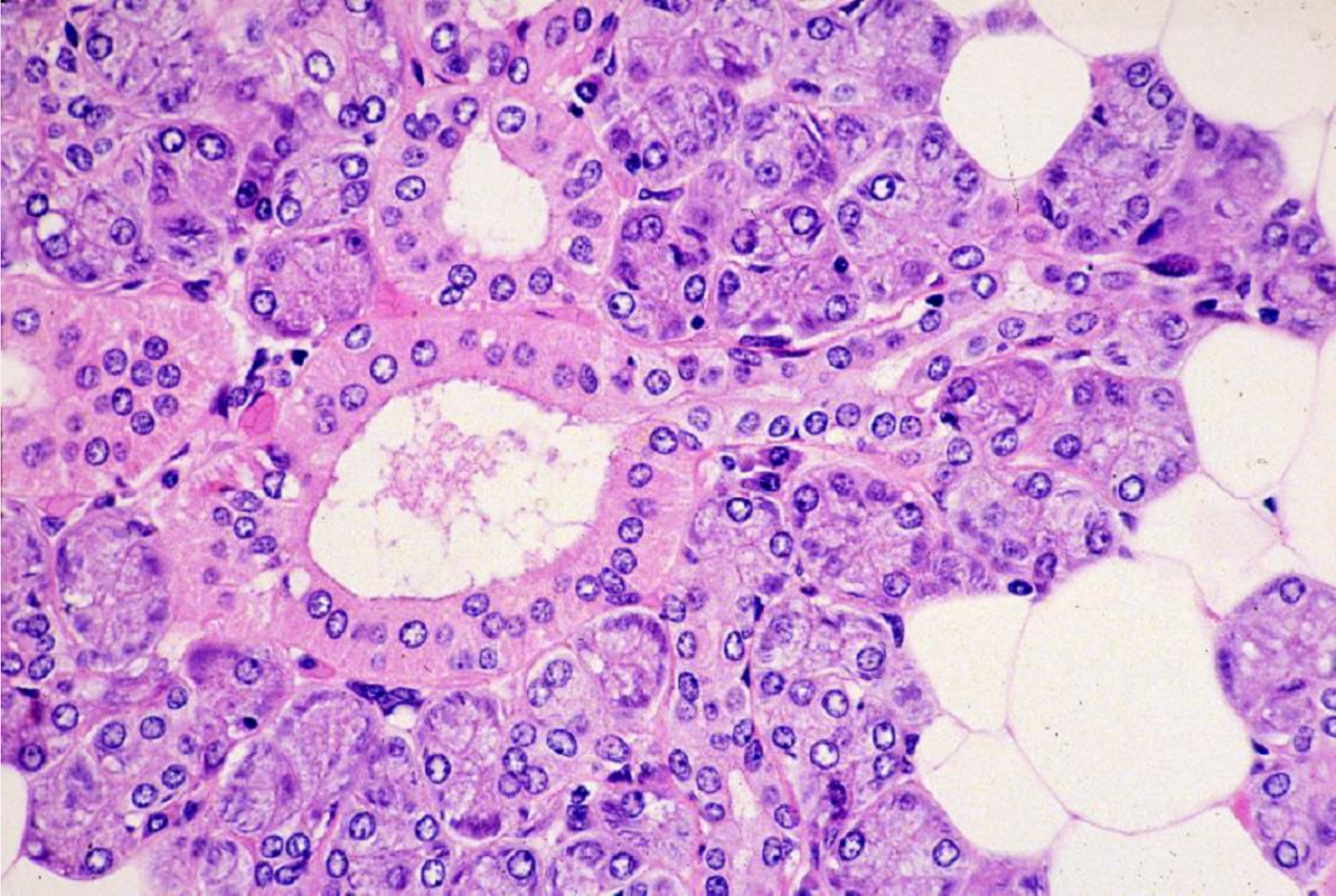
09-34 Gl. submandibularis, 8. Secretion granules. Human, H-E stain, x 160.





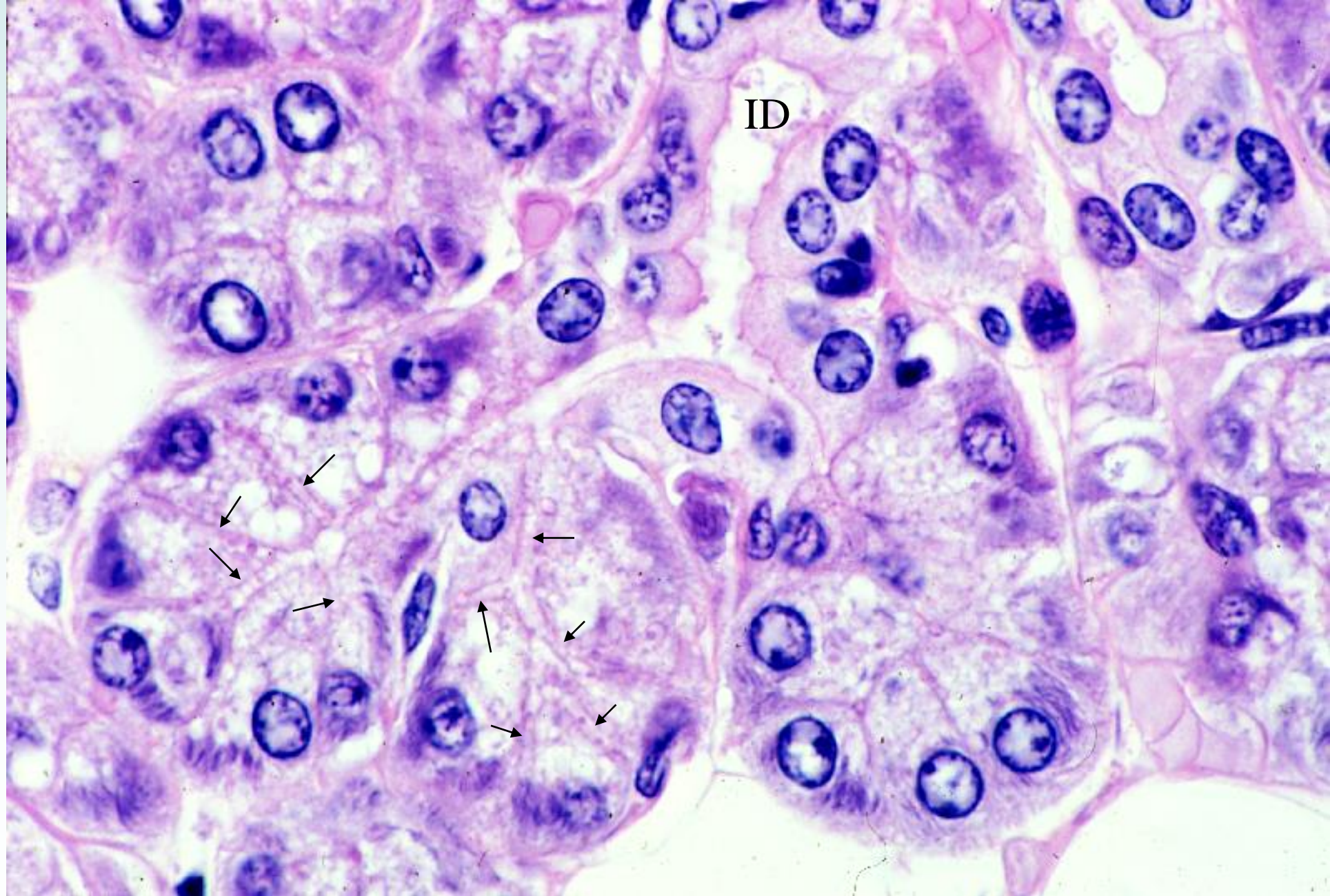
09-35 Gl. submandibularis, 9. Striated ducts. Human, H-E stain, x 160.





09-36 Gl. submandibularis, 10. Human, H-E stain, x 160.





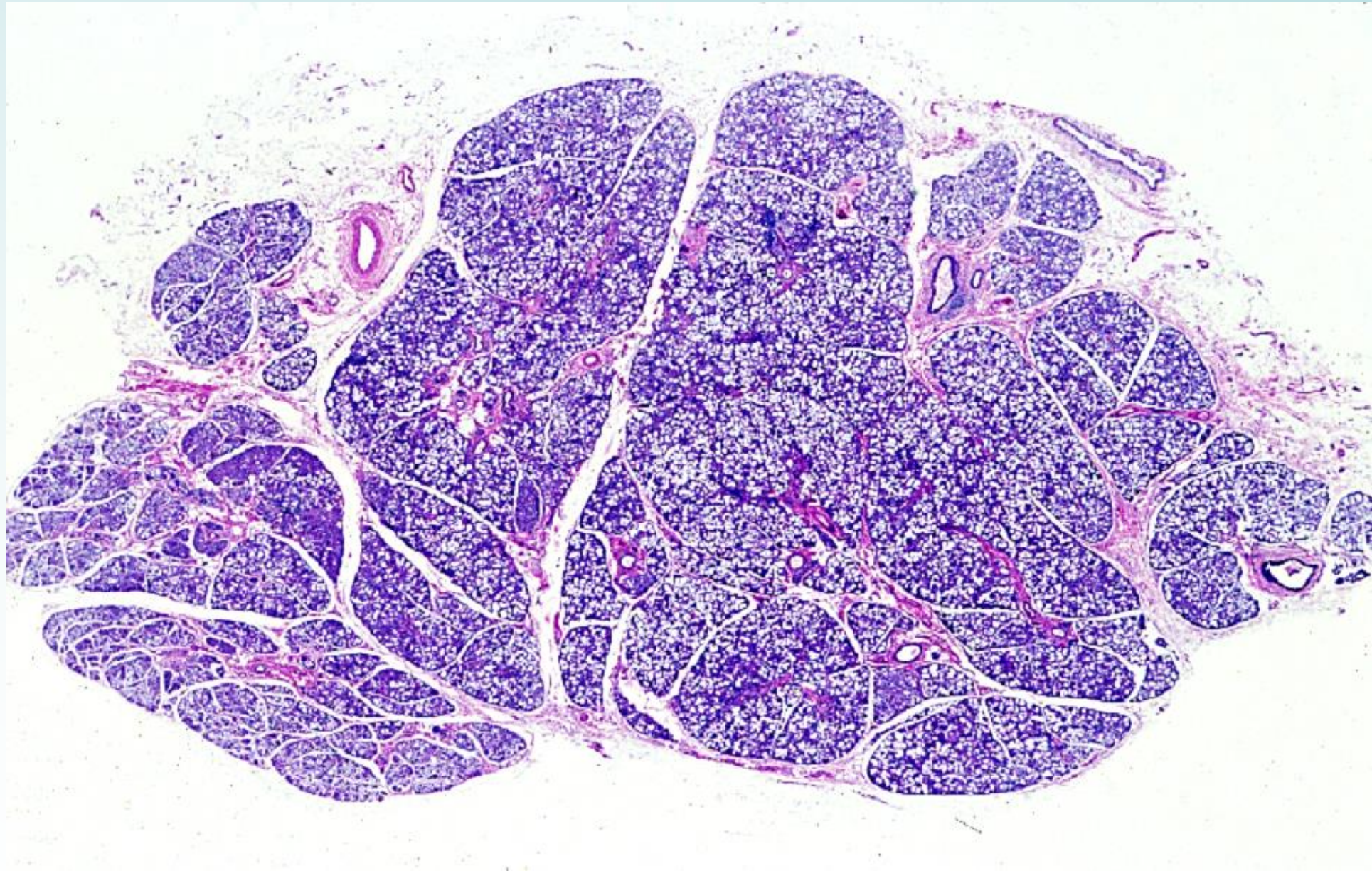
09-37 Gl. submandibularis, 11. Intercellular secretory canaliculi. Human, H-E stain, x 250.



# 09-0023

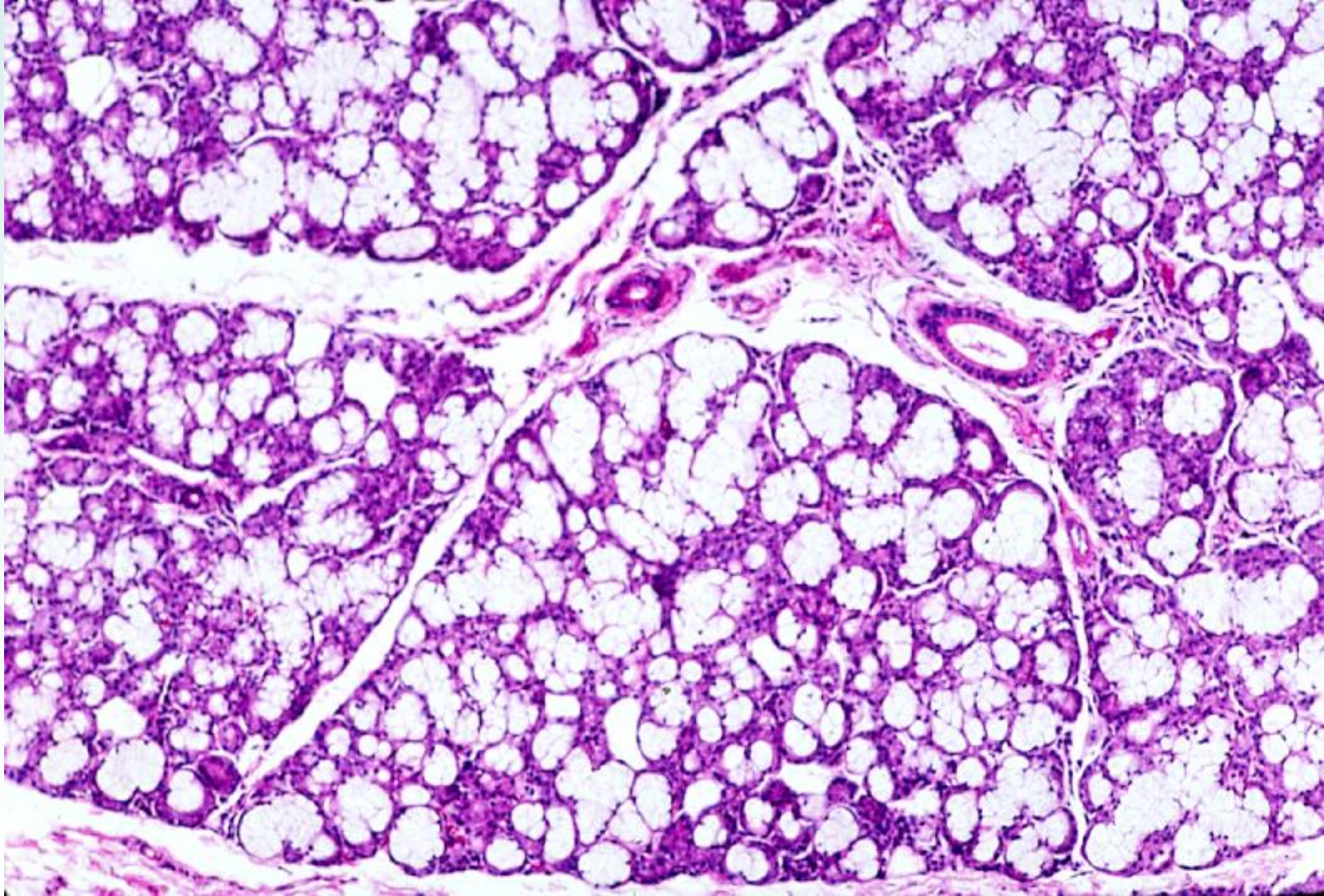
## Gl. sublingualis





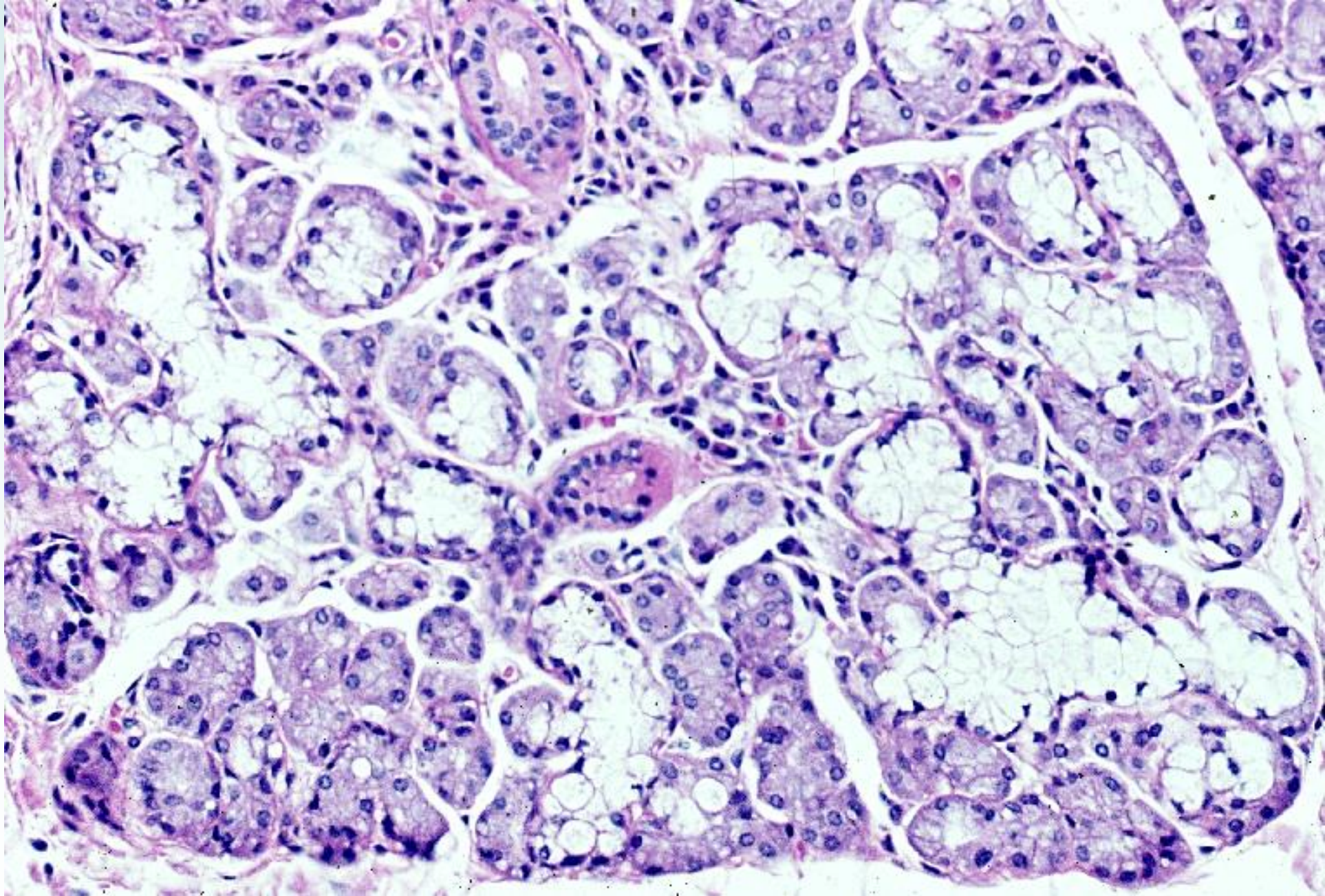
09-38 Gl. sublingualis, 1. General view. Human, H-E stain, x 2.2.





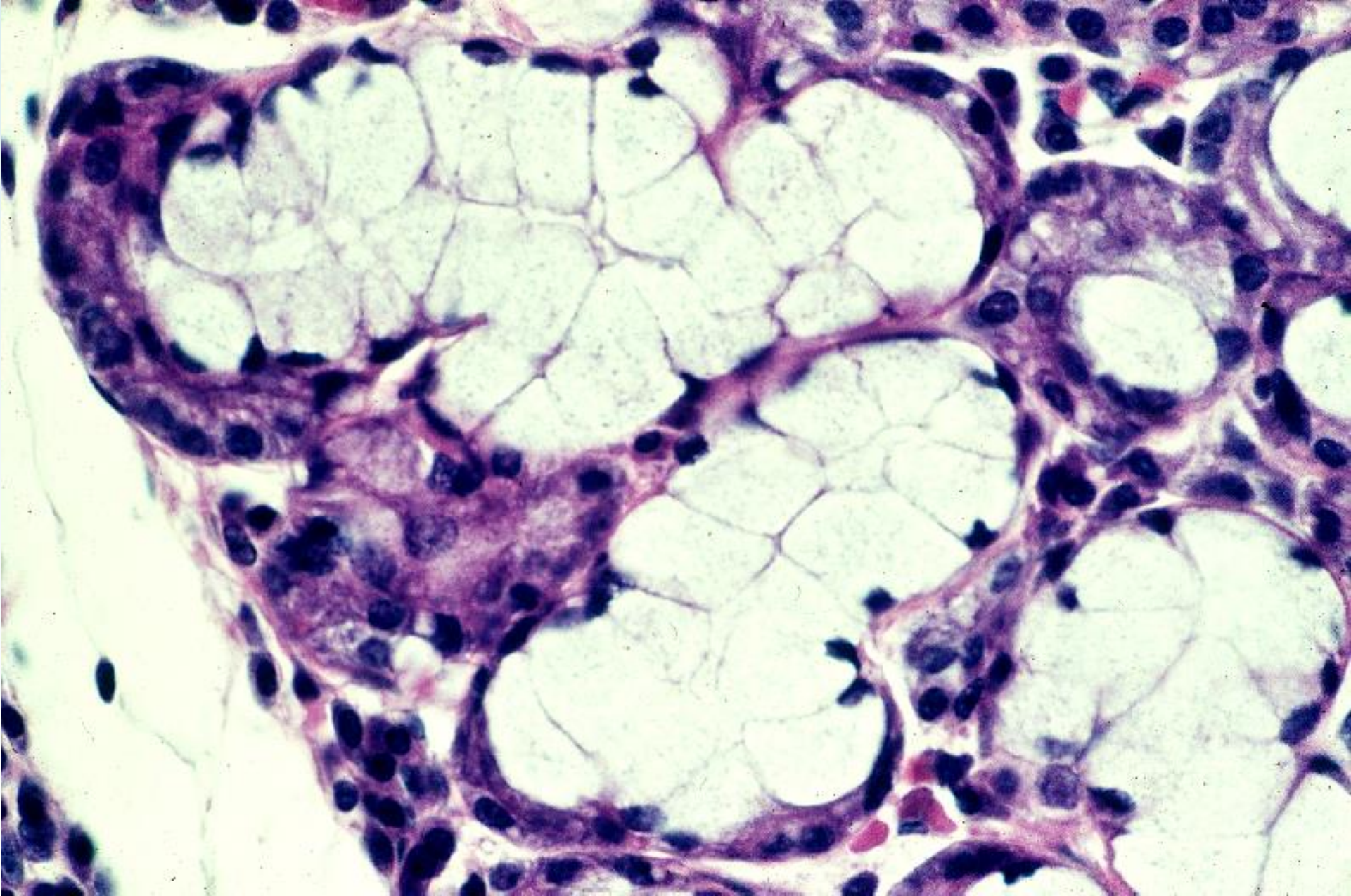
09-39 Gl. sublingualis, 2. Human, H-E stain, x 25.





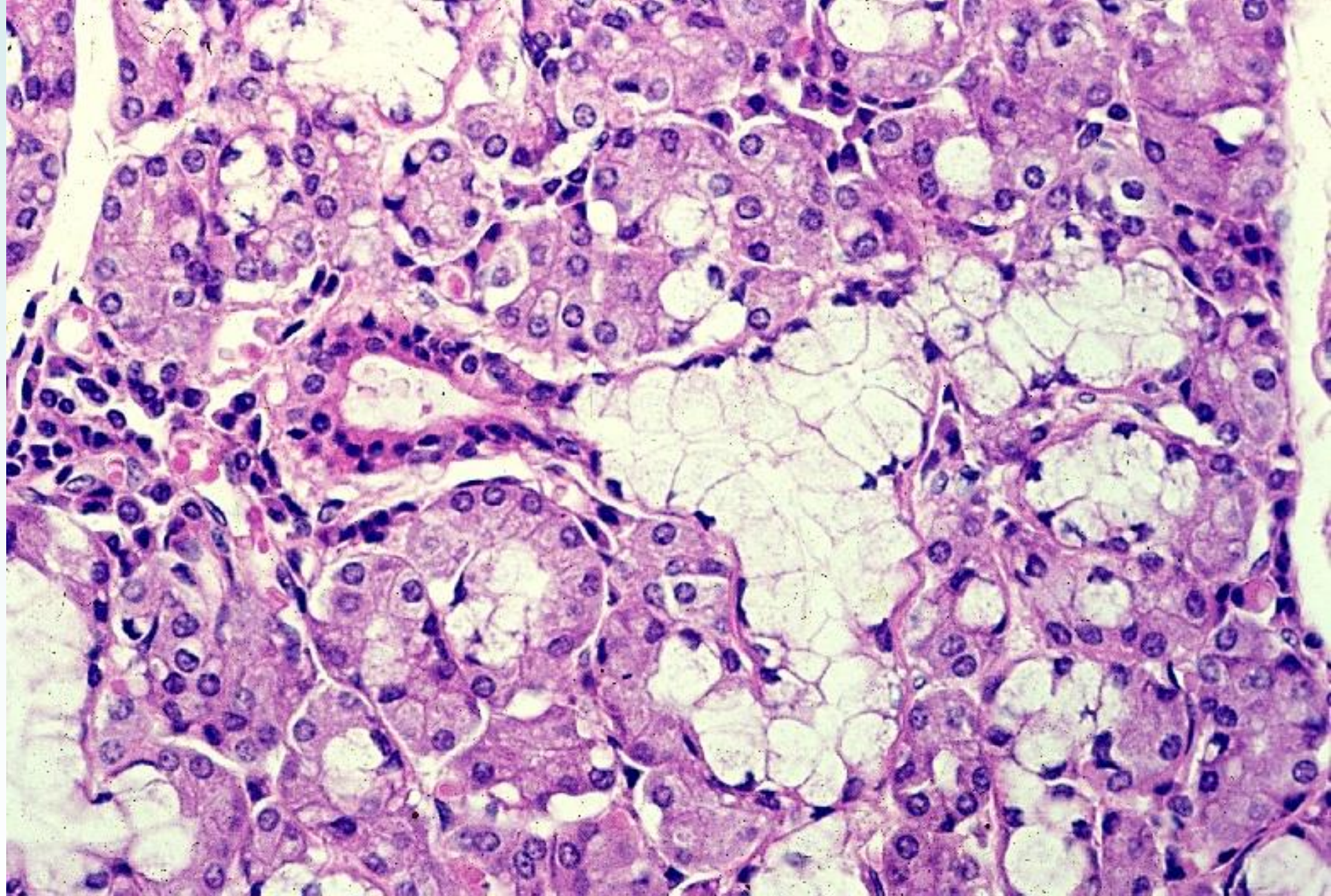
09-40 Gl. sublingualis, 3. Human, H-E stain, x 64.





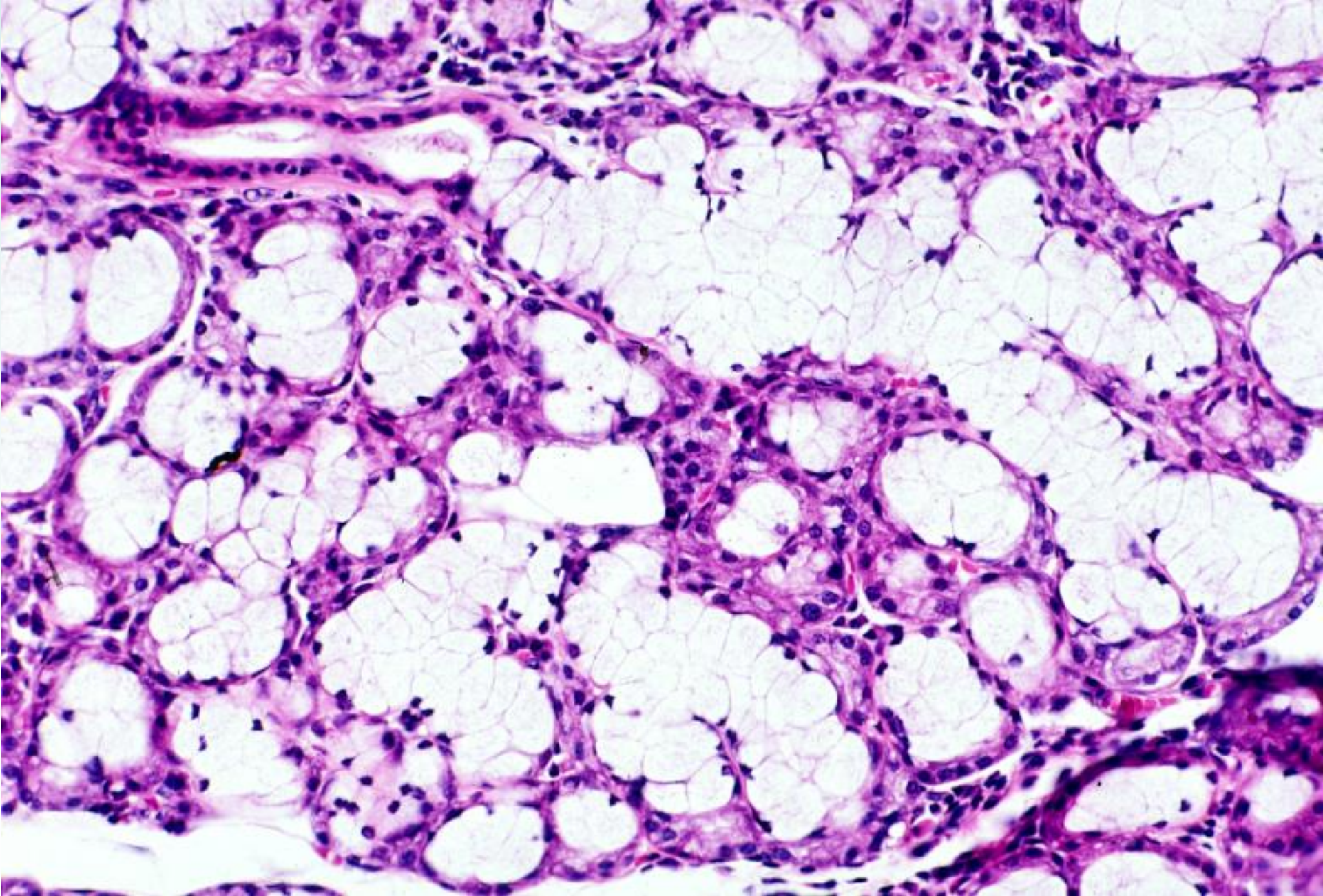
09-41 Gl. sublingualis, 4. Mucous acini and demilunes. Human, H-E stain, x 160.





09-42 Gl. sublingualis, 5. Human, H-E stain, x 100.





09-43 Gl. sublingualis, 6. Human, H-E stain, x 66.

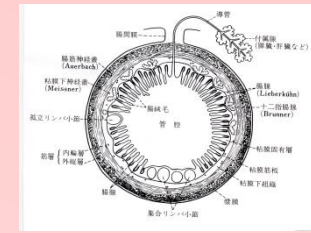


## 09-00 Digestive System 1

- The digestive system is a long, tortuous tube, which begins with the lips and ends with the anus. On its way through this tract the food undergoes mechanical and chemical changes. It is minced and ground by the teeth and is forwarded through the tube by the contraction of its muscular walls, while it is digested by the secretion of the various parts of the alimentary tract and its auxiliary glands. A part of the digested food is absorbed through the walls of the intestine and passes into the blood, which carries it to the tissues of the organism. The undigested residue is eliminated as feces.
- The digestive tract consists of mouth, pharynx, esophagus, stomach, small intestine, large intestine and rectum. The functional condition of one segment causes certain functional changes in the following segments. Thus the regular sequence of the processes necessary for the digestion of food is assured.



## 09-01 General structure of the digestive system ( Scheme )



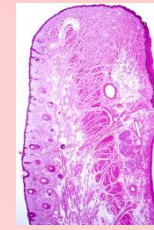
- The wall of the digestive tube consists of concentrically arranged several layers; they are from inside to outside ① tunica mucosa, ② tela sumucosa, ③ tunica muscularis and ④ tunica serosa.
- The tunica mucosa, mucous membrane, enclosing the lumen of the tube, consists of an epithelium, underlying loose connective tissue, lamina propria, and thin smooth muscle layer, lamina muscularis mucosae. The mucous membrane is enclosed by a layer of the loose connective tissue of coarse collagen fibers, tela submucosa, and then a thick smooth muscle layers, tunica mucosa, consisting of the inner circularly and outer longitudinally oriented smooth muscle layers. The outermost layer is the tunica serosa, i.e. peritoneum, which forms mesenterium at the posterior midline of the tube and connects the tube to the posterior midline of the abdominal cavity.



## 09-001 Oral Cavity



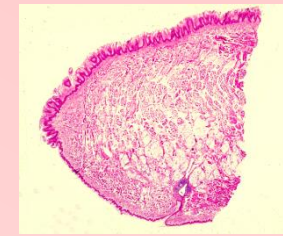## 09-02 Lip, sagittal section, Human, H-E stain, x 1.2.



- The upper and lower lips close the front of the oral cavity from the upper and lower sides. The lip is covered by the skin at front side and by the mucous membrane at the back side; it contains in the middle distinct skeletal muscle fiber bundles, M. orbicularis oris, and between this and the skin subcutaneous connective tissue and between this and mucous membrane submucous connective tissue. On the top between the skin and mucous membrane cornification of the skin epithelium becomes gradually inconspicuous and shifts into the epithelium of the mucous membrane. In this area epithelium is thin and numerous papillae protrude within the epithelium, so that this area looks reddish because of the red hue of the blood circulating in the capillaries in papillae.
- This figure is a general view of human lip sagittally sectioned; the left side is the front covered by skin; there are several hair follicles and small sebaceous glands. The right side is the oral mucous membrane; in the submucous connective tissue a small salivary gland is seen.



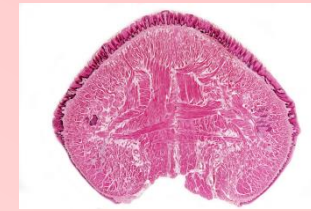## 09-03 Apex linguae, sagittal section. Human, H-E stain, x 1.7.



- This is a sagittal section of a human tongue. The tongue consists of interlacing bundles of stratified muscle that run in three planes and cross one another at right angle. The muscular mass is covered by a tightly adherent mucous membrane. The dorsal surface of the tongue is rough because of the innumerable small processes, papillae, and beneath it there is a dense connective tissue layer, called aponeurosis linguae, whereas the lower surface is smooth and mucous membrane is thin, lacking of such processes. There are four kind of papillae: filiform, fungiform, circumvallate and foliate papillae.
- In this figure on the dorsal surface of the tongue numerous filiform papillae and several fungiform papillae are seen and beneath it aponeurosis linguae is very conspicuous. At lower middle there is a duct of lingual gland surrounded by the lymphocyte infiltration.



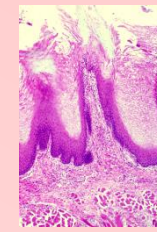
## 09-04 Corpus linguae, transverse section. Monkey, H-E stain, x 1.3.



- This shows a general view of the transversely sectioned monkey tongue. The dorsal surface is covered by a very thick epithelium with numerous papillae, whereas on the lower surface epithelium is very thin, lacking papillae. Enclosed by the epithelium, vertical, transverse and longitudinal arrangement of the stratified muscle bundles is in good order. A small group of mixed gland is recognized each at left and right center among the muscle bundles.



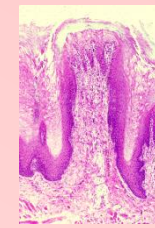
## 09-05 Papilla filiformis. Human, H-E stain, x 25.



- The filiform papillae are 2 to 3 mm long. Their connective tissue core tapers and at the top provides with secondary papillae with pointed ends. The epithelium covering these connective tissue outgrowths also forms short papillae, which taper into pointed processes.
- This figure shows a typical filiform papilla containing the connective tissue core. Beneath the core the aponeurosis liguae is distinct, consisting of horizontally oriented connective tissue fibers. The lowermost area of this figure is occupied by the stratified muscular fibers, among which longitudinally sectioned fibers end on the aponeurosis.



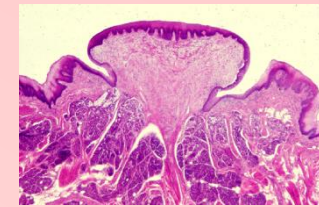
## 09-06 Papilla fungiformis. Human, H-E stain, x 25.



- The fungiform papillae have a short, slightly constricted stalk and a slightly flattened hemispherical upper part, of 0.5 to 1.0 mm in diameter. The connective tissue core forms secondary papillae that project into recesses in the underside of the epithelium, which has a smooth free surface.
- This figure shows a fungiform papilla, the connective tissue core of which sends several secondary papillae into the surface epithelium and contains distinct nerve fiber bundle at its axial portion. The surface epithelium this fungiform papilla shows slight cornification.



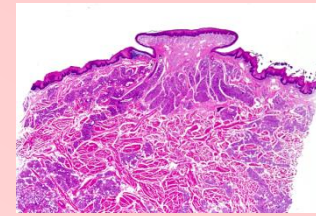
## 09-07 Papilla vallata, 1. Human, H-E stain, x 4.0.



- In the posterior region of the dorsal surface of the tongue, there is a V-shaped line, with the opening of the angle directed forward; this is sulcus terminalis, the boundary between the corpus linguae and radix linguae. Along the diverging arms of this line, 7 to 12 vallate papillae are arranged. This type of papilla consists of a flattened round head of 2 to 3 mm in diameter and a stalk of 0.5 to 1.5 mm high and is surrounded by a deep circular furrow. The connective tissue core forms secondary papillae on the upper surface. The covering epithelium of the head is smooth, while that of the lateral surface of the stalk contains many taste buds. A few of them may be present in the outer wall of the groove surrounding the papilla. Beneath the vallate papillae there are distinct glands of the serous type in the submucosa and embedded deep in the underlying muscular tissue and whose excretory ducts open into the bottom of the furrow. They are called glands of Ebner.
- This is a vertical section of a vallate papilla, surrounded by a furrow. In the lower half region of this field it is filled by the glands of Ebner, stained deep violet. The connective tissue core sends many secondary papillae into the surface epithelium of the head.



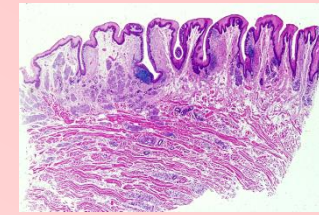
## 09-08 Papilla vallata, 2. Human, H-E stain, x 3.0.



- This vallate papilla is low and surrounding furrow is shallow. The glands of Ebner are not abundant but their violet hue is conspicuous.



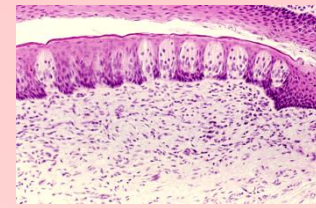
## 09-09 Papillae foliatae. Human, H-E stain, x 3.0.



- In the posterior region of the corpus linguae on the lateral surface are foliate papillae on each side. They consist of several vertical parallel folds of equal size, of 0.5 to 1.0 mm wide and 0.5 to 2.0 mm high, separated by deep vertical furrows. The connective tissue core sends many secondary papillae into the surface epithelium. The epithelium of the wall facing the furrow contains numerous taste buds. Beneath these papillae there are also the glands of Ebner.
- This figure shows the human foliate papillae.



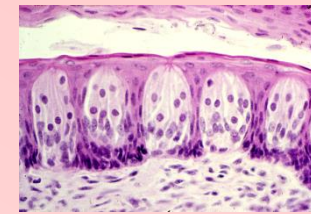## 09-10 Taste buds, 1. Monkey, H-E stain, x 64.



- This figure shows the taste buds in the epithelium facing the furrow of the foliate papilla. On the top traverses the furrow and in the underlying epithelium many taste buds form a line. Beneath the epithelium there is a thick layer of the nerve fibers innervating these taste buds.



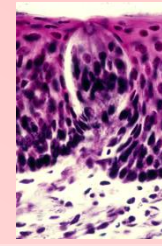
## 09-11 Taste buds, 2. Monkey, H-E stain, x 160.



- Higher magnification of 09-10.
- The taste buds are seen in the histological sections as pale, oval bodies in the darker staining lingual epithelium. Their vertical dimension is 50 to 80  $\mu\text{m}$  and width 30 to 50  $\mu\text{m}$ . They extend from the basement lamina almost to the surface. They consist of 50 to 90 fusiform cells slightly wider at the base than at the apex. The narrow apices converge on a small opening in the surface layers of the epithelium called the taste pore. Light microscopically two types of cells were distinguished in the taste buds: light cells and dark cells. Small cells at the base of the taste bud were recognized and assumed to be stem-cell precursors of the gustatory cells. The epithelium over each taste bud is pierced by a small opening, the taste pore.
- Electron microscopically, slender dark cells situated both at the periphery of the taste bud and in its interior were observed to have long microvilli projecting into the taste pore; these are designated type-I cells and interpreted as supporting cells. The more centrally situated type-II cells also have long microvilli. A type-III cell, which falls into the broad category of light cells, has also been identified. It has a long apical process, several times the diameter of a microvillus. This extends through the dense material in the pore to the free surface. The processes of this and passively those of other cell types projecting into the pore, are the receptor surface for the sense of taste. Regrettably no consensus has been reached as to the functional meaning of these cell types.
- In this figure typical arrangement of taste buds in the epithelium is clearly seen. The taste bud locating in the middle shows taste pore at the apical end ( arrow ) and at the bottom nerve fiber bundle entering this bud is evident. Directly beneath the epithelium a dense network of nerve fibers is seen..



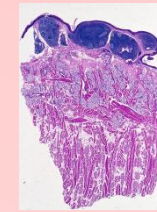
## 09-12 Taste bud. Human, Suzuki's silver impregnation, x 200.



- This is a silver impregnated taste bud. Fine nerve fibers entering the bud are clearly shown. This preparation was made by Prof. Dr. K. Suzuki.



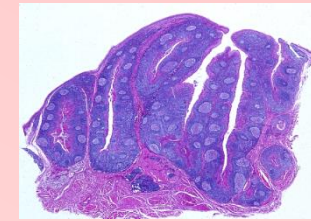
## 09-13 Radix linguae, tonsilla lingualis. Human, H-E stain, x 2.0.



- The posterior portion of tongue, posterior to the sulcus terminalis, is called the root of the tongue, radix linguae, where, different from the dorsum linguae, no lingual papillae are present and the surface of the tongue is smooth. On the free surface there are numerous flat bulges of 3 to 5 mm in diameter and deep furrows between them. Beneath the epithelium of these bulges and furrows there are numerous dense lymphatic nodules; they are altogether called lingual tonsils. Under the tonsils there are mucous glands, embedded in the muscle tissue. The ducts of these glands open into the bottom of the furrows.



## 09-14 Tonsilla palatine. Human, H-E stain, x 2.0.



- The aperture through which the oral cavity communicates with the pharynx is called the fauces. In this region the mucous membrane of the digestive tract contains accumulations of lymphatic tissue. The largest of them, well outlined organ, is the tonsilla palatine, oval swelling of 6 to 8 mm wide and 8 to 10 mm long, which occupies the space between the glossopalatine and pharyngopalatine arches. The overlying epithelium invaginates to form 10 to 20 deep tonsillar crypts, which almost reach the connective tissue capsule. Beneath the surface epithelium and surrounding crypts the nodules with the prominent germinal center are embedded in a diffuse mass of dense lymphatic tissue 1 to 2 mm thick, and are usually arranged in a single layer. The crypts with their surrounding sheaths of lymphatic tissue are partially separated from one another by thin partitions of loose connective tissue which invaginate from the capsule.
- This figure shows the general view of the human palatine tonsil taken from a cadaver.

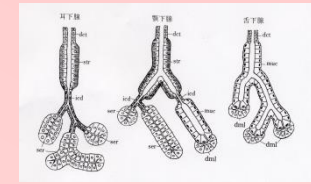


## 09-002 Salivary Glands

- Numerous small glands open into the oral cavity and secrete continuously and furnish a liquid, saliva, which moistens the oral mucous membrane. There are three pairs of large glands, which constitute the salivary glands proper. They are the parotid, the submandibular, and the sublingual glands. They secrete only when mechanical, thermal, or chemical stimuli act upon the nerve endings in the oral mucous membrane, or as a result of certain olfactory stimuli. The saliva secreted by the large glands is abundant and helps prepare the food for digestion in the stomach and intestine.



## 09-15 Structure of three large salivary glands ( Scheme ).



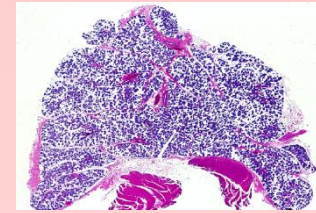
- ① Parotid gland consists only of the serous acini and has a long branching duct system of the intercalated ducts and striated ducts, which open into the excretory ducts.
- ② Submandibular gland consists of both serous and mucous acini and the duct system is constituted of very short intercalated ducts and long branching striated ducts which open into the excretory ducts. At the distal ends of the mucous acini attach the serous cell groups as semilunar caps, demilunes.
- ③ Sublingual glands consist of mostly mucous and a few serous acini. The duct system is simple: mucous acini open directly into the excretory ducts. Serous demilunes are numerous.



## 09-0021 Gl. parotis



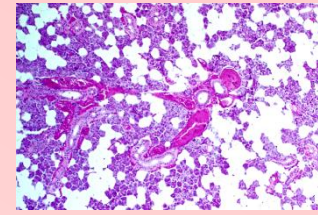
## 09-16 Gl. parotis, 1. General view. Human, H-E stain, x 2.2.



- This is a general view of a human parotid gland. The parotid gland consisting only of serous acini, is divided by thin connective tissue septa into the numerous lobules which contain usually abundant fat tissue. So the parenchyma looks very loose.



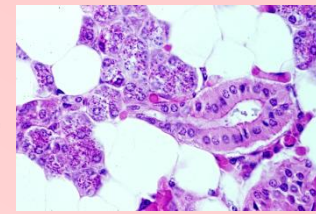
**09-17 Gl. parotis, 2. Low power magnification. Human, H-E stain, x 25.**



- Dark violet stained acini are scattered among the fat cells. At center large veins and concomitant duct system are seen. The lower right portion of this figure is shown in 09-18 at higher magnification.



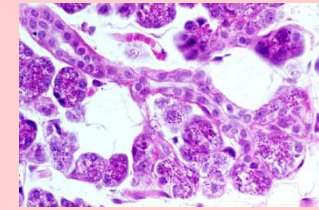
**09-18 Gl. Parotis, 3. Intercalated duct and striated duct. Human, H-E stain, x 160.**



- At center a longitudinal section of an intercalated duct continuing with a striated duct is seen. The intercalated duct consists of simple cuboidal or squamous epithelial cells showing no red hue, whereas the epithelium of the striated duct stains deep red and the dense striations perpendicular to the basement membrane are conspicuous. The acinar cells contain each a round nucleus and abundant secretion granules stained dark red. Around these surround numerous fat cells.



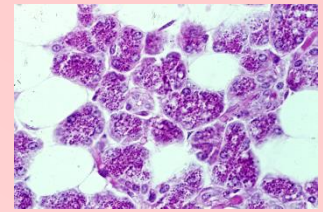
## 09-19 Gl. parotis, 4. Intercalated duct. Human, H-E stain, x 160.



- In this field a long intercalated duct, being longitudinally sectioned, is seen. After dividing two or three times it continues with acini whose cells contain numerous deep red stained secretion granules. The epithelial cells of this tube are low cuboidal and enclose a narrow lumen. Their cytoplasm is colorless or stains faintly pink.
- The serous acini consist of several cells enclosing a very narrow lumen. Their cytoplasm stains dark blue and contains numerous deep red stained secretion granules in the apical region. In this specimen the lumen is not recognized because of the abundance of secretion granules



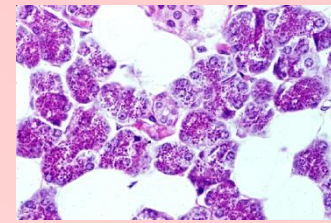
09-20 Gl. parotis, 5. Intercalated duct, transverse section. Human, H-E stain, x 160.



- At center a transversely sectioned intercalated duct with a narrow lumen is seen ( arrow ). The intercalated duct is a thin tube with a narrow lumen enclosed by three to five low cuboidal pale cells. In the acinar cells because of abundance of secretion granules nuclei are pressed against the basal area.

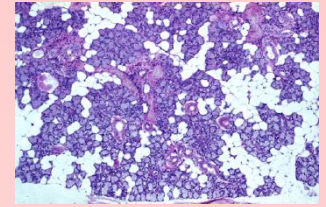


**09-21 Gl. parotis, 6. Intercalated duct. Human, H-E stain, x 160.**



- At center a transverse section of an intercalated duct is seen ( arrow ).

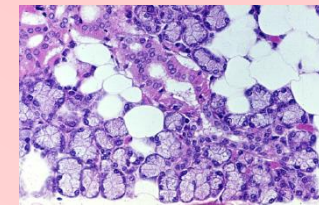
**09-22 Gl. parotis, 7. General view of another parotid gland. Human, H-E stain, x 25.**



- This specimen is other than 09-16 to 09- 21. In this specimen secretion granules are just discharged so that the general hue is deep blue and against this hue, red stained striated ducts are evident. The lower right portion of this figure is shown as 09-23 at higher magnification.

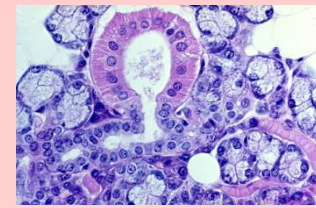


## 09-23 Gl. parotis, 8. Striated and intercalated duct. Human, H-E stain, x 100.



- Higher magnification of 09-22. From top left a longitudinally sectioned striated duct, stained deep red, runs down right wards and at distal end it shifts to a slender intercalated duct, showing no red hue, which branches into two and at each distal end continues with the serous acini.
- The serous acini contain no secretion granules so that their cytoplasm appears blue and cell boundary is evident but their lumen is so tiny that hardly discernible.

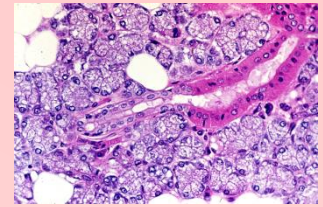
**09-24 Gl. parotis, 9. Striated duct and intercalated duct. Human, H-E stain, x 160.**



- At top center is a transversely sectioned striated duct of larger diameter consisting of simple columnar epithelium, the cytoplasm of which stains deep red and contains dense striation perpendicular to the basement membrane. At lower end of this duct the red hue of the epithelial cells suddenly disappears and shifts to the intercalated duct with narrow lumen consisting of small cuboidal epithelial cells showing bluish hue. The appearance of the serous acini is the same as 09-23.

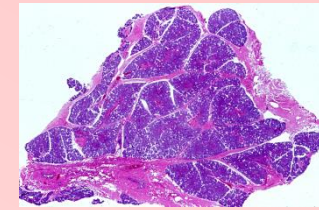


09-25 Gl. parotis, 10. Striated duct and intercalated duct. Human, H-E stain, x 100.



- In this figure is shown the sudden shift from a striated duct to an intercalated duct. The striated duct of larger caliber consisting of tall columnar epithelium, whose cytoplasm stains deep red, loses suddenly red hue and shifts to the slender intercalated duct, consisting of small cuboidal cells, showing no red hue. The serous acini contain no secretion granules.

## 09-26 Gl. parotis containing less fat cells. Human, H-E stain, x 2.2.

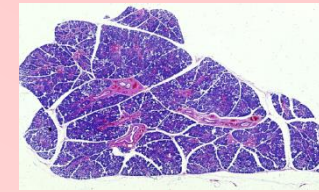


- The content of fat cells in the parotid gland differs from case to case; usually it contains so much; but in some case, as shown in this figure, the parotid gland contains only a few fat cells.



## 09-0022 Gl. submandibularis

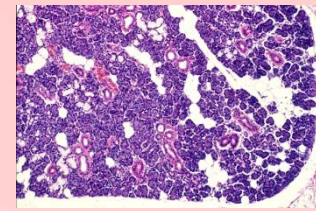
## 09-27 Gl. submandibularis, 1. Human, H-E stain, x 2.5.



- This is a general view of a gl. submandibularis. Gl. submandibularis consists mainly of serous acini and of a part of mucous acini. Gl. submandibularis contains only a few fat cells so that it gives a compact appearance.
- This is a general view of a submandibular gland

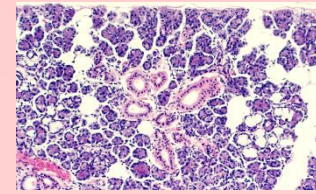


## 09-28 Gl. submandibularis, 2. Human, H-E stain, x 40.



- The low power magnification of a human submandibular gland. It consists mainly of serous acini and only small mucous acini are found at lower left and top center. The striated ducts are numerous and conspicuous.

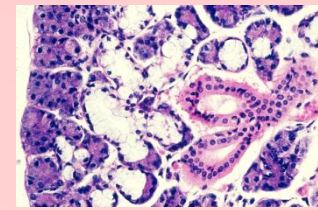
09-29 Gl. submandibularis, 3. Human, H-E stain, x 40.



- This is a portion of a human submandibular gland, consisting largely of serous acini. At center a group of the striated ducts are seen, which are originated from one duct and arranged radially. Serous acini contain much secretion granules and a group of mucous acini are recognized at lower right.

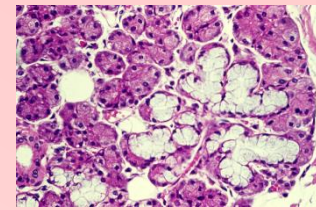


09-30 Gl. submandibularis, 4. Human, H-E stain, x 100.



- At middle right a striated duct is dividing into two branches. Above and left side of these striated duct, there are mucous acini with serous cell group, demilune. At the left edge serous acini form a line whose cytoplasm stain dark violet.

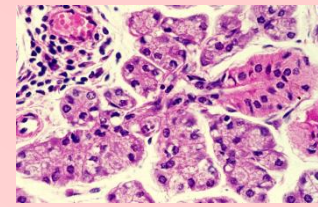
**09-31 Gl. submandibularis, 5. Human, H-E stain, x 100.**



- In the right side of this figure occupy the mucous acini that are branching and arranged radially and at the distal end of each acinus is covered by the demilune.
- The cytoplasm of the serous acini appear reddish violet, because of abundant secretion granules.

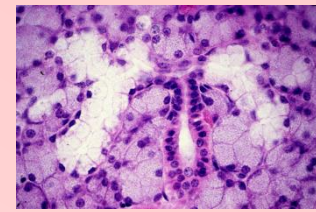

**09-32 Gl. submandibularis, 6. Human, H-E stain, x 160.**



- In this field only serous acini are seen. At right middle a typical striated duct shifts to the intercalated duct, which is very short and branches into two or three ones shifting in turn to the serous acini. At upper left is a vein surrounded by lymphocytes.

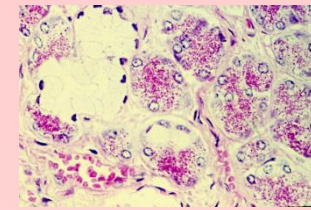
**09-33 Gl. submandibularis, 7. Monkey, H-E stain, x 160.**



- At center one striated duct goes upward and shifts to the intercalated duct, which branches into two shifting to the mucous acini. The lumen of these ducts and mucous acini is continuously observed. The distal end of the mucous acini is capped by dumilune.

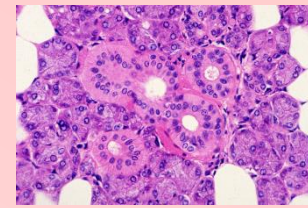


**09-34 Gl. submandibularis, 8. Secretion granules.  
Human, H-E stain, x 160.**



- In this case the secretion granules in the serous acinar cells are very conspicuous. At upper left corner mucous acini with demilune are conspicuous. At lower left corner there is a vein containing erythrocytes.

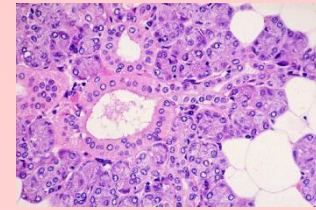
**09-35 Gl. submandibularis, 9. Striated ducts. Human,  
H-E stain, x 160.**



- At the center a group of transversely sectioned striated ducts are seen, that originate from one stem duct. The striated duct consists of simple columnar cells surrounding a round lumen of large caliber. The cytoplasm is stained deep by acid dye, eosin, and contains distinct dense basal striations. Around these striated ducts are serous acini.

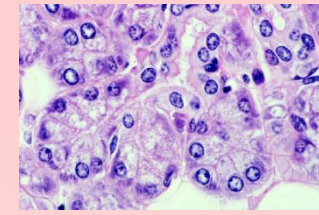


**09-36 Gl. submandibularis, 10. Human, H-E stain, x 160.**



- At center a striated duct of large caliber sends rightward a thin intercalated duct which continues to the serous acini. In this field only serous acini are seen.

**09-37 Gl. submandibularis, 11. Intercellular secretory canaliculi.  
Human, H-E stain, x 250.**

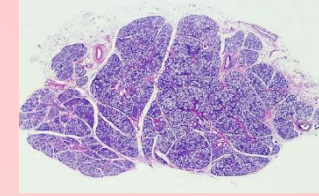


- This is a higher magnification of serous acini, in which the lumen and intercellular secretory canaliculi are evident. At top right is an intercalated duct ( long arrow ) which branches into two. The one goes down leftward and continues with the lumen of serous acinus and further with intercellular secretory canaliculi ( short arrows ). In this specimen no secretion granules are seen.



## 09-0023 Gl. sublingualis

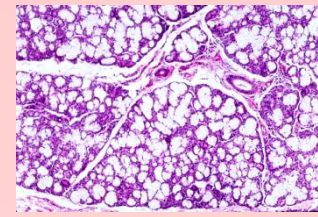
## 09-38 Gl. sublingualis, 1. General view. Human, H-E stain, x 2.2.



- The sublingual gland consists mainly of mucous acini intermingled by serous acini.
- This figure shows the general view of human sublingual gland, which is divided by interlobular connective tissue into numerous lobi and further lobuli. The interlobular connective tissue provides the pathway to the blood vessels, nerves and excretory ducts. The sublingual gland contains fat cell very few.

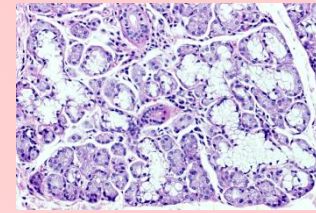


**09-39 Gl. sublingualis, 2. Human, H-E stain, x 25.**



- This is a low power magnification of a human sublingual gland. The general construction of this gland consisting of lobules is well recognized. Mucous acini are numerous and conspicuous. In the interlobular connective tissue two large excretory ducts are seen.

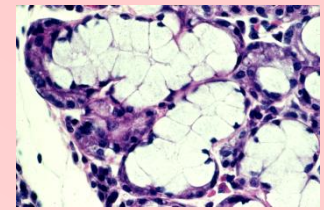
**09-40 Gl. sublingualis, 3. Human, H-E stain, x 64.**



- Here mucous acini are long and branching, distal end of that is capped by dumilune. In the submandibular gland neither striated duct nor intercalated duct is seen; the excretory duct continues directly with mucous acini. At center one excretory duct shifts to the mucous acini. In this field the serous acini are numerous.

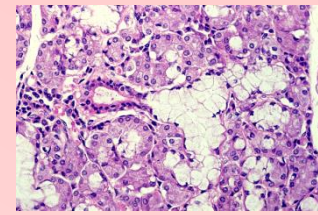


**09-41 Gl. sublingualis, 4. Mucous acini and demilunes. Human, H-E stain, x 160.**



- In the left half of this field true longitudinally sectioned mucous acini are seen. To the distal end (left side) of each acinus attach the serous cell group, demilune.

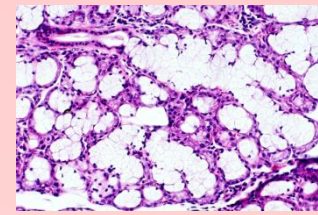
**09-42 Gl. sublingualis, 5. Human, H-E stain, x 100.**



- At center an excretory duct continues directly with the mucous acinus which branches into two. In this field serous acini are numerous.



**09-43 Gl. sublingualis, 6. Human, H-E stain, x 66.**



- At top left an excretory duct goes rightward and continues directly with a mucous acinus which is long and branches into several terminal portions with dumilunes.